COUNTWAY LIBRARY
HC 4YPU -

SAUNDERS'

MEDICAL HAND-ATLASES.

THE series of books included under this title are authorized translations into English of the world-famous

Lehmann Medicinische Handatlanten,

which for **scientific accuracy, pictorial beauty, compactness,** and **cheapness** surpass any similar volumes ever published.

Each volume contains from **50 to 100 colored plates,** besides numerous illustrations in the text. The colored plates have been executed by the most skilful German lithographers, in some cases more than twenty impressions being required to obtain the desired result. Each plate is accompanied by a full and appropriate **description,** and each book contains a condensed but adequate **outline of the subject** to which it is devoted.

One of the most valuable features of these atlases is that they offer

BOSTON
MEDICAL LIBRARY
8 THE FENWAY

The same careful and competent **editorial supervision** has been secured in the English edition as in the originals. The translations have been edited by **leading specialists** in the different subjects considered. The volumes are of a uniform and convenient size ($5 \times 7\frac{1}{2}$ inches), and are substantially bound in cloth.

(For List of Books, Prices, etc., see back cover and fly-leaf)

Pamphlet containing specimens of the Colored Plates sent free on application

THE BOSTON
Medical and Surgical
JOURNAL.

ATLAS AND EPITOME

OF

DISEASES OF THE SKIN

BY

DR. FRANZ MRAČEK

Professor of Dermatology in the University of Vienna

AUTHORIZED TRANSLATION FROM THE GERMAN

SECOND EDITION, REVISED AND ENLARGED

EDITED BY

HENRY W. STELWAGON, M.D., PH.D.

Professor of Dermatology, Jefferson Medical College, Philadelphia; Physician to the Department for Skin Diseases, Howard Hospital; Dermatologist to the Philadelphia Hospital, etc.

With 77 Colored Plates by the Artists, J. Fink and A. Schmitson, and 50 Half-tone Illustrations

PHILADELPHIA AND LONDON

W. B. SAUNDERS & COMPANY

1905

27.A.271.

Set up, electrotyped, printed, and copyrighted May, 1899. Reprinted September, 1899, March, 1900, December, 1900, June, 1901, and January, 1902. Revised, entirely reset, reprinted, and recopyrighted July, 1905.

Copyright, 1905, by W. B. Saunders & Company.

PRESS OF
W. B. SAUNDERS & COMPANY
PHILADELPHIA

EDITOR'S PREFACE.

THE author's idea of providing a hand-atlas of convenient size containing a series of colored plates and black-and-white illustrations conjointly with sufficient text for practical purposes was a good one, and it has had its full justification in the continued favor with which the first edition has been received. In the present second, revised and enlarged edition the author has, as his own preface shows, materially increased the number of colored plates as well as the half-tone cuts, and has added considerably to the text. It should, as it now appears, be even more acceptably received than formerly, and serve to add still further to the general knowledge and interest in this branch.

H. W. S.

JULY, 1905.

PREFACE TO THE SECOND EDITION.

In the preparation of this edition the book has undergone considerable rearrangement and enlargement. In the Atlas portion the following new plates appear:

Erythema Exudativum, Purpura Papulosa et Bullosa, Leucæmia, Erythema Scarlatiniforme, Dermatitis Exfoliativa, Exanthema Bullosum Neuropathicum, Herpes Zoster Cervicalis, Impetigo Herpetiformis, Pemphigus Vulgaris Diutinus, Gangræna Raynaud, Combustio, Bromid Acne, Ecthymata per Totam Cutem Dispersa, Psoriasis Vulgaris Capitis, Dermatitis, Ichthyosis Serpentina, Ichthyosis et Atrophia Universalis, Akanthosis Nigricans, Achromatosis, Elephantiasis Cruris—Lupus Vulgaris, Elephantiasis, Folliclis, Ulcera Tuberculosa Dorsi Manus, Tuberculosis Verrucosa Cutis, Herpes Tonsurans Orbicularis, Onychia et Paronychia Trichophytica (Herpes Tonsurans).

In addition to this increase in the illustrations the text has also been subjected to considerable revision to make it properly reflect present-day dermatology. The histopathological advances have been especially noted. Having in view the practical usefulness of this hand-book, I have, as far as possible, avoided theoretical discussions. In the arrangement and grouping of the diseases I have been

chiefly guided by etiological considerations, without, however, holding myself strictly to any fixed system. In the selection of the new material for the Atlas portion I had the aid of my assistant, Dr. von Buchta. The artistic portrayal of the new pictures was cared for by Mr. Fink. The therapeutic portion was revised by Dr. S. Gross.

May this work in its enlarged form serve to contribute to the general dissemination of knowledge concerning our special branch, whose high practical importance is becoming daily more and more recognized.

DR. MRACEK.

VIENNA, July, 1904.

CONTENTS.

PAGE

Anatomy 17
Physiology 23
General Pathology 26
General Therapeutics 30
Disorders of the Sweat Glands 35
Hyperidrosis 35
Osmidrosis 36
Miliaria Crystallina 36
Miliaria Rubra 36
Miliaria Alba 36
Miliaria Epidemica 37
Hematidrosis 37
Uridrosis 37
Dysidrosis 37
Hydrocystoma 38
Disorders of the Sebaceous Glands 40
Seborrhea 40
Vernix Caseosa 40
Eczema Seborrhoicum 40
Comedones 41
Pityriasis Capitis 42
Milium 43
Molluscum Contagiosum 44
Acne 45
Sycosis 51
Dermatitis Papillaris Capillitii 53
Acne Rosacea 54
Anemia of the Skin 57
Hyperemia of the Skin 58
Inflammatory Dermatoses 60
Erythema 60

Inflammatory Dermatoses—(*Continued*). PAGE
Erythema Multiforme 60
Erythema Nodosum 62
Erythema Caloricum 64
Erythema Solare 64
Röntgen-ray Dermatitis 65
Serum Erythema 65
Toxic Erythema 65
Erythromelalgia 65
Urticaria 66
Pellagra 69
Drug Eruptions 70
Hemorrhagic Erythema 72
Peliosis 72
Morbus Maculosus Werlhofii 73
Scorbutus 74
Dermatitis 75
Gangræna Diabetica Bullosa Serpiginosa 75
Multiple Cachectic Gangrene 76
Neurotic Gangrene 77
Raynaud's Disease 77
Syringomyelia 77
Multiple Neurotic Gangrene 78
Perforating Ulcer of the Foot 78
Gangrenous Genital Ulcers 79
Noma 80
Combustio (Burns) 81
Congelatio (Frost Bite) 86
Erysipelas 89
Furunculus 92
Carbunculus 93
Pustula Maligna 94
Equinia 94
Exfoliative Erythrodermias 95
Pityriasis Rubra 96
Keratolysis 98
Dermatitis Exfoliativa Neonatorum 98
Vesicular and Bullous Eruptions 100
Exanthema Bullosum Neuropathicum 100
Herpes Zoster 100

Vesicular and Bullous Eruptions—(*Continued*). PAGE
Herpes Facialis et Progenitalis 104
Pemphigus Neonatorum Sive Contagiosus 106
Impetigo Simplex 107
Impetigo Contagiosa 108
Impetigo Herpetiformis 109
Pemphigus 110
Pemphigus Vulgaris 110
Pemphigus Foliaceus 112
Pemphigus Vegetans 113
Dermatitis Herpetiformis 115
Squamous Dermatoses 116
Psoriasis 116
Lichen 127
Lichen Ruber Acuminatus 127
Pityriasis Ruber Pilaris 128
Lichen Ruber Planus 129
Lichen Scrofulosorum 132
Eczema 134
Acute Eczema 134
Chronic Eczema 138
Prurigo 147
Strophulus 150
Neuroses 151
Pruritus 151
Anesthesia of the Skin 154
Anomalies of the Epidermis 154
Callositas 154
Clavus 155
Cornu Cutaneum 155
Verruca 156
Ichthyosis 157
Lichen Pilaris 159
Ichthyosis Congenita 159
Acanthosis Nigricans 159
Psorospermosis Follicularis Vegetans 160
Keratoma Hereditarium Palmare et Plantare 161
Scleroderma 162
Edema Neonatorum 163
Sclerema Neonatorum 163

PAGE
Anomalies of the Hair 164
Alopecia 164
Trichorrhexis Nodosa 166
Trichoptilosis 167
Spindle Hairs 167
Albinismus 167
Poliosis 167
Graying of the Hair 167
Anomalies of the Nails 168
Pigment Anomalies of the Skin 170
New Growths 178
Nevi 178
Cicatrix 180
Scar Keloid 180
True Keloid 181
Elephantiasis; Pachydermia 181
Myxedema 183
Partial Atrophy and Thinning of the Skin 183
Kraurosis Vulvæ 184
General Atrophy of the Skin 184
Xeroderma Pigmentosum 185
Lupus Erythematosus 187
Fibroma Molluscum Seu Pendulum 191
Lipoma 192
Xanthoma; Xanthelasma; Vitiligoidea 193
Dermatomyomata 194
Angiomata 195
Nævus Vasculosus 195
Lymphangioma 196
Lymphangioma Tuberosum Multiplex 196
Rhinoscleroma 197
Tuberculous Diseases of the Skin 198
Lupus 200
Scrofuloderma 206
The Tuberculous Ulcer 207
Tuberculosis Verrucosa Cutis 208
Tuberculosis Fungosa 209
Tuberculide 209

PAGE
Lepra 215
Nerve Leprosy 216
Tubercular Leprosy 216
Lepra Anæsthetica Seu Nervosa 218
Madura Foot 224
Aleppo Boil 225
Malignant Growths of the Skin 225
Granuloma Fungoïdes 226
Leukemia and Pseudoleukemia 228
Sarcoma Idiopathicum Hæmorrhagicum 230
Endothelioma Cutis 231
Trichoepithelioma Papulatum Multiplex 232
Sarcomatis Cutis 232
Sarcoma 233
Epithelioma; Rodent Ulcer; Cancer; Skin Cancer 234
Paget's Disease 237
Parasitic Diseases of the Skin 239
The Vegetable Parasites of the Skin 239
Tinea Favosa 239
Tinea Trichophytina 243
Tinea Circinata 244
Tinea Tonsurans 247
Pityriasis Rosea 248
Tinea Versicolor 250
Erythrasma 251
Piedra 252
Trichomycosis Palmellina 252
Actinomycosis 252
Blastomycosis 253
The Animal Parasites of the Skin 254
Scabies 254
Creeping Disease 258
Pediculosis 259
Pediculosis Capitis Seu Capillitii 259
Pediculosis Corporis Seu Vestimenti 259
Pediculosis Pubis 260

INDEX 263

LIST OF PLATES.

Plate 1.	Pompholyx.
Plate 2.	Milium.
Plate 3.	Adenoma Sebaceum. Comedo. Acne Follicularis.
Plate 4.	Acne Vulgaris Disseminata.
Plate 5.	Erythema Multiforme.
Plates 6, 7.	Erythema Bullosum.
Plate 8.	Erythema Exsudativum.
Plate 9.	Erythema Contusiforme et Papulatum.
Plates 10. 11.	Purpura.
Plate 12.	Purpura Rheumatica Fulminans.
Plates 13, 14.	Purpura Papulosa et Bullosa. Leukemia.
Plate 15.	Dermatitis Scarlatiniformis Exfoliativa Toxica.
Plates 16, 17.	Dermatitis Exfoliativa Generalisata.
Plate 18.	Exanthema Bullosum Neuropathicum.
Plate 19.	Herpes Zoster (Sacrolumbalis, Hæmorrhagicus et Gangrænosus).
Plate 20.	Herpes Zoster (Supraorbital and Palpebral).
Plate 21.	Herpes Zoster Cervicalis.
Plates 22, 23, 24.	Impetigo Herpetiformis.
Plate 25.	Pemphigus Vulgaris Diutinus.
Plates 26, 27.	Pemphigus Vegetans.
Plates 28, 29.	Raynaud's Gangrene.
Plate 30.	Dermatitis Factitia (Cantharides).
Plate 31.	Combustio.
Plate 32.	Bromid Acne.
Plate 33.	Ecthyma.
Plate 34.	Furunculosis.
Plate 35.	Psoriasis Vulgaris Punctata et Guttata.
Plate 36.	Psoriasis Vulgaris Confluens.
Plates 37, 38.	Psoriasis Vulgaris Numularis et Scutata.

Plate 39. Psoriasis Vulgaris.
Plates 40, 41. Psoriasis Annularis.
Plate 42. Psoriasis Annularis Serpiginosa.
Plates 43, 44, 45. Psoriasis Vulgaris. Cornua Cutanea (with Degenerative Changes in Right Hand and Left Foot).
Plate 46. Lichen Ruber Planus.
Plates 47, 48. Eczema Artificiale Vesiculosum.
Plate 49. Eczema Artificiale Acutum.
Plates 50, 51. Eczema Impetiginosum Artificiale.
Plate 52. Eczema Bullosum Manus.
Plate 53. Eczema Marginatum.
Plates 54, 55. Eczema Madidans et Crustosum (Mycoticum?).
Plate 56. Prurigo.
Plate 57. Lichen Pilaris.
Plate 58. Ichthyosis.
Plate 59. Ichthyosis Serpentina.
Plate 60. Ichthyosis et Atropia Universalis.
Plate 61. Hyperkeratosis Palmaris.
Plates 62, 63. Acanthosis Nigricans.
Plate 64. Alopecia Totalis Neurotica.
Plate 65. Alopecia Areolaris. Canities.
Plate 66. Vitiligo.
Plate 67. Nævus Pigmentosus Unilateralis.
Plate 68. Hyperchromatosis Arsenicalis.
Plate 69. Achromatosis.
Plate 70. Nævus Verrucosus.
Plate 71. Elephantiasis Cruris—Lupus Vulgaris.
Plates 72, 73. Elephantiasis.
Plates 74, 75. Xanthoma Tuberosum.
Plate 76. Nævus Vascularis.
Plate 77. Nævus Vascularis et Verrucosus.
Plate 78. Lupus Erythematodes Nasi.
Plate 79. Lupus Erythematodes Disseminatus.
Plate 80. Folliclis.
Plate 81. Lupus Vulgaris Serpiginosus.
Plate 82. Lupus Serpiginosus Exulcerans.
Plate 83. Chronic Tuberculosis of the Hand.
Plates 84, 85. Tuberculous Ulcer of Hand.
Plate 86. Chronic Tuberculosis of Skin of Leg. Lupus Tumidus.
Plates 87, 88. Lupus. Phlegmone.

Plate 89. Lupus Hypertrophicus Faciei.
Plate 90. Tuberculosis Subacuta Mucosæ Oris.
Plate 91. Panaritium Tuberculosum.
Plate 92. Tuberculosis Cutis.
Plate 93. Tuberculosis Verrucosa Cutis.
Plates 94, 95, 96. Lepra.
Plate 97. Epithelioma Cicatrisans.
Plate 98. Carcinoma Lenticulare.
Plate 99. Epithelioma of Labium Majus.
Plates 100, 101. Carcinoma Penis.
Plate 102. Favus.
Plate 103. Herpes Tonsurans Maculosus et Squamosus.
Plate 104. Herpes Tonsurans Orbicularis.
Plate 105. Herpes Tonsurans Vesiculosus.
Plate 106. Herpes Tonsurans Orbicularis.
Plate 107. Onychia et Paronychia Trychophytica (Herpes Tonsurans).
Plate 108. Sycosis Framboësioides.
Plate 109. Pityriasis Versicolor.
Plate 110. Actinomycosis.
Plates 111, 112. Scabies Pustulosa.
Plate 113. Maculæ Cæruleæ. Phthiriasis.
Plate 114. Animal Parasites.
Plate 115. Vegetable Parasites.

DISEASES OF THE SKIN.

ANATOMY OF THE SKIN.

THE skin covers the body in various thicknesses. On most regions it is lax and readily movable over the underlying parts, the subcutaneous fascia which connects it with the muscles being loose and elastic. Numerous furrows are to be seen on the surface—partly tension, and partly flexion, furrows—and these are particularly numerous and marked about the joints, and especially so in those of advancing years, in consequence of the loss of elasticity and of the fat-cushion of the skin.

The human skin consists of three layers: the epidermis, the cutis, and the subcutaneous tissue. The epidermis is developed from the outer germinal layer, and the cutis and subcutis together out of the middle germinal layer. The **epidermis** has two main layers:

1. The uppermost layer, the *horny layer*, or *stratum corneum*, consists of variously shaped dried and horny cells, the nuclei having only a shadowy outline, and no longer taking stain; the protoplasmic fibrillation is still retained. These horny, variously shaped cells are enveloped by a thin membrane which is very resistant to chemical reagents. They arise from the underlying prickle layer, the cells of the latter being constantly pressed upward and undergoing cornification.

2. The *rete Malpighii*, or mucous layer, consists of several rows or strata of polyhedral cells, with minute interspaces which are bridged over with intercellular projections or fibers, so that the entire layer appears as a meshwork of cells which are bound together with the projections of

their protoplasm. In the middle of the intercellular bridges is to be found a knob-like swelling of the protoplasm—the so-called bridge-swellings (Brückenknöpfchen). It is to this interlacing of fibers that is due the firmness of the epidermis and its resistance to pressure and traction. In the intercellular spaces, which communicate with the lymph spaces of the cutis, is found a liquid—epithelium lymph—which represents the secretion product of the epidermis cells. The lowest layer of the prickle cells is composed of cylinder cells (basal cylindric cell-layer); above follows the so-called stratum granulosum, whose cells show protoplasm in which granules, hematoxylin-stained, can be demonstrated (keratohyalin). In the layer just above, the stratum lucidum, the protoplasm is stained black by osmium (eleidin); in this layer the cell substance is already liquefied and forms a strong light-breaking mass. On the upper side of the stratum lucidum begins the cornification of the cells, resulting in the stratum corneum.

The elements of the epidermis and the cutis are both, as to their origin and their morphology, sharply divided. Their union is firm and is affected by a sort of rabbeting together, resulting from an interlacing of the down juttings of the rete cell-layer interlocking with upward-projecting papillæ of the cutis; in addition, the rete cells themselves send down prolongations which interlock with upshoots of the connective tissue of the corium.

The two layers of the **cutis**—the papillary layer and the reticular layer—cannot be sharply divided one from the other. The network of the cutis is essentially composed of two different varieties of fibers, which are to be found in both layers; elastic connective tissue, which can be demonstrated by orcein or fuchsin staining, and collagenous connective tissue, which is stained a bright red with acid fuchsin.

1. The *papillary body*, or *papillary layer*, or *pars papillaris*, is exceedingly rich in blood-vessels. The papillæ, which project into the basal layer of the epidermis, con-

tain the endings of the nerves (touch papillæ) and a capillary loop (blood-vessel papillæ). The rows of projecting papillæ into the epidermal layer and the sinking in of the epidermal layer into these interlinear papillary spaces give rise to the furrows and projecting lines of the skin surface. Here and there crossing furrows give rise to the so-called skin fields.

2. The *pars reticularis, cutis propria, stratum reticulare corii,* is made up of a firm meshwork of elastic and collagenous fibers. The diagonal course of the fiber bundles gives rise to polygonal rhomboids, and to this arrangement of the fiber bundles is due the lines of cleavage of the skin of Voight and Langer; these are of importance as predilection points for many skin diseases.

The **color of the skin** is due to the presence of small yellow to brown pigment-cell granules in the cells of the epidermis, as well as to those in smaller number in the cutis. By the mildest degree of pigmentation the color granules are only found in the deepest layer of cells of the rete Malpighii. On certain regions of the body the pigment is found in large quantity, as in the axilla, on the nipple, on the abdomen of pregnant women, on the scrotum, the labia majora, about the anus, etc. Whether the pigment takes its origin in the middle or outer germinal layer is as yet undetermined; also the question of the nature of the chromatophores or melanoblasts, which were by many looked upon as the color-forming organs. Whether these latter, as well as the cells of Langerhans, which serve as end-organs of the sensory nerves, are practically independent individual cells has not been definitely determined. In many of the human races the skin is darker than that of the so-called Caucasian. The parts exposed to air and sun of persons whose work is chiefly in the open are much darker pigmented.

The **subcutis,** subcutaneous fat-tissue, or subcutaneous layer of the skin, which, without sharp division, merges into the papillary body of the cutis, varies considerably in extent on different parts of the body; on the abdominal

region it can be many centimeters thick, while on the vola manus it is present to the least extent. Becoming fat is essentially an increase in the subcutaneous fat-tissue; in advancing years, when the fat diminishes, the skin becomes loose and wrinkled. The subcutis consists of a network of imbedded fat-cells. The fat-cells vary somewhat in size and shape, depending upon the size of the contained fat-drops; in children the cells appear more numerous than in adults. The fat-cells are divided by straight and transverse connective-tissue septa into lobules. In these firm membranous septa most of the blood-vessels of the skin are to be found.

Along with the development of the epidermis, the hair, nails, and glands are also developed from the outer germinal layer.

The **hairs** are to be found almost over the entire cutaneous surface; only the innermost part of the meatus auditorius externus, the vermilion of the lips, the flexor sides of the hands and feet, the ends and neighborhood of the fingers and toes, the glans penis and the inner preputial surface are without hair. Three varieties of hair are usually described: the long hair, the bristle hair, and the lanugo. The thickness of the individual hairs varies considerably, from the thick eyelashes, the medium-thick beard, and genital hair, to that of the finest down on the so-called non-hairy parts of the body.

Every hair consists of a hair shaft and hair root. The essential constituents of the *hair shaft* are the cortical cells, which are elongated fibrillæ and contain pigment-granules and air bubbles. Further, each hair is enclosed in a thin enveloping cuticle of obliquely arranged hyaline cells (cuticula pili). The medulla of the hair is to be found only in the thickest hairs and consists of cornified cells.

The *hair root*, *radix pili*, ends in the *hair bulb*. In the lower end of the bulb is a central hollow space which grasps the hair papilla. The hair root is embraced by the *hair follicle*. The individual layers of the epidermis con-

tinue into the hair follicle. The epithelial layer extends from the mouth of the sebaceous gland to the papilla and is named the *outer root-sheath* of the hair. Within the same lies the hair, which consists of soft matrix cells. Extending from the lateral edges of the papilla to the neck of the follicle is the *inner root-sheath,* which consists of three concentric layers—the outermost layer, the Huxley layer, and the Henle layer. In the hair-matrix in dark-haired individuals are to be found numerous yellowish-brown pigment granules, as well as the before-mentioned chromatophores. All hairs are provided with clustered sebaceous glands. The cylindric arrectores pili are inserted obliquely into the outer root-sheath.

When a new hair is being formed about the hair papilla, the old hair, if it has not previously fallen out, is pushed out by the new-growing hair. The physiologic mission of the hair is the protection of the organism against mechanical insults and temperature influences.

The **nails,** as light, bent horny plates, cover the end phalanx of each finger and toe. At the posterior thin border and at the sides the nail is imbedded in the so-called *nail furrow, sulcus unguis.* The main portion of the nail is the uniform, thick rosy-red *nail body,* the posterior portion of which is known as the *nail root.* At the posterior portion of the nail, especially on the thumb nails, there is a semilunar area of white color. The underlying epidermis is called the *nail bed;* the anterior part is called the *hyponychium,* and the posterior portion the *matrix.* The matrix consists of keratin and is to be looked upon as a thickened rete Malpighii, whose cells, in consequence of higher development, contain keratin instead of keratohyalin. The nails are to be considered as rudimentary seizure organs; they have, however, the further function of protecting the end phalanx against severe pressure and to give the touch portion of the finger proper support.

Over the entire surface of the body, with the exception of the glans penis and the greater part of the inner preputial lining, are to be found **sweat** or **coil glands**; these

are largest in the anal region, and most numerous on the non-hairy parts of the hands and feet. They consist of the *coil* (*corpus glandulæ sudoriferæ*), the secreting portion, lying in the deepest cutis or upper subcutis; and of the winding or spiral *duct* (*ductus sudoriferus*), which opens as the sweat pore, in the stratum corneum. The coil itself is made up of cylindric or cubic cells; these cells contain minute fat-globules, indicating that, in addition to the sweat secretion, these glands also secrete fat. The glands show on their outer part a layer of flat, smooth muscle fibers, and further an elastic membrana propria. The duct shows on its inner portion a pavement-like epithelial layer with a cuticle, and on its outer portion a layer of cells with obliquely placed nuclei.

Blood-vessels of the Skin.—The skin is largely supplied by two arterial systems—a deep plexus and a higher, or papillary, plexus. The vessels of the former come from the muscles and run along the septa of the fat-lobules of the subcutis upward; the fat-tissue, coil glands, and hair papillæ are supplied by this plexus. The papillary plexus originates from the upward branches of vessels coming through the cutis, and continues upward, forming the capillary loops of the papillæ. The papillary blood-vessels possess an arterial and a venous portion, and are therefore true capillaries. In addition, the papillary plexus sends branches to the sebaceous glands and to the follicles.

The **lymph vessels** of the skin form a superficial plexus, communicating with the interior of the papillæ, and also receiving branches from the coil glands and hair follicles. The lymph is a product of the intercellular spaces of the prickle cells and of the canals of the papillary body.

The **nerves of the skin** are most abundant in the balls of the fingers. Both medullated and non-medullated nerves are found intimately associated. The cerebrospinal fibers are the sensory skin nerves, while the sympathetic nerves are supplied to the smooth muscle fibers, the sweat

glands and the blood-vessels. A part of the nerve supply forms an extensive network in the deepest layers of the skin, which breaks up in individual fibers in their upward course. These individual fibers terminate in the end-organs of the cutis. The other part of the nerve branches forms a second extensive network, or plexus, in the papillary body and sends its end-fibers from here into the epidermis. The nerve fibers end in the epidermis either free or as the so-called touch cells (Merkel), to which a nervous function is attributed.

The termination of the sensory nerves of the cutis is either as touch corpuscles of Krause, a nerve coil with a connective-tissue envelope; or in the Meissner touch-corpuscles, into which the non-medullated nerve fiber enters and divides into spiral branches; or, finally, into Vater-Pacini corpuscles or into the quite similar Ruffini corpuscles, through which the nerve fibers, after having lost their medulla, traverse; after exit from the corpuscle the nerve ends in several little connective-tissue knobs.

The vasomotor nerves of the skin are for the most part of the non-medullated variety, which come from the nerve plexus in the depth of the cutis. With the capillaries the non-medullated fibers continue right on to the walls of the vessels and end free with knobs.

Every hair is surrounded by a ring-shaped nerve-plexus, which lies beneath the sebaceous gland.

Finally, nerve fibers are described which penetrate the coils of the sweat glands.

PHYSIOLOGY OF THE SKIN.

The skin is among the most important organs of the body and is intimately associated with the functions of the general organism; so that cutaneous eruptions can give rise to substantial disturbances in the general well-being, and diseases of the internal organs can also manifest themselves by pathologic changes in the skin.

As an **organ of sense** the skin is not the seat of a

special sense-energy, but, in consequence of the presence of its nerve-end organs for touch, warmth, cold, and pain, it can give rise, upon certain irritation, to corresponding perceptions.

The *sense of touch* on hairy regions is dependent upon the nerves of the root sheaths; on non-hairy regions, upon the Meissner corpuscles. The hairs themselves constitute an element of some importance in the sense of touch. In the touch perceptions also the pressure and contact sensations play an important rôle (*pressure sense*, *locality sense*, *space sense*).

In the testing-trial of the exact perceptive power it is found that normally the slightest touch is recognized, while the same cannot be made any more marked through pressure or weight. The sense of localization of the skin is tested by the use of a caliber compass, the subject determining how far the ends are apart; and is best tried and most acute on the balls of the fingers, and least distinct on the back of the hands, on the neck, and under the chin.

The *cold-sense* is dependent upon the Krause terminal knobs, and the *heat-sense* upon the Ruffini corpuscles. On certain points of the surface, the so-called heat- and cold-points, only heat or cold will be recognizable, respectively. On the spots or places where the *touch-sense* is developed to the highest degree the *temperature-sense* is less developed. Temperatures above 116° F. and under 50° F. give rise, as a rule, to the so-called temperature pain, the pain from heat appearing more frequently than that of cold. By simultaneous contact of the surface with cold and warm agents, the cold is felt more quickly than the warm.

The *sense of pain* is seated, according to von Frey, in the free nerve-endings in the epidermis; the same writer gives certain pain-points which are distinct from the pressure-points. The pain-sensitiveness is increased by the expectation or idea of pain.

The skin takes part in the *general body-interchange of matter*. While the epidermis forms a guard against the

penetration of liquids, and in dry or oily condition is practically impassable for the same, it, when thoroughly wet or water-soaked, permits the penetration of small quantities. The electric current makes it penetrable for certain substances, and this fact has led to the known method of treatment by cataphoresis. Also some firm or more solid substances, as, for example, mercury in salve form, are able to penetrate the epidermis; the mercury does not, probably, gain entrance in its original form, but only after some chemical change. In consequence of the penetrability of the skin for gaseous substances, it is capable of a **respiratory function,** although for the interchange of matter this power is insignificant. In skin respiration oxygen is taken up, and carbonic acid, water, and a very little nitrogen are given off. Of these the most important as to quantity is water, and of this the richer the skin is in glands the greater the quantity. The suppression of the function of perspiration is accompanied with more or less risk to the organism, as shown in cases of burns. It is known that human beings and animals die when they are deprived of one-third of the skin.

The skin secretes, from the corresponding glands, **sebum** and **sweat.** The sebum is excreted from the hair-sebaceous glands, and most profusely on the eyelids (Meibomian glands) and in the preputial sac. The secretion of the sebaceous glands consists primarily of cell growth and later cell fatty degeneration; it begins in childhood in the face and scalp and increases gradually, becoming less again in advancing years.

By means of the sweat glands, which, especially in the face, axillæ, on hands and feet, are largely developed, and which are in very large numbers over the entire surface, a considerable quantity of liquid can find exit through the skin. The sweat consists almost wholly of water, with mostly acid reaction, and contains, as shown by microscopic examination, epidermis scales and fat-granules. The sweat secretion is much increased by high body-temperature, physical work, psychical excitation, dyspnea, and

certain poisons (nicotin, pilocarpin, etc.). The sweat secretion is an important means of discharge in disturbed kidney-function, inasmuch as it can take up a part of the duty of the latter. The sweat plays also a great rôle as a **heat-regulating factor** in maintaining an equilibrium of body heat. The skin keeps within the organism a certain quantity of heat, guards this against different outside temperatures, shares in the necessary heat formation, and in consequence of its constant contact with the surrounding air maintains an equilibrium between the body temperature and the outside air temperature. With a fairly constant and equable temperature of the outside air the rate of formation of body heat under normal circumstances is unchanged; with greater temperature fluctuations of the surrounding air or objects the organism reacts immediately with a corresponding diminution or increase of the body-warmth. This modification of the heat formation is excited voluntarily (active muscular movements, hot drinks, etc.) or involuntarily (muscular contractions, shivering, etc.).

In old age there develops a **senile degeneration of the skin,** which is probably in consequence of the influence of light and air. In addition to a degeneration of the elastic tissue (elacin, Unna), there is also an increase in the pigment cells in the hair bulb and around about the hair root, in consequence of which the senile, loose, markedly wrinkled skin takes on a brownish color.

GENERAL PATHOLOGY OF THE SKIN.

The symptoms of skin diseases are divided into subjective and objective. To the former belong the various painful, itching, and burning sensations, etc.; further, those accompanied by a feeling of tension, disturbances of sensibility, anesthesia, and paresthesia. Of greater importance are the visible changes on the surface—objective symptoms—of the skin, the so-called cutaneous lesions or efflorescences, as they offer the necessary points for diagnosis.

These are conveniently divided into two classes: the primary efflorescences or lesions and the secondary efflorescences or lesions.

To the **efflorescences** or **primary lesions** belong the so-called *macules*, or spots (maculæ). An eruption of hyperemic macules, or spots, up to the size of a finger-nail, is generally called *roseola;* when they are larger, *erythema*. Hemorrhages into the skin in macule form are usually designated *purpura;* when these are minute in size, or petechial, are named *petechiæ;* when stripe-like or linear, *vibices;* when of larger size, *ecchymoses*. All these variously named efflorescences, as well as *telangiectases* and *nævi vasculosi*, arise through pathologic changes in the papillary body. Pathologic processes in the cutaneous tissues can also give rise to macular efflorescences, such as xanthoma (yellow macules, or spots), tattooings, scleroderma, etc. Among macular pigment anomalies of the skin may be mentioned *albinismus*, *vitiligo*, *chloasmata*, and other pigment blemishes.

Circumscribed hyperemia with consecutive serous exudation and inflammation gives rise to a passing or evanescent cutaneous edema and the formation of a *wheal* (urtica) which characterize urticaria, and which in consequence of the compression of the papillary vessels has mostly a waxy or porcelain-like color.

Persistent solid elevations above the surface of the skin are known as *papules* (papulæ), and are very variable in their appearances, and may be due to entirely different processes (tuberculosis, lichen pilaris, syphilis, etc.). The larger and firmer solid lesions are known as *tubercles*, *nodules*, *tumors*, etc.

Vesicles (vesiculæ) and *blebs* (bullæ) are lentil- to fist-sized epidermal elevations, with clear or translucent contents, which arise through exudative inflammation of the papillary body, as in bullous erythema multiforme; or intra-epidermoidal, as either in the rete Malpighii, or beneath the horny layer (combustio, herpes, eczema, etc.).

In consequence of the entrance of pus-exciting organ-

isms in such vesicles or blebs, or from the migration of leukocytes into a preformed cavity, *pustules* (pustulæ) are formed. Larger pustules with inflammatory base and areola are named *ecthyma;* seropurulent pustules with thin and drying contents, *impetigo.*

Among **efflorescences** or **secondary lesions** rank first in importance excoriations, epidermal exfoliation, mechanically produced tissue-loss of the epidermis of various extent and depth, as from insect bites, pediculis vestimentorum, or from itching dermatoses (prurigo, etc.).

Cracks and **fissures** are tears in a pathologically changed skin, which, according to their depth, either weep or bleed.

Crusts are formed from the drying up of the contents and covering of blebs or vesicles, or of purulent lesions; there is often an admixture of blood. When a crust consists of tile-like layers with a lessened thickness peripherally, it is given an oyster-shell-like aspect, and such lesions are called *rupia.* [While rupia-like crusts may be seen occasionally in other diseases than syphilis, it is usually significant of the large pustular or bullous eruption of this latter disease, so that when the term rupia is used alone it generally refers to the syphilitic eruption.—Ed.]

Increased exfoliation of the horny cells of the epidermis (desquamation) leads to the formation of small and large *scales* (squamæ). They indicate either an inherent anomaly in which, owing to an inflammatory process, the horny cell proliferation and exfoliation are pathologically increased—for example, as with the *parakeratoses*—or the scale formation takes place spontaneously without inflammatory accompaniment through simple hypertrophy, as in the *hyperkeratoses*, to which category belong all idiopathic increases of the horny layer (*ichthyosis*). By *acanthosis* we understand an increase in the prickle-cell layer, which clinically is made known by a varying exaggeration in the surface lines and papillary prominences of the skin.

The more severe inflammatory processes with tissue destruction (necrosis) give rise to *ulcers* of the skin (ulcera).

When this action extends down into the true skin, healing takes place by connective-tissue new formation and results in a *scar* (cicatrix). The scar is in its earlier period, owing to its thin epidermis, reddish in color; gradually it becomes, from the absence of pigment, white and lacks the normal appearance of the skin, as well as wanting in hairs, inasmuch as the hair papillæ have been destroyed. The character and appearance of the scar are often clearly indicative of the nature of the malady which had caused it; a scar with a net-like surface-formation is indicative of tuberculosis, serpiginous scars point to syphilis, etc. Scars resulting from inflammatory processes without ulceration (skin gummata, lupus erythematosus, ulcus rodens) are called *atrophic scars*.

Efflorescences may be solitary (*efflorescentiæ solitariæ*) or scattered (*dispersæ*), crowded together (*aggregatæ*), or in circles or segments of circles (*efflorescentiæ annulares, circinatæ*). The latter frequently form when the process spreads at the periphery and undergoes involution in the center. The name *iris* (herpes, or erythema iris) is given to that form in which several circles of efflorescences occur around a primary focus. *Gyri* are more or less circular lines, which are formed by the confluence of several circles and segments of circles. *Exanthem* designates a cutaneous eruption which is distributed over large surfaces or over the entire body.

It remains to be stated that some dermatoses have certain **parts of predilection,** a knowledge of which is often of great significance in the differential diagnosis; this will be referred to in considering the diagnosis of particular diseases.

Diseases of the skin may be either **acute** or **chronic.** Under those termed chronic are in general included two groups: those in which the lesions themselves as well as the disease are of long duration, and those cases of chronic recurrent diseases in which fresh acute outbreaks arise continuously or from time to time.

GENERAL THERAPEUTICS.

In dermatology we are as yet far from attaining the desired object of our therapeutic endeavors—to treat forms of disease according to their etiology. In but few skin diseases has the question relating to the primary or essential causative factor or factors of an affection been satisfactorily settled; the treatment of the greater number of diseases is still based upon the symptoms. As these are subject to changes during the course of a malady the therapeutic indications also change; it is accordingly of great importance to the physician to recognize each of these several phases or stages, and he will then be enabled to use intelligently the numerous remedies which dermatologic therapeutics places at his disposal.

Internal Treatment.—The older practitioners recommended and employed various internal remedies in skin diseases. Nearly all of these have been forgotten at the present day; the ideas, however, of treating skin affections by placing stress upon dietary rules and internal medication are again coming more and more to the front. In some skin diseases dietary regulations are not only strongly to be advised, but are even indispensable. One need, for instance, only recall urticaria, often due to ingestion of certain kinds of food, and which may appear at other times when intestinal digestion is imperfect or faulty; and the erythemata, which occur under similar etiologic conditions; and also the eruptions of eczema in diabetic, nephritic, and gouty individuals.

It is therefore surely an error to practise dermatology with the aid of the ointment pot alone: just as it would be, on the other hand, to endeavor to combat marked changes in the cutaneous integument by simply forbidding certain articles of food.

Of the internal remedies we desire to mention the following: Arsenic, mercury, iodin, tar preparations, pilocarpin, atropin, quinin, sodium salicylate, antipyrin, pyramidon, aspirin, thyroid preparations, yeast preparations,

menthol, etc. Some cases are benefited by a course of treatment with the natural mineral waters (Carlsbad, Franzensbad, Levico, Roncegno, Hall, Lipik [and in our own country Richfield Springs, Hot Springs of Virginia, Healing Springs, Bedford Springs, and many others well known.—Ed.]).

External Treatment of Skin Diseases.—We employ the following means:

1. *Water* for ablutions and for partial and full baths; the cold water as an astringent and warm water dilating the vessels. The continuous water bath (Hebra's water bed) may be employed in pemphigus foliaceus, decubitus, extensive burns, universal psoriasis, lichen ruber, and pityriasis rubra Hebra. Medicated baths are baths containing alkalies, potassium sulphid, brine, tar, corrosive sublimate, bran, oak bark, etc.

2. Besides waters, the *fats* serve materially for the purpose of softening morbid accumulations on the skin. Mineral, vegetable, and animal fats, in solid and fluid form, are employed; they are used alone or as vehicles for medicaments. We mention those most frequently used: Petrolatum, vasogene (oxygenated hydrocarbons), vasole (Hell), cacao butter, ol. olivæ, ol. amygdalarum dulc., ol. lini, ol. rapæ (rape-seed oil), ol. ricini, lard, spermaceti, œsypus (the natural fat of wool), adeps lanæ (wool fat), lanolin [this is not a fat, but consists principally of ethereal fatty acids of cholesterin and isocholesterin, which are also found in all tissues containing keratin and in the human skin and human hairs, and of free fatty acids (up to 30 per cent.)], cod-liver oil, and oleum physeteris.

Further: Mollin (an overfatty soap made of pure kidney fat and the finest Cochin cocoanut oil, saponified by mixing potash and soda lye and addition of glycerin), resorbin (made of almond oil, wax, and addition of gelatin, soap, and adeps lanæ), glycerinum saponatum (H. v. Hebra), epidermin (Kohn), unguentum lanolini (Paschkis), vaselinum lanolinatum (Hell), and glycerin.

Salve mulls (Salbenmulle) (Beiersdorf) are bandages spread with special salve mass variously medicated, which do not adhere to the skin, but must be kept in position by suitable bandages. The fatty mass of the ointment mulls consists principally of sebum benzoinatum, with addition of more or less wax.

A very practical form of salve application is with the so-called *salve pencils* (Unna), which are made with various medications; their basis consists of wax, salad oil, and some resin.

Cooling salves [of which cold cream is a familiar example—Ed.] are mixtures of fat and water. Through the evaporation of the water constituent heat is drawn from the skin and a cooling influence exerted.

3. *Soaps.*—These are combinations of fatty acids with alkalies. We distinguish between soft soaps (fat saponified by potash lye) and hard soaps (fat saponified by soda lye). When all of the alkali of the soap is combined with fatty acids the soap is *neutral*. The action of the soaps is said to be due to the soluble basic, fatty-acid salt. In addition to the chemical action of a soap there is also a mechanical action. Overfatted soaps are those which contain along with the fatty-acid salts, of which neutral soap consists, a certain quantity of unsaponified fat. Unna's overfatted or basis soap is made of the best beef-tallow and a mixture of two parts of soda lye and one part of potash lye; sufficient olive oil is added to the soap mass so that about 4 per cent. will remain unsaponified. Eichhoff has produced soaps containing various pulverulent substances.

Very useful is an addition of powdered chalk, powdered marble, or sand to a soap (Sanger, Schleich), as this increases the mechanical effect of the soap, and is found desirable in many dermatoses. Of the liquid soaps, that recommended by Buzzi, the liquid sulphur soaps (Thiosavonale), and finally Sarg's liquid glycerin soap should be mentioned.

We employ, in addition, Hebra's "spiritus saponatus

kalinus" (tinctura saponis viridis) according to the following directions:

℞ Saponis viridis, 100 (ʒiij).
Solve leni calore in
Spirit. vini, 200 (ʒvj).
Filtra et adde
Olei lavandulæ,
Olei bergamottæ, āā 3 (gtt. xlv).
Misce et filtra.
Sig.—Spiritus saponatus kalinus (tinctura saponis viridis).

Finally, a number of medicated soaps (naphtol-sulphur soap, sulphur and tar, corrosive sublimate, menthol, thymol, resorcin, etc.).

4. *Varnishes.*—Excipients which, when painted on the skin, dry and form a smooth coating.

a. Varnishes soluble in water: Linimentum exsiccans Pick consists of tragacanth, 5 parts; glycerin, 2 parts; distilled water, 100 parts.

Unguentum caseini Unna consists of alkali casein, glycerin, vaselin, and water. It is miscible with all substances which do not coagulate casein. Tar up to 20 per cent. may be added to the casein ointment, although with this an addition of 1 part of sapo viridis to 4 parts of water is recommended, so as to render the product less acid. Rubbed on the skin, it dries into an elastic, smooth layer.

Gelanthum consists substantially of tragacanth, gelatin, and water.

Gelatin paste, according to Unna's formula, is as follows:

℞ Gelatinæ alb., 30 (ʒviiss);
Zinci oxid., 30 (ʒviiss);
Glycerini, 50 (fʒxiiss);
Aquæ, 90 (fʒxxiiss).

The gelatin is dissolved in the water over a water bath, the glycerin added, and the zinc oxid well incorporated. When desiring to use, melt over water bath and paint on with brush.

b. Varnishes insoluble in water: Collodion, traumaticin (liquor gutta-perchæ), liquor adhæsivus Schiff or filmogen (cellulose nitrate dissolved in acetone with addition of oil).

5. *Pastes.*—These are firm mixtures of fats, oils, or glycerin with pulverulent substances. These latter constituents give the preparation a porous and moisture-absorptive powers, sometimes very desirable in an application to the skin. As a paradigm can be mentioned *Lassar's paste*, which is made according to this formula:

℞	Acid. salicylici,	2 (gr. xxx);
	Zinci oxidi,	
	Amyli,	āā 24 (ʒvj);
	Vaselin,	
	Lanolini,	āā 25 (ʒviss).

Among other pastes may be mentioned bole paste, lead pastes, dextrin pastes, gum (acacia or tragacanth) pastes; and further the serum pastes, peptone pastes, and wax pastes (Schleich).

6. *Plasters.*—These consist of lead and soap, or of a mixture of turpentine, various resins, and fats, or of varying proportions of the two plasters.

The Unna-Beiersdorf gutta-percha plaster mulls are plasters in which the fabric is first coated with a thin layer of gutta-percha. The thickly applied plaster mass consists principally of caoutchouc with addition of adeps lanæ, and is variously medicated. The "paraplasters" have as base a close cotton material of very fine fiber, which is saturated with a solution of caoutchouc and vulcanized. Collemplastra are plasters in which caoutchouc is mixed with the plaster mass.

7. *Powders.*—As such are employed: Vegetable substances, as amylum oryzæ, amylum tritici, lycopodium,

pulvis radicis, irid. flores; and mineral substances, as talcum venetum, zinc oxid, bolus, terra silicea, bismuth subnitrate; and of animal substances, conchæ præparatæ, ossa sepiæ pulv. To such powders medicaments are often added, such as dermatol, tannoform, salicylic acid, calomel, etc.

8. *Caustics* are applied for the destruction of pathologic products, as lupus tissue, warts, nevi, condylomata, new growths, etc. Further, for the softening of callosities and horny masses, for the destruction of overabundant granulations, and, on the other hand, for the stimulation of the process of granulation. Among those employed may be mentioned nitric acid, silver nitrate, chromic acid, corrosive sublimate, carbolic acid, and lactic acid.

9. *Mechanical and physical methods* of treatment have grown in importance of late years, and are still gaining more extended use in dermatotherapy. Especially is this true as regards the employment of the Röntgen rays, the light treatment of Finsen, and the use of radium. Concerning the special indications for the employment of these agents, more will be said in connection with the diseases in which they are employed.

DISORDERS OF THE SWEAT GLANDS.

Pathologic increase of sweat secretion (**hyperidrosis**) is usually observed in corpulent individuals, in psychic excitement, and also after conditions which lead to hyperemia of the skin. Profuse sweating often occurs in cachectic, tubercular, and anemic subjects. Subjective symptoms of prickling and slight itching of the skin sometimes may precede the sweating.

Hyperidrosis may be either general or local or partial. Increase in sweat secretion of certain regions of the body, as the palms of the hands and the soles of the feet (*hyperidrosis palmarum et plantarum*), is to the individual thus afflicted of considerable importance. Hyperidrosis of the feet is usually most marked between the toes, greatest at

the big toe, and lessening somewhat toward the smaller toes; the sweat may undergo rapid change and give rise to an offensive odor. In moderately developed cases there is frequently a thickening of the sole (hyperkeratosis), and in extreme cases a thinning of the plantar epidermal layers. Hyperidrosis of the palms is also a highly troublesome disorder.

It is common in anemic subjects, whose hands and feet are cyanotic, owing to stasis, and who complain of sensations of cold in the extremities. This excessive sweating may exist for many years without any change whatever taking place in the skin. In rare instances vesicles sometimes may form on the fingers, more frequently on the toes; these rupture and lead to excoriations of the epidermis [dysidrosis, pompholyx?—Ed.]. The epidermis between the toes is frequently macerated and peels off; painful excoriations and fissures occur, which may give rise to troublesome inflammation, and exceptionally to the formation of pus.

Offensive and bad-smelling sweat secretion is known as **osmidrosis, bromidrosis,** or stinking sweat.

Under the head of *universal* or *general hyperidrosis* we include prickly heat; febris miliaria, the etiology of which is not yet clearly understood; and miliaria crystallina, or sudamen, which, as an accidental or occasional accompaniment of various febrile and septic diseases, is characterized by small, non-inflammatory, drop-like vesicles, having a resemblance to dew drops. This last (**miliaria crystallina**) results from the collection of secretion in the duct of the sweat glands. **Miliaria rubra** (prickly heat, heat rash) appears in the form of rounded, vividly red, elevated papules, occurring during the warm season of the year and very largely in infants and fat people. It may be present also after the use of salt-water baths. From the addition of leukocytes the papules and vesicles may become gradually milky, thus presenting the so-called **miliaria alba.** Both forms of miliaria—miliaria rubra and miliaria alba—were designated by Hebra as eczema sudamen or calori.

The general condition is usually not disturbed in this affection. Fresh-water baths [and keeping the skin dry with dusting-powders—Ed.] soon bring the malady to an end.

Miliaria epidemica is a rare disease of greater importance. It occurs epidemically, and is ushered in by rigors and fever; the patients sweat profusely and are very dull. The skin of the neck and rump is covered with tubercles, vesicles, or pustules.

The entire aspect of the disease conveys the impression of its being due to general systemic infection, and this view gains in importance owing to the individuals developing constant fever, dulness, and stupor, and frequently perishing. During the epidemic of 1892 observed in Carinthia 24 per cent. of the cases proved fatal.

Conditions of temperature appear to influence the origin of this disease; the epidemics occur principally during the spring and summer, when the atmosphere is warm and moist. Nothing characteristic is found at post-mortem; it is striking, however, that such cadavers decompose very rapidly.

Blood and constituents of the urine (uric acid, urea) have also been secreted by the sweat glands (**hematidrosis** and **uridrosis**). The transfer of pathogenic micro-organisms into the coil of the sweat glands has also been observed in several instances.

Dysidrosis, pompholyx, or **cheiropompholyx** [Hutchinson] occurs on the palms of the hands, on the sides of the fingers, and on the soles of the feet, owing, it has been believed, to retention of sweat. Vesicles and blebs, from the size of a pinshead to that of a pea, or larger, develop; their contents are perfectly clear at first, though they become turbid later. The inflammatory symptoms, redness and slight or marked swelling of the epidermis, complete the picture of this disease. The affection disappears after the vesicles have ruptured spontaneously or have been ruptured by macerating treatment or accidentally. As the disease, however, relatively often

attacks individuals who suffer from sweating feet, its recurrence is not uncommon (Plate 1).

In people of middle and advancing age who come in contact with warm vapor and steam, especially in women cooks, the face may become the seat of pinhead to pea-sized vesicles, bearing a resemblance to boiled sago grain (**hydrocystoma**), and which have their formation in a distention of the sweat duct lying in the cutis.

While sweat-secretion anomalies or disorders are quite common, demonstrable histopathologic changes in the sweat glands are exceedingly uncommon, in spite of the fact that there are innumerable sweat glands scattered over the entire surface. The reason for this is probably in the fact that these structures are deeply situated and thus protected, and, further, that penetrating micro-organisms meet with the often-rapid and constant flowing of the thin secretion, and thus are washed away or eliminated. As to the sweat-gland tumors, which are themselves also uncommon, adenoma, syringoma (hydradenoma), and epithelial carcinoma will be described later.

Treatment.—In universal as well as local hyperidrosis, it is of great importance to consider the possible underlying cause or causes (tuberculosis, anemia, etc.). Of internal remedies which have the power of influencing excessive secretion of sweat we mention especially atropin and agaricin.

℞ Atropin. sulphat., 0.015 (gr. $\frac{9}{40}$);
Extr. taraxaci,
Pulv. rad. althææ, q. s.
Ft. pil. No. xx.
Sig.—One pill night and morning.

Or

℞ Atropin. sulphat., 0.01 (gr. $\frac{3}{20}$);
Aq. menth. pip., 10 (f℥iiss).—M.
Sig.—Five to ten drops t. d.

℞ Agaricini, 0.015 (gr. $\frac{9}{40}$).
In pil. No. xxx.
Consperg. sem. lycopod.
Sig.—One pill t. d.

The following are advised in the external treatment: Baths, ablutions, and applications of alcoholic solutions, such as menthol (1 : 100), carbolic acid (1 : 100), salicylic acid (1–2 : 100), naphtol (β-naphtoli), 1 (gr. xv.); aqua coloniensis, 25 (ʒvj et gtt. xv); spir. vini. gall., 175 (ℨvss). A dusting powder should be subsequently applied. The following is useful for this purpose:

℞ Salol., 1 (gr. xv);
Zinci oxidi,
Talc. ven., āā 45 (ℨiss).—M.
Sig.—Dusting powder.

Or such with salicylic acid, boric acid, tartaric acid, dermatol, tannoform.

In hyperidrosis pedum Hebra's favorite treatment with unguentum diachyli is often useful. The feet are daily enveloped with bandages spread with ung. diachyli, pledgets of lint smeared with this ointment being placed between the toes. This proceeding is continued for ten to fourteen days, during which period the feet are not to be washed. A few days after the dressing has been discontinued the skin exfoliates, and when desquamation has ceased the hyperidrosis is usually noted to have been relieved. A repetition of the treatment is often necessary.

Applications of a 5 per cent. solution of chromic acid, solutions of formalin and corrosive sublimate are to be recommended; also painting with the following:

℞ Liq. ferr. sesquichlorati, 30 (fʒviiss);
Glycerini, 10 (fʒiiss);
Ol. bergamottæ, 20 (fʒv).—M.
Sig.—To be applied with a brush to the sole of the foot and the regions between the toes (Legoux).

In addition to these, the above-mentioned dusting powder, especially tannoform (tannoform 1 part, talcum 2 parts).

DISORDERS OF THE SEBACEOUS GLANDS.

The sebaceous secretion of the skin is the product of the sebaceous glands, whose fat-cells secrete the nascent sebum found on the surface. An abnormal increase in the amount of sebaceous matter is known as **seborrhea,** which, when it appears in the form of an oil coating, constitutes the condition known as *seborrhœa oleosa;* when the excessive sebaceous secretion dries up with the loose epidermic cells into scales, it gives rise to the type known as *seborrhœa sicca seu squamosa.*

Oily seborrhea may exist for years on the nose, forehead, and chin of many individuals without demonstrable cause; it may also be seated upon the scalp. Seborrhœa sicca is observed most frequently. It may be observed at almost any age, but is more common during adolescence and early adult life. It is also noted on the scalp of nursing-infants as a dry, hard crust, which adheres to the tender hairs.

The **vernix caseosa** is of similar origin, and occurs in newborn infants as smegma, covering the whole body and consisting chiefly of detached epithelium. When this condition is more or less persistent, it has been designated *cutis testacea* or *ichthyosis sebacea* (Hebra).

The same disease is exemplified in collections of smegma in the preputial pouch in balanitis and balanoposthitis, and on the prepuce of the clitoris and interlabial folds; these conditions lead to maceration of the epidermis and to excoriations, and even to inflammation accompanied by secretion of pus.

Eczema seborrhoicum (Unna), or seborrhœa congestiva, generally takes its origin in the scalp. The scalp is either covered with fine branny exfoliating scales or with yellowish fatty crusts. The affection can also invade

the nose, cheeks, and ears, and in occasional instances the whole face. The seborrheic basis of such an eczematous eruption is sometimes only recognizable by the effect of the sulphur treatment as compared with that of ordinary eczema.

When seborrhea has existed for a longer period it gives rise to **comedones** (Plate 3). These formations are also noted when there is but a slight oily or branny seborrheic condition of the surface of the skin. The fat and loose epithelium become inspissated in the excretory duct, lanugo hairs and the demodex folliculorum (Plate 114, Fig. 1) are mixed with this secretion, and the dilated follicle is filled with a greasy mass having a black external covering. These plugs are frequently loosened by the accumulating secretion beneath in the follicle, and can be readily removed. The excretory duct, which has become patulous, can be seen as an opening in the skin. Comedo formation is due to retention of sebum in the duct of the gland, probably in consequence of a hyperkeratosis of the duct outlet.

Owing to increased accumulation of sebum in the cystic, dilated excretory ducts, the comedones may be converted into the so-called giant comedones, from the size of a pea to that of a bean. In chronic processes retention cysts—*mollusca atheromatosa*—of various sizes are not uncommon (*vide* Plate 3). These can also break down and become soft fluctuating tumors. These retention cysts are not to be confounded with dermoid cysts, which are true atheromata.

As a consequence of comedo or blocking of the sebaceous ducts, inflammation of the sebaceous glands—*acne*—finally results, which will be discussed later on.

Treatment of Seborrhea.—The accumulated scales and crusts should be softened with oils or fats and then removed. When this has been done, or to aid in this, the scalp is thoroughly washed with soap (tinctura saponis viridis) and lukewarm water. The scalp, which may have become sensitive and moist, is covered with ointment.

Zinc oxid, sulphur and salicylic acid, sulphur and zinc oxid, in ointment form, and pastes of sulphur and zinc oxid are employed:

℞ Zinci oxidi, 5 (gr. lxxv);
Sulph. præcip., 3 (gr. xlv);
Terr. siliceæ, 2 (ʒss);
Adipis benz., 25 (ʒvj).—M.
Ft. pasta (Unna).

Ointments of white and red precipitate, 5 to 30 grains to the ounce, are preferable if the hair is long or has not been cut. [Ointments containing pulverulent substances in any quantity are not so well adapted for scalp treatment as those just mentioned or those containing salicylic acid, resorcin, or sulphur, 5 to 30 grains to the ounce.—Ed.]

Conjointly or alternately with ointment we use ablutions containing spirituous solutions of carbolic acid (0.35–0.70 (gr. v–gr. x) to the ounce), salicylic acid, β-naphtol, and resorcin; the last in ointment, 2 to 10 per cent. strength, or either in alcoholic or aqueous solution of 2 to 4 per cent. Formalin lotions [should be weak—Ed.] are also occasionally commended.

When the disease is localized on other parts of the body, treatment based on the same principles is employed, but the applications should be weaker. In balanitis and balanoposthitis, washing with weak alcoholic solutions, with supplementary applications of dermatol, tannoform, etc.

PITYRIASIS CAPITIS (SEBORRHŒA SICCA).

[The author, while placing this under seborrhea, recognizes its clinical difference by giving it a special heading for treatment. Most writers consider this as belonging to Unna's seborrheic eczema.—Ed.]

The method of treatment, as recommended by Lassar, should be mentioned first. This consists of:

1. Shampooing with tar soap for from ten to fifteen minutes; this is washed off with warm water, which should be gradually cooled.

2. Washing with

℞ Sol. hydrarg. chlorid. corros., { 0.50 : 150 (gr. viiss to ℥v water);
Glycerini,
Spir. coloniensis, āā 50 (f℥xiiss).

3. Applying

℞ β-naphtol, 0.25 (gr. iv);
Alcohol. absolut., 200 (f℥viss).—M.

4. Rubbing into scalp

℞ Acidi salicylici, 2 (gr. xxx);
Ol. olivæ, ad 100 (f℥xxv).—M.

In connection with soap-washing and spirituous applications to the scalp, sulphur ointments will also give good results in these cases. We also use (in alcoholic solution, frequently with the addition of oleum ricini) tincture of cantharides, tincture of capsicum, resorcin, corrosive sublimate, quinin, chloral hydrate, captol, and tar preparations.

MILIUM (Plate 2).

In this condition round grains the size of a millet seed, of a milky-white color and slightly raised above the level of the skin, can be seen shining through the epidermis. They are met with chiefly on the eyelids, cheeks, temporal regions, and male genitalia; rarely on the labia minora. When the epidermis is incised and these small bodies have been removed from their bed, they fall to pieces on slight pressure. They consist of dry epidermic cells and fat. Owing to mechanical obstruction, as, for example, in scars, milia are not infrequently formed from a drying-up of the secretion in superficially lying lobules of the gland.

Treatment.—The overlying skin is incised with a small knife and the contents removed by lateral pressure. The ensuing wound, which is insignificant, heals very

rapidly. When a large number of small milia exist, a desirable method of treatment is that which produces exfoliation of the epidermis; and this may be attained by exciting a moderate degree of inflammation by stimulating the skin with applications of soft soap (Kaposi).

Sebaceous-gland adenoma, *adenoma sebaceum*, appears especially on the nose, and consists of yellowish-red, small, pea-sized growths, which are probably congenital. Histologically it consists of a hypertrophy of the entire glandular tissues. The treatment is purely surgical.

MOLLUSCUM CONTAGIOSUM.

The names *Molluscum Contagiosum*, *Molluscum Verrucosum*, *Molluscum Epitheliale* are applied to a verrucous proliferation on the skin, appearing as a rounded, shining, pearly, translucent, slightly elevated growth, and usually attaining the size of peas, which project hemispherically and show a slight depression at their apex. Lateral pressure with the fingers or curetting causes the contained whitish mass to be ejected, which is seen to be lobular in construction and surrounded by a thin covering of connective tissue; this sends out processes which converge toward the center as septa. The mass often has a firmer cover; it can be easily crushed to pieces, and the contents are found to be made up of epidermic cells, fat, crystals of fat, and so-called molluscum bodies. These latter are structureless, slightly shiny formations of ovoid shape, smaller than an epithelial cell, and are usually surrounded by epithelial cells and cell débris (Plate 65, *b*).

Molluscum contagiosum has been demonstrated to be contagious; the growths are often found on contiguous surfaces of the skin and in individuals who are in close contact with one another (children and nurses). The most common sites are the face, eyelids, the genitalia, scrotum and penis, the external female labia (see *Atlas of Syphilis*, Plate 71), and inner folds of the thighs. They also occur on the neck, hands, and forearms, and may even

be distributed over the general surface, as observed by Kaposi in a small child.

Treatment.—The contents are usually removed by lateral pressure; when the lesions are numerous or persistent, removal by surgical means (Volkmann's spoon; excision) is recommended. Puncturing with a pointed knife, pressing out the contents, and touching the interior with carbolic acid or silver nitrate will usually suffice.

ACNE.

Eruptions which are situated principally on the face, and which, upon superficial inspection present a similar appearance, have heretofore been included under the general term of acne. Formerly *acne vulgaris*, *acne rosacea*, and *acne mentagra* (sycosis) were discussed together, although each disease depends on a different pathologic process.

At the present day we designate as acne a disease consisting essentially of an inflammation of the sebaceous follicles.

It may depend upon various causes. In many instances the irritation of the cutaneous follicle and resulting inflammation are due to external noxious influences. Not infrequently we must seek the predisposing cause in the organism itself—*e. g.*, cachexia, debility. Finally, we are acquainted with substances which, during their excretion from the body through the skin, give rise to folliculitis (toxic acne). Some authors would regard staphylococci as the cause of some varieties (blepharitis ciliaris, hordeolum). Acne correspondingly presents different clinical pictures and does not always pursue the same course.

The various acne-form eruptions, sometimes considered along with acne as aberrant forms of the same, but which we now know are not true examples of the disease, will be found referred to under the head of the acne-form tuberculides (Hallopeau). Among these belong *acne cachecticorum*, *acne telangiectodes* of Kaposi, *acne varioliformis*

of Pick and others, and the *acne serpiginosa nasi* of Kaposi.

Acne vulgaris, or acne, appears on the face (nose, forehead, chin, and cheeks), on the chest, and on the back (Plate 4). Both sexes are attacked alike. Chlorotic, anemic girls are especially predisposed; also boys, probably more than girls, during the period of puberty (sixteen to twenty years), when the beard begins to grow. Digestive disturbances, such as habitual constipation, indiscretions in diet, etc., are frequently mentioned as causes. We cannot up to the present time offer a plausible explanation for this frequent complaint. We would, however, not like to be considered as regarding the above-named disturbances as entirely without influence in producing the disease. In such individuals the secretory activity of the sebaceous glands is noticed to be increased; very frequently seborrhœa oleosa is also present. Acne vulgaris probably arises from secondary infection of a comedo. The first step in the production of acne, however, is interference with free excretion by sebaceous plugs or comedones forming in the outlets of the sebaceous glands and follicles; this leads to swelling and inflammation of the follicles and the *neighboring* surrounding tissue; the black plugs can be usually seen in the middle of the papules (*acne punctata*). Where the sebaceous glands are more numerous, as on the forehead, the nasolabial folds, and chin, acne papules frequently make their first appearance, and are usually more numerous here throughout the course of the disease. Aggravated cases, with increased swelling and inflammation, take on a reddish-blue color and have a pustule in their center (*acne pustulosa*). After spontaneous opening of the same, occasionally, slight scars are left. On the eyelids are sometimes found hard linear lesions (*acne hordeolaris*).

Histologic examination of the inflamed infiltrated follicles and immediate surroundings discloses the presence in the latter of giant and plasma cells. Unna has found a bacillus which he considers pathogenic, but this requires

confirmation. [Gilchrist's investigations have added evidence to this belief.—Ed.] Gastro-intestinal disturbances, habitual constipation, and diseases of the female sexual organs favor, probably through resulting auto-intoxication, the production of acne.

A further variety, in which the subjective symptoms consist mainly of burning and itching, has been designated *acne urticata* by Kaposi.

In this chronic disease, which frequently lasts for years, inflammation recurs with more or less intensity, and the swelling and pigmented markings may frequently lead to considerable disfigurement. In addition to the whitish, flat, and sometimes depressed cicatrices we also see raised macules and elongated pustules which are still red and in various stages of evolution and involution; and alongside of these we also encounter inflamed tubercles of different sizes, making it difficult for an inexperienced observer to recognize the process as originating in the follicles.

The inflammation spreading to the sebaceous glands and extending to deeper structures, larger cutaneous abscesses frequently occur, which contain fluid and sometimes inspissated pus.

Toxic Acne Eruptions.—Just as certain substances may produce toxic erythemas upon the skin, there are also medicines and chemical substances which may bring about follicular inflammation, either at that part with which they come in direct contact, or when taken internally, in those places where they are secreted from the skin. Iodid acne can be provoked either by the ingestion of potassium iodid or sodium iodid [and from almost any iodin preparation. —Ed.]. In *iodid acne* the inflammation is usually more intense than with ordinary acne, the localization of the eruption being, however, about the same in both. Concerning the manner of the toxic action of iodin, internally administered, upon the skin we know but little. In marked cases even egg-sized tumor-like formations result, beset with pustules, and in their further course may become gangrenous (*iododerma tuberosum, acne coagminata*, Behrend).

According to Ehrmann, this tumor-like formation is an inflammatory granulation tumor, with hyper- and parakeratosis, which undergoes a rapid metamorphosis. The cause probably lies in an alteration of the vessel walls, produced by the iodism.

In *bromid acne* the follicles are more markedly infiltrated, and it is less disseminated than iodin acne; it is usually confined, moreover, to smaller areas of the skin; owing to the infiltration and inflammation becoming more extensive, the follicles may be converted into raised, irregular plaques, up to the size of the palm of the hand. The surface of these plaques seldom disintegrates; only small moist spots, situated on a more or less intensely reddened and irregular raised base, are formed (Plate 32).

The diagnosis of this last-named type of bromid acne is often very difficult, as it presents few characteristics and may readily be confounded with vegetating syphilitic ulcers, or even with epithelioma. We have observed an instructive case of this kind on the lower extremity. An uneven, slightly raised, ulcerating surface covered with granulations presented itself for consideration. The patient, an aged female, had been taking large doses of potassium bromid in secret. The supposition that we had a bromid acne before us, and not syphilis or epithelioma, was strengthened by the absence of symptoms pointing to syphilis, the presence of decided inflammatory phenomena, and also by the more rapid course than occurs in epithelioma.

Chlorin gas, *benzin*, *creasote*, and *tar* are also capable of provoking a toxic acne. Tar applied to hairy parts of the skin may block up the follicular openings and thus give rise to an *acne artificialis*.

Also in consequence of a *gonorrhea*, particularly in women, an acne-like folliculitis of the skin has been observed, which is analogous to folliculitis præputialis gonorrhoica (Jesionek).

Treatment.—Internal causes, chlorosis, disturbances of the stomach and intestines, and difficulties of menstrua-

tion are to be considered. These must receive their share of attention; and their management must go hand-in-hand with local treatment. The little pustules and abscesses are opened first; tubercles which may exist are punctured. When the small incisions and punctures have been healed by compresses or indifferent ointments and bandages the affected parts are thoroughly washed with soap and warm water. Potash soap, tincture of sapo-viridis, marble soap, sand soap, and the legion of medicated soaps can be used. This treatment suffices for many mild cases. Usually in connection with the soap-washing, which is to be repeated at least nightly, an ointment must be ordered. We mention:

℞ Sulphur. præcip.,
Potass. carbonat.,
Glycerini,
Aq. laurocerasi,
Spirit. vini gallici, *āā* 10 (ʒiiss).—M.
Ft. pasta.

℞ Sulph. lot., 10 (ʒiiss);
Balsam. peruv.,
Camphoræ, *āā* 2 (gr. xxx);
Saponis viridis, 5 (gr. lxxv);
Adipis, 30 (ʒviiss).—M.
Ft. unguentum (Eichhoff).

℞ Bismuth. subnitrat.,
Hydrarg. præcip. alb.,
Ichthyoli, *āā* 2 (gr. xxx);
Vaselini, 20 (ʒv).—M.
Ft. unguentum.

Sig.—To be applied thickly before bedtime (Hebra-Ullmann).

Schütz recommends:

℞ Sulphur. lot.,
Calcii sulphurat.,
Calcii phosphat., āā 25 (ʒvj gr. xv).—M.
Ft. pulv. subt.
Sig.—Sulphur powder.

This is mixed with a little water and allowed to remain on during the night.

Further, lotions of:

℞ Sulphur. præcip., 15 (ʒiij gr. xlv);
Camphoræ, 10 (ʒiiss);
Aq. destill., 250 (fʒviij).—M.

Or

℞ Sulphur. præcip., 10 (ʒiiss);
Spir. vini gall., 50 (fʒxiiss);
Spirit. lavand., 10 (fʒiiss);
Glycerini, 150 (fʒiv ʒvj).—M.

And other spirituous solutions and mixtures of similar composition.

We note very good results with Lassar's method of producing exfoliation:

℞ β-naphtoli, 10 (ʒiiss);
Sulphur. præcip., 40 (ʒx);
Vaselini,
Sapon. viridis, āā 25 (ʒvj gr. xv).—M.
Ft. pasta.

This paste is applied as thick as the back of a knife and is allowed to remain for fifteen minutes to one hour, when it is wiped off and an indifferent powder is dusted on. The patient applies a 10 to 20 per cent. resorcin paste, which is allowed to remain overnight. In a few days inflammation of the skin treated in this manner results, the epidermis exfoliates, and the acne is usually

much improved or cured. When improvement alone results, this procedure is to be repeated.

Unna uses the following paste to bring about exfoliation:

℞	Resorcini,	40 (ʒx);
	Zinci oxidi,	10 (ʒiiss);
	Terr. siliceæ,	2 (gr. xxx);
	Adipis benzoinat.,	28 (ʒvij).—M.
Ft. pasta.		

Favorable results or influence can also be effected by applications of steaming-hot water to the parts (up to 115° F.). This can be combined with some of the plans of treatment already described.

SYCOSIS.

Synonyms: *Acne mentagra; Folliculitis barbæ; Sycosis vulgaris.*

Sycosis is exclusively a disease of the hairy parts of the body. The ordinary and most common seats of the affection are the hairy portions of the face, as the upper lip, the cheeks, the chin. The eyebrows and eyelids, the nostrils, the axilla, the pubes, even the hairy scalp, may, in rare instances, show a similar follicular inflammation.

We have to deal with an inflammation of the follicles and perifollicular tissue. The first or primary stage of the eruption consists of papules, which change into pustules and are pierced in the center by a hair. These hairs, when pustulation is advanced and of some duration, are loose, and on removal the sheath of the hair root is seen to be yellowish, infiltrated with pus, and swollen. On pressure with the finger-nails pus can frequently be made to exude from the follicle. When the pustules are crowded together, larger inflammatory infiltrations result, which are covered with crusts and scabs. After the scabs drop off a cicatrix may remain, the follicle is obliterated; as a rule, however, in many cases of sycosis no permanent trace is left.

This affection may persist for years, and as it attacks exposed portions, as the face, it is exceedingly annoying to patients. The pustules are, furthermore, sensitive to the touch and very painful when the inflammation is extensive.

Sometimes sycosis begins on the hairy scalp, in the axilla, or on the mons veneris as a seborrhœa; this becomes of an inflammatory type (*eczema seborrhoicum*), and finally develops into a sycosis.

Sycosis was long considered as non-parasitic. Hebra, in his definition of the disease, described it as non-contagious. Especially was the fact that the depilation of the affected area did not prevent its extension cited as another evidence of its non-parasitic nature. Eczema was also looked upon as the forerunner of the disease, and as suggesting this the sycosis which developed under the nose as a result of the irritation, the discharge from a nasal catarrh was cited.

At present the contagiousness of sycosis can scarcely be called in question. The experimental investigations by Bockhardt and Garré have shown that the purulent folliculitis and perifolliculitis are due to the staphylococcus aureus and albus; in this respect and also in the manner of infection having much in common with impetigo contagiosa. The difference in the clinical symptoms is dependent upon the fact that in sycosis the infecting cocci are localized in places where the hair sits more deeply in the skin and where they are close together.

It is believed that the process develops as follows: The staphylococci find their way into the hair-follicle depression and give rise to an impetigo pustule; progressing, they get deeper into this opening and multiply in the crevice between the hair shaft and hair sheath, down to the opening of the sebaceous gland. Having permeated the tissue to this extent, there results the formation of a perifollicular abscess, which ends with complete suppuration of the hair follicle and loss of the hair.

A rare or unusual form of sycosis, but in general closely

related, is the so-called **dermatitis papillaris capillitii** (Kaposi), which is identical with the *acne-keloid* of Bazin, and the *folliculitis nuchæ sclerotisans* of Ehrmann. Tubercles and tuberculo-pustules form at the margin of the nucha and posterior scalp; these develop into papillomatous vegetations, bleed easily, and are covered with crusts, and sometimes here and there contain pockets of purulent fluid. The process advances upward from the occiput to the vertex. The hairs are gathered in tufts or are entirely absent. New formation of sclerotic connective tissue, atrophy, and baldness result. At times tufts of hair protrude from the sclerosed tissue. In most instances the disease tends to limit itself to the lower occipital region.

As to the etiology of this variety of folliculitis, Ehrmann believes that it is essentially the same as in ordinary sycosis, only the suppuration process permeates more deeply in the tissues, and in many places breaks through the cutis. The different anatomic pictures depend chiefly upon the longer form of the hair pockets and their peculiar group-like arrangement in this region.

Sycosis parasitaria (hyphogenes) belongs in the group of trichophyton (ringworm) eruptions, and will be considered under that head.

Treatment.—While formerly the treatment of sycosis was an exceedingly difficult matter, as well as frequently disappointing, we are now, thanks to the Röntgen-ray treatment, in position to favorably influence this disease, and frequently to cure it permanently. According to Leopold Freund, it only requires four to six exposures of about ten minutes' duration, at a distance of fifteen centimeters, and with a hard tube. After the disappearance of the inflammatory reaction sulphur paste is to be applied.

The former conventional treatment consisted in depilation, destruction of the follicular abscess with the microcautery, applications of disinfecting lotions, etc. [One should hesitate to employ the microcautery in this disease, when persistent depilation or shaving, together with the

persistent use of mild disinfectants (boric acid, resorcin, sulphur, salicylic acid, oleate of mercury), will quite frequently result in cure. The Röntgen-ray treatment is best reserved for obstinate cases.—Ed.]

Dermatitis papillaris capillitii also yields promptly to the Röntgen-ray treatment.

ACNE ROSACEA.

Acne rosacea is characterized by red or bluish discoloration and hypertrophy of the cutaneous structures of the nose, and occasionally extends to, or is seated upon, other parts of the face, as the forehead, cheeks, and chin. This affection appears usually in adults, more frequently in men, but also in women; in the latter exceptionally during the period of puberty, most frequently, however, during the climacteric.

Patients at first complain of a sensation of warmth in the nose upon the slightest cause, as when entering a warm room, excitement due to psychic irritation or to drinking; at which time especially the nose appears flushed, which, however, soon disappears. The nose is observed to be frequently moist or oily—seborrheic. Sooner or later the redness becomes permanent, and disappears only on mechanical pressure for a short period, to reappear as soon as this is withdrawn.

This intense redness goes hand-in-hand with slight or more or less pronounced swelling and hypertrophy of the nose. On the most pronounced and thickened skin areas the capillaries and veins are enlarged, and for the most part there is also follicular pustule formation about the follicles. In anemic individuals the redness of the affected region comes out more clearly and distinctly. Occasionally a few venous vessels become more prominent at an early date. These dilated, tortuous varicose vessels impart a bluish color to the affected parts. The hypertrophy referred to is due to proliferation of the connective tissue, which begins around the vessels and is irregularly dis-

tributed. Frequently single flat papules develop superficially; these increase in size and number, become confluent, and often form excrescences the size of a cherry to that of a nut. These lobular tumors, which are pedunculated at times, and the swelling of the nose may exceptionally increase to the size of a small fist, and the distorted organ overhangs the mouth (*rhinophyma*).

The skin of the enlarged organ is furthermore covered with dilated sebaceous follicles and scattered acne papules and pustules. At times patients also complain of burning pain, which is probably due to suppuration and formation of the acne pustules. These enlarged noses retain their soft, elastic consistence for a long time, and only rarely feel tough and thick to the touch.

In the early stages the slight swelling of the nose may cause acne rosacea to be mistaken for lupus erythematosus; careful inspection will, however, prevent such an error. Soon the vascular alteration becomes conspicuous. The shiny, intensely red surface, the absence of being sharply defined from the surrounding neighborhood, and lack of scar formation point to acne rosacea. The absence of disintegration and ulceration distinguishes acne rosacea from lupus vulgaria; the same applies to syphilis. Enlargement of the nose of higher degree in this disease, unaccompanied by excrescences, reminds us of rhinoscleroma; it differs from the latter, however, principally in being of softer consistence. [In the large majority of cases of acne rosacea met with in this country the condition consists either of diffused redness or additionally of dilated vessels and more or less numerous acne lesions. Connective-tissue hypertrophy, except to a slight degree, is not very common. —Ed.]

Popular opinion attributes the disease to drink. In most cases the abuse of alcohol must be recognized as the causative factor, sour white wine, whiskies, and brandies being regarded as especially injurious. These drinks, however, must not be looked upon as the direct cause;

the chronic catarrhal conditions of the stomach and intestines of alcoholics must be regarded as the direct essential factors. Hence catarrhal diseases of these organs occurring in non-alcoholics may likewise be of similar etiologic importance. Experience, furthermore, demonstrates that individuals who are much exposed to cold—*e. g.*, coachmen, hucksters, and sailors—are frequently affected with acne rosacea. People of this class, however, are not very careful in their diet nor in the use of alcohol, and frequently resort to the latter for its warmth-giving effect. Excessive tea-drinking is also of causative influence. Our observation, that such patients not infrequently have a pale skin and conjunctiva, appears worthy of mention.

There are other etiologic factors to be considered. We have mentioned that girls develop acne rosacea during puberty, and women more frequently during the climacteric period. Such individuals suffering from disturbances of the genital system are nearly always anemic. We therefore may regard it as probable that long-continued anemic conditions dispose to this disease, and that the anemia is the result either of digestive disturbances, due to malnutrition, or to disorders of the genitalia and loss of blood. A very hopeful prognosis, therefore, cannot be given in many instances, as the underlying causes may be either difficult of recognition or, when they depend on the method of living, cannot be removed. The affection never reaches a stage dangerous to life. In concluding the consideration of the acne forms, short reference may be made to the acne scars which appear as white atrophic or scar-like perifollicular spots on the trunk, and which, according to the investigations by Iwanow, result from a chronic process originating in the sebaceous glands.

Treatment.—The general treatment of this disease should be directed to the frequently associated symptoms of uterine disorders, abuse of alcohol, disturbances of the stomach and intestines, and constipation, which must receive proper consideration.

Local treatment, of course, is governed by the stage

and conditions. In the first stage applications of hot water for a short period, covering the diseased skin with adhesive plaster or plaster of salicylic acid soap, and mopping with sulphur lotions will be productive of good results.

The following will be found serviceable:

℞ Sulphur. præcip.,
Ammon. muriat., āā 1.2 (gr. xviij);
Spirit. camphoræ, 2.4 (gr. xxxvj);
Acet. vini., 4 (fʒj);
Aq. laurocerasi,
Aq. rosæ, āā 15 (fʒiij gr. xlv).—M.
Sig.—Shake, and apply with finger (Schütz).

Application of tincture of iodin, iodized glycerin, and gray plaster will bring about absorption of hard infiltrations.

When numerous tubercles and dilated vessels are present it is best to scarify the skin. The choice of the instrument, of which there are quite a number, may be left to the individual taste; personally we prefer the most simple instruments. Some authors (Hardaway, Lassar) employ the electrolytic needle in place of scarifications. The treatment of rhinophyma is purely surgical.

ANEMIA OF THE SKIN.

Cutaneous anemia is most usually a part or symptom of systemic anemia. It is characterized by pallor and coldness of the general integument. In consequence of the decreased quantity of blood in the capillaries the tension of the skin is also somewhat lessened, so that it lacks tone and is flabby. Efflorescences that may be upon the skin appear likewise paler. Anemic conditions due to psychic excitement, as anger, or to reflex action from the digestive tract, as occurs in malaise, colic, etc., also local anemias due to cold or to transitory occlusion of larger vessels, are

of no importance, as they are only of short duration and are not followed by further changes in the skin.

The "*dead fingers*," described by Reil, belong to the local anemias, and are characterized by a unilateral paresthesia of the end phalanges, associated with pains and muscle weakness. It is met with principally in women, and can lead to a thickening of the epidermis.

Of more importance, so far as the final result is concerned, are the local and universal anemias of the skin, already referred to, when they are long continued or exert their influence frequently at short intervals, as they lead to interference with secretion and nutrition. The skin becomes dry and the epidermis exfoliates in lamellæ. The skin becomes lax, and atrophic conditions, excoriations in places, and even deeper necrotic ulcers may result.

HYPEREMIA OF THE SKIN.

Of greater importance are the cutaneous hyperemias. They are due either to congestion of blood in an irritated area of the skin (active hyperemia) or to stasis when the return circulation is interfered with (passive hyperemia or hyperemia due to stasis).

Active hyperemias (*erythema congestivum*) are the result of engorgement of the smallest capillaries in the papillary layer. Large areas on the surface of the skin are pale red or bluish red. The various color tones of the hyperemic skin, from bright red to livid cyanotic dark blue, depend upon the degree of fulness of the vessels and the quality of the contained blood (oxygen constituent). The skin feels warmer to the touch, and the higher temperature of the hyperemic skin can be demonstrated by the thermometer. Frequently the redness appears in small circumscribed spots and disappears on slight pressure, to return as soon as pressure is withdrawn.

Sometimes patients feel a slight itching or burning. Such hyperemias, of a rapid transitory character, disappear without causing any change in the skin. When long

continued or of frequent recurrence, however, they lead to desquamation of the epidermis, accumulation of pigment, and to increased activity of the sebaceous and sudoriparous glands.

These hyperemic conditions arise from mechanical, thermic, or chemic irritants which come into direct contact with the cutaneous surface. Peripheral irritation—*e. g.*, scratching—may also be conveyed by reflex to other central nerve tracts and give rise to a hyperemic condition in remote places of the surface. Finally, psychic disturbances—*e. g.*, shame and other mental emotions—may cause direct irritation of the vasomotors from the cortex of the brain and thus produce hyperemia.

Livedo belongs to the stasis hyperemias. It is due to interference with the return circulation by the pressure of a bandage or tumor on the returning veins, to cold, or dilatation following inflammation of veins; larger or smaller areas of the skin show a bluish discoloration.

By *cutis marmorata* is understood a condition of the skin giving it a color resemblance to Salzburg marble. One finds circle-like or elliptic hyperemic outlines with lighter-colored centers. It is observed in anemic individuals and in those of alcoholic habits, as well as in those who have a naturally thin skin; and is more marked when the skin is exposed, as in undressing. Cutis marmorata has a certain resemblance to the figured macular syphilide (erythema circinatum), but is distinguished from it by the general distribution over the trunk and the extensor surfaces of the extremities, and by the absence of the deeper changes in the epidermis.

Cyanosis is a more widely distributed bluish discoloration of the skin, usually associated with dilatation of the vessels. It is due to occlusion of the larger veins, or directly to cardiac lesions or to stasis in the larger vessels. These conditions bring about the permanent changes leading to various consecutive processes, as chronic edemas, thickening of the skin, etc.

INFLAMMATORY DERMATOSES.

The step from hyperemias of the skin to inflammation is not a great one, and in the beginning scarcely perceptible. Inflammatory processes in the skin are preceded by hyperemia. When an irritant is applied to the vasomotor nerve-branches, alteration in the vascular capillaries occurs and active hyperemia results. This is the precursory stage of inflammation. When exudations and infiltrations and changes in the cellular elements have occurred—for example, proliferation of the cellular elements—inflammation becomes more decided. Although these fundamental principles of inflammation are always present at the same time, the clinical picture differs according to one or the other becoming more pronounced. Suppuration is not always present, but appears mostly only through secondary infection with pathogenic organisms.

The various forms of dermatitis, of the lowest degree of inflammation of the skin, result from mechanical, chemic, or thermic irritation, as well as also through nervous influence. According to the clinical characters we recognize erythematous, vesicular, and bullous varieties, which may lead to pustular and ulcerative forms.

ERYTHEMA.

Under this designation we group those mildly inflammatory conditions of the skin occurring in the most superficial layers and accompanied by slight or moderate exudation.

Erythema multiforme (Plate 5) is the type of this class. Vascular dilatation, active cell migration, and an edematous saturation of the papillary layers, and also moderate proliferation of the connective tissue form the substratum of the cutaneous inflammation. Proliferation of the epidermis cells in the rete and loosening or bullous elevation of the epidermis complete the picture of this inflammatory process.

Erythema multiforme most usually appears on the forearms and upper part of the arms (Plate 8), over the ankle and knee joints—in fact, over the extensor surfaces of the extremities; further, on the face, neck, nucha, and chest. Papules crop out rapidly; these spread, and in a few hours become deep-red patches. In a few days the skin is seen to be covered with macules and papules, projecting above the level of the skin; the older lesions are depressed in the center and begin to fade, but extend at the periphery with a red margin. The developed efflorescences exhibit, especially in the central portion, a bluish-red cyanotic color, resulting from the enlargement of the capillaries and the extravasation of the red corpuscles. Adjacent efflorescences coalesce and form with the successive crops the type of polymorphism. Macular lesions are found upon the backs of the hands and feet; and when the condition advances beyond this first stage of development we have an *erythema papulatum* (Plate 9). *Erythema annulare* results from a fading of the central part; by the coalescence of older spots and wheals arise *erythema gyratum* and *figuratum.*

According to the amount of exudation characterizing the process, there occur elevations of the epidermis in the form of vesicles, the size of a lentil to that of a pea, which are situated on a red base and are tense and firm—*erythema vesiculosum*, *erythema multiforme bullosum* (Plates 6 and 7).

When these erythematous spots, or the vesicles, are arranged in rings—*i. e.*, when a new ring appears around one or more of these macules or bullæ—it constitutes respectively the so-called *erythema iris* and *herpes iris.* When the older vesicles desiccate in the center and the new peripheral ring alone remains we call this form *herpes circinatus.* These two latter forms occur principally on the backs of the hands and feet; they are usually associated with erythematous patches and rarely, in fact, appear independently of these.

The whole course of erythema lasts for two to several

weeks, and frequently recurs at the same time the following year.

The duration of the efflorescences differs according to the amount of exudation; they may fade in eight to ten days, disappearing with accompanying slight desquamation of the epidermis. They may, however, remain four to six weeks; and especially when they appear in successive crops, which is usually characteristic of the disease, they may annoy the patients for several months. At times the mucous membranes of the oral cavity and genital tract participate in the disease.

In addition to these objective phenomena the process is accompanied by moderate itching, at times by a burning sensation, languor, and psychic depression. The pemphigoid bleb formation in the mouth sometimes observed can bring about severe symptoms of suffocation. In accordance with other observers we could often demonstrate troublesome gastric disturbances in our cases. At times patients complain of pains in the joints, which may develop into aggravated articular affections (*rheumatoid erythema*). Of rare occurrence are albuminuria or hemorrhages from the kidneys, and inflammatory complications of serous membranes, conditions which must be regarded as being due to a high degree of general intoxication. Usually a slight rise of temperature is noted, sometimes even high fever, which, however, does not follow any certain type.

Another type of erythema, which is distinguished from the ordinary erythema multiforme only by its external form and not by its character, is **erythema nodosum**; this is observed most commonly in children. Frequently both forms appear side by side. In erythema nodosum intensely red and usually somewhat deep-seated nodules (Plate 8) appear over the extensor surfaces of the tibia, knee and ankle joints, more rarely over the articulations of the hands and on the forearms. The nodules increase in size, several may fuse together, and the affected parts frequently show a marked increase in volume. The nodes

are very sensitive to pressure, and have a hard, elastic feel. The accompanying general disturbances are *mutatis mutandis* the same as in erythema multiforme: Nausea, feeling of weakness, fever, and articular pains. The swelling declines in one to two weeks, and the entire process is usually over in about a month. Hemorrhagic infiltrations not infrequently occur in these nodose swellings along with the serous exudation, they turn bluish (*erythema contusiforme*) (Plate 8), undergo gradual involution, and show the well-known changes of color from green to greenish yellow. Histologically, the findings indicate an inflammatory erythema extending down into the deepest layers of the cutis propria. Erythema nodosum has been considered by some as an acute infectious disease (Jarisch), but as yet this has not been demonstrated.

As to the **causes of erythema** and related processes, we are up to the present date forced to look to a few empiric facts and more or less theoretic suppositions. Experience teaches that certain kinds of fruits—*i. e.*, strawberries, raspberries; further, oysters, crabs, lobsters, seafish; especially fat, stale pork, or sausage—may give rise to digestive disturbances and to erythemas. According to our clinical observations, made years ago, it is not difficult to imagine that after a certain cause—*i. e.*, eating of damaged food—not only the substances referred to above, but also others that are formed in the organism from imperfect digestion, produce various disturbances, especially in the digestive tract, to which is added the erythema and the clinical picture completed. At my suggestion E. Freund has, for a period of two years, made investigations of those cases in which severe general symptoms and oliguria preceded the cutaneous symptoms of erythema multiforme. An investigation of the urine and feces in a large number of cases disclosed large quantities of such substances as are found in putrid decomposition of the bowel contents, such as indol, skatol, indoxyl, skatoxyl, phenol, and sulphuric ether. At the time of the expiration of the affection diamin in abundance can be found

in the stools as well as in the urine, a substance only observed in toxo-infectious processes of the general organism. These findings point very strongly, although as yet not conclusively, to the fact that in the majority of these cases the malady originates in an auto-intoxication, having its origin in the gastro-intestinal tract. Naturally this cause can only be considered as a factor in a limited number of cases of the erythemas in general.

Treatment.—As erythema multiforme can be demonstrated to be, or at least may be supposed to be, of probable intestinal origin, the diet should be correspondingly regulated; and, when indicated, laxatives and intestinal antiseptics should be resorted to. As such, we prescribe either menthol (0.2 (gr. iij) per dose in gelatin capsules, t. d.), or—

℞ Pulv. cort. cinnamomi, 0.2 (gr. iij);
Ol. menth. pip.,
Ol. eucalypti, āā (gtt. j).
Ft. capsule.
Sig.—Four to six capsules daily (Freund).

General treatment is, in other respects, according to the usual rules; rheumatic pains and articular swellings, etc., when present, are treated with local applications (ice water, plumb. acet. bas. solut., Burow's solution), and internally salol and sodium salicylate are given.

When there is tendency to itching it is well to have the affected areas painted with spirituous solutions of carbolic acid and spirituous solutions of salicylic acid, etc., about the same strength as advised in hyperidrosis (*q. v.*), followed by dusting with starch.

The same therapeutic remedies will suffice for erythema nodosum.

Erythema caloricum and **erythema solare** are the result of exposure to the combined influence of light and heat upon the skin, and consist of hyperemia with accompanying inflammation.

The **Röntgen rays** can provoke a dermatitis, which, if on hairy parts, is associated with loss of the hair. The mode of action in this form of dermatitis is not yet clear. Even a genuine atrophia cutis idiopathica can follow *x*-ray exposures (H. E. Schmidt). Holzknecht observed general febrile disturbance with exanthem in *x*-ray dermatitis, which presented a toxemic symptom-complex, but which has a favorable prognosis. Similarly to the Röntgen rays the so-called Becquerel rays (uranium salts, metallic uranium) have likewise an influence upon the skin.

With the prevalence of immunization treatment observations of *serum erythema* have increased, especially after diphtheria-serum injections, but also after the injections of antistreptococcic serum; in general, these run a favorable course. These belong to the so-called toxic erythemas, and appear either in the form of a diffused redness or with wheal-like lesions, mostly starting from the point of injection.

Toxic erythema in the narrow sense occurs as a prodromal and accompanying symptom of various infectious diseases (typhus, cholera, severe pneumonia, septicemia, acute exanthemata, etc.), and appears on the trunk, especially in the epigastrium, and the flexor surfaces of the extremities, either as roseola spots or hemorrhages in form of ecchymoses and petechiæ.

To the diffuse erythemas belongs **erythromelalgia,** concerning which, however, it is not yet positively determined whether it is a disease *sui generis* or not. It appears mostly symmetrically on the hands and feet as a diffused redness, accompanied with pain, very often with severe pain, of the affected skin. The skin feels warm to the touch. In severe cases the process can go on into an inflammatory process, and in its further development to trophic disturbances of the nails; these becoming fragile and talon-like. Often there is a prodromal stage of slight burning in the parts; later the extremities becoming very warm and painful. Whether this affection is an angio-

paralysis or an affection of the central nervous system (syphilis, Morvan's disease, etc.), being a syndrome of the latter, has not been definitely determined with the observations at hand. Frequently there is a history of malaria, syphilis, injuries, severe physical work; many of the patients have a distinct neurotic family tendency. In many cases peripheral nerve disease or affections of the central nervous system have been found.

The **treatment** is apparently powerless against this malady. Cold applications usually have a favorable influence in the attacks of pain. In some cases antipyrin, antifebrin, salicylic acid preparations, electricity (Faradization, galvanic current), have been credited with bringing about improvement. Endeavoring to ascertain the underlying cause and treating or modifying the same is under all circumstances the first duty in the management.

URTICARIA.

Urticaria is characterized by the rapid appearance of wheals, elevations which are frequently pale red, rarely white, and are surrounded by a hyperemic halo. As they disappear and reappear rapidly, and here and there become confluent, it is scarcely possible to state their size, because stable efflorescences are not found frequently. The spots seldom project more than 1 to 2 mm. above the level of the skin (*urticaria papulosa*). [This term to English and Americans usually means small, itchy, more or less transitory, scattered papules, somewhat eczematoid; or similar papules evolving out of disappearing urticarial wheals; it is met with chiefly in ill-cared-for and badly nourished children.—Ed.] Owing to paling of the center and peripheral extension of the process, urticaria presents the picture at times of a serpiginous affection. In some instances urticaria is closely allied to erythema multiforme. In urticaria as well as in the erythemas the appearance of edematous swellings, the cropping out of bullæ (*urticaria papulovesiculosa, urticaria vesicu-*

losa, *urticaria bullosa*), and participation of the mucous membranes are of not rare occurrence.

Urticaria is especially characterized by severe itching, which is exceedingly troublesome to patients, as it robs them of sleep; and if the disease is of any duration they grow weak in consequence of imperfect rest and the nervous tension. The itching leads to scratching, and this gives rise not only to localized new eruptions, but is also conveyed by reflex to remote and more extensive cutaneous surfaces.

The skin of certain persons who are predisposed to these erythematous eruptions is so very sensitive that every local irritation is followed by an eruption of wheals (*urticaria factitia*, *autographism*, *dermographismus*, *l'homme autographe* of the French). Such individuals are frequently nervous and hysteric.

From direct action of irritants (pediculi, nettle, insect bites, caterpillar hair) arises urticaria idiopathica. From disturbances in the gastro-intestinal canal urticaria symptomatica is produced, which in its most severe form is designated urticaria chronica recidivans (nettle rash). Wheals that persist days and weeks constitute that variety known as urticaria perstans (Pick).

Worthy of special note are those forms of urticaria which appear in childhood, and which, owing to their persistence and frequent recurrence, trouble the patients for many years and leave brownish pigmentations (*urticaria pigmentosa*).

While urticaria has been considered by many as an angioneurosis, according to the investigations of Török and Hari, it appears to be purely due to local irritation. Those substances accepted (ptomain, toxin, medicaments, etc.) as circulating in the blood in urticaria possess, according to Török's experiments, the property when reaching the skin of provoking a superficial irritation edema; so that it is concluded that a wheal arises from a direct action of these substances upon the blood-vessels of the corium.

Further, other diseases, as diabetes, catarrhal jaundice, dysmenorrhea, pregnancy, and puerperal diseases, favor the appearance of urticaria; also the eating of fruits and crabs, in addition to provoking erythema, can also provoke urticaria.

Allied to urticaria is *œdema cutis circumscriptum*, *angioneurotic edema*, described by Quincke and others. In this somewhat rare disease conspicuous edematous, cutaneous swellings appear, which may be the size of the palm of the hand, and which gradually merge into the normal skin. They disappear in one place, to reappear soon upon some other portion of the body. The mucous membranes of the mouth, pharynx, and larynx are also frequently implicated. Vomiting and local disturbances, due to swelling of the mucous membrane, are the most annoying concomitants of this affection. Riehl regards this morbid condition as an angioneurotic disturbance of the circulation similar to an urticaria.

Treatment.—When an urticarial eruption cannot be attributed to external irritants (epizoa), the condition of the general health, and especially of the intestinal tract and the genital system, should be given careful consideration. In some persistent and recurring cases it will be necessary to regulate carefully the diet, or, when indicated, to combine a bath-cure (Karlsbad), and in other cases to treat any existing disorder of the digestive or generative organs.

For internal treatment are recommended: Arsenic, atropin, ichthyol (0.2 (gr. iij) per dose, Lang), antipyrin, salophen (4–5 (gr. lx–gr. lxxx) per day, de Wannemaeker), calcium chlorid (0.2–0.3 (gr. iij–gr. ivss) per dose t. d., Wright), carbolic acid, yeast preparations.

Locally: Applications of the spirituous lotions already mentioned under Erythema, followed with dusting-powders.

Further, baths containing starch, alum, corrosive sublimate, washing with vinegar, etc.

PELLAGRA.

Pellagra, *mal rosso*, *mal del sole*, in its early stage appears as an erythematous malady, which during its further progress exhibits the anomalies of pigmentation. Its supposed cause (an intoxication) associates it closely with the erythemas. In some regions (as Lombardy, Venetia, Eastern Friaul, Bukowina, Roumania, etc.) pellagra occurs endemically.

Its course can be conveniently divided into three stages: the erythematous stadium with secondary pigment increase; the stage of disturbances of the digestive tract; and, finally, the stage of nervous disturbances. It appears in the spring and summer at first as an erythematous skin affection, which becomes dark brown; the eruption shows itself on those uncovered portions most exposed to the rays of the sun, as the face, the dorsal surfaces of the hands, and, in the peasants who go barefooted, on the dorsal surfaces of the feet also. Patients feel weak and suffer from a feeling of pressure in the epigastrium and frequent diarrhea. Desquamation of the epidermis occurs. The discoloration of the skin disappears in the winter, to reappear the next summer. Later the pigment turns darker and bluish red and the skin becomes sensitive. Patients complain of chilly sensations and cold. Muscular weakness, anemia, despondency, stupor, and melancholia develop. A fatal issue is brought about by aggravated diarrhea, diseases of internal organs, and delirium.

The disease is attributed to an excessive diet of maize; damaged maize especially is said to give rise to pellagra. Neusser is of the opinion that the poisonous principle is developed in diseased maize under the influence of the *bacteridium maïdis*, and that it produces the disease in field laborers who are debilitated by insolation and gastric derangements. According to this writer, pellagra is a chronic systemic disease, characterized by disturbances of delicate nerves in the domain of the sympathetic and its central nerves and arterial channels,

caused by a toxic principle forming in the intestines of individuals affected, and leading to auto-intoxication.

Treatment.—This is mainly one of diet. Nourishing food, outdoor life, and administration of iron and arsenic preparations are indicated. Strychnia in increasing dosage, combined with a bitter or gentian extract, is recommended. Of great importance are prophylactic measures, by which, if strictly carried out, the disease can be materially improved and be made to disappear.

DRUG ERUPTIONS.

In the majority of instances diseases of the skin due to the ingestion of drugs belong to the type of erythemas, but differ from these principally in being polymorphous. In common with most erythemas, they are accompanied by gastric disturbance and not infrequently by fever. It is of practical importance, however, to study these various skin manifestations separately.

All drugs do not give rise to cutaneous eruptions; and individuals differ materially in susceptibility, many, indeed, being free from such influence. Lewin's statements (*Handbook of Pharmacology*) are interesting: Among 402 drugs he found that 204—*i. e.*, 50.7 per cent.—might possess the property of irritating the skin. Such action from drugs requires a *temporary or inherent individual predisposition*. Some patients have an idiosyncrasy for certain drugs and react to the smallest doses; others can bear larger quantities and also a longer application of a drug without experiencing unpleasant consequences of any kind.

The rapid appearance of a generalized eruption from drugs in certain individuals is often surprising, which can be explained only on the basis of reflex action; for scarcely has the drug reached the digestive tract before the exanthema is noticeable on the skin.

It is somewhat different in those cases due to local application, when the skin is irritated directly by a remedy

which is taken up by the skin, not only giving rise to irritation of the area or areas to which it has been applied, but also by reflex action leads to similar eruptions on other parts. Exanthemata are due more frequently, however, than was formerly thought to be the case to absorption of materials by the blood, which are then excreted by the glands of the skin, and during their passage give rise to the cutaneous eruption.

Arsenic may provoke various types of skin affections, scarlatinoid erythema, vesicular and bullous eruption (arsenic zoster), the arsenic keratosis in form of a thickening of the horny layer of the palms and soles; and the arsenic pigmentation as a slate-gray pigmentation of the entire surface.

Mercury can in all its forms and methods of application produce irritation of the skin. The diffused erythema, folliculitis, and also eczema are important associated symptoms in mercurial intoxication after an inunction course. But also after the internal administration of mercury, after intramuscular injections or even temporary external application of the drug, as washing out a cavity with corrosive sublimate antiseptic solutions, erythema and eczema may be provoked.

Iodin gives rise in the most cases to papular eruptions; iodid acne, which is described more fully in connection with acne; further, inflammatory swellings of the nasal mucous membranes (iodid coryza), pemphigoid eruptions of the face and scalp; and rare instances to purpura-like blood-extravasations.

Antipyrin may not only provoke an outbreak of erythema on the extensor surfaces of the extremities, but also herpetic lesions on the mucous membranes of the lips and of the genitalia.

Quinin gives rise to a diffused bluish-red erythema (Kaposi). The *balsams* may provoke a universal, large macular erythema; *turpentine* may give rise to urticarial efflorescences. *Cantharidin* provokes an artificial erythema with vesicle and bleb formation (Plate 30).

HEMORRHAGIC ERYTHEMA.

Hemorrhages into the skin can be idiopathic, as in consequence of trauma, or symptomatic, as in the various general diseases and as a sign of blood-vessel weakness in the lower leg of old people (*purpura senilis*). In the following remarks only those hemorrhagic eruptions are presented which have a more distinct clinical picture.

Peliosis or **purpura rheumatica** (Plates 10 and 11) is a general disease of unknown etiology. It differs from the ordinary varieties of erythemas in involving the joints more markedly, and the efflorescences over the articulations are more numerous.

Dark-red to blue spots, the size of a lentil to that of a pea, develop at first over the joints, later on the rest of the body, more especially, however, on the limbs; the lesions are situated on a level with the skin and rarely project above it; they do not disappear on pressure, and soon assume a purple hue, or in very grave cases, owing to marked extravasation of blood, they are of a bluish-black color (*purpura rheumatica fulminans*) (Plate 12). Simultaneously with the purpura eruption there may also be erythema. In rarer cases the face may be the seat of vesicles and blebs with serous contents (*purpura papulosa et bullosa*) (Plates 13 and 14). Patients are prostrated and complain of pains in the joints. In many cases the joints are decidedly swollen, the exudation is serous, sometimes hemorrhagic. Moderate rise of temperature in the evening, languor, anorexia, and a feeling of thirst are constant concomitants. In rare instances albuminuria, hemorrhages from the kidneys, and endocarditis are grave complications.

The exciting cause of peliosis, despite the numerous investigations of late years, still remains unexplained. The hemorrhage may be preceded by hyperemia and stasis, usually of long duration. The blood escapes through the walls of the vessels by diapedesis; it is rarely possible to demonstrate capillary disease. Some observers have stated that hyaline degeneration, fatty changes in the endothe-

lium, and formation of thrombi during this process take place. This state of affairs, however, would probably be found to exist only in petechiæ occurring in the course of grave diseases (tuberculosis, Bright's disease).

It is highly probable, however, that toxins and ptomains circulating in the blood either change the latter or cause angioparalysis of the smallest branches by influencing the vasomotors. So far as the changes in the blood are concerned, it is certain that the percentage of hemoglobin is greatly diminished. Microcytes and poikilocytes are found occasionally in fresh blood; and, further, the eosinophilous cells are increased in number. Microorganisms have also been found in the blood-serum (bacillus purpuræ hæmorrhagica, Letzerich; cocci of Kolb, Reher, Babes, and others).

The older efflorescences undergo the ordinary changes of blood-coloring matter and appear greenish yellow to reddish brown. When hemorrhage into bullæ (in erythema bullosum) has taken place, they dry up into brown scabs. The process generally lasts four to six weeks, and tends in some instances to recur.

Morbus maculosus Werlhofii, or **purpura hæmorrhagica,** is a disease which is differentiated from peliosis by the number and extensive character of the hemorrhages.

In this affection irregularly generalized, scattered petechiæ and vibices appear over the entire body. The mucous membranes of the mouth and pharynx participate more frequently in this process than is observed in purpura rheumatica. Sharply circumscribed pea-sized papules often appear in the mouth; and similar papules can also be present upon the trunk (*purpura papulosa*). Edematous swellings accompanied by hemorrhages occur, and when they involve the larynx they may cause dangerous symptoms of suffocation. Still graver complications are the occurrence of hematuria and endocarditis and pericarditis, conditions which go to confirm more fully still the intoxication of the entire organism.

The treatment of purpura is purely symptomatic. In cases of joint involvement salicylic-acid preparations are given; in hemorrhages from the internal organs, ergot, lead acetate, etc. According to later observations gelatin injections and the administration of adrenalin have sometimes proved useful.

In order to complete the subject of hemorrhages in the skin we will briefly refer to **scorbutus** (scurvy), which differs from morbus maculosus only in degree, and is characterized, along with the phenomena peculiar to that disease, by involving the gums and the mucous membranes of the oral cavity at an early date. The gums are of a dirty-gray color, very loose, and undermined in places by hemorrhages. Frequently there arises a purulent gangrenous stomatitis.

Owing to necrosis of the mucous membrane of the mouth there is very pronounced fœtor ex ore. The blood-vessels of scorbutic patients show a high degree of weakness; slight pressure with the finger-nail suffices sometimes to provoke or produce a subepidermoid hemorrhage (*purpura factitia*). The hemorrhages on the trunk and extremities, the soft parts being permeated by larger extravasations of blood and forced apart, are of graver importance. Larger hematomata, those found in the subcutaneous tissue and between the muscles, can break down and suppurate and lead to exhausting inflammatory processes.

Scurvy and morbus maculosus Werlhofii, as experience teaches, especially the former, result from malnutrition in general and lack of fresh meat and vegetables, and occur most frequently in convicts and seafaring men.

In the treatment of scurvy a strengthening diet and the administration of tonics are required. Acids are believed to favorably influence the condition. In this malady, also, it might be of advantage to try gelatin injections and the administration of adrenalin. The mouth is washed out frequently with antiseptic and astringent lotions.

We would mention finally that *bleeders' disease* (*hemophilia*) is a permanent inherited tendency to hemorrhages, and is often found to exist in fat, well-nourished individuals, whereas the affections discussed above are acquired diseases accompanied by disturbances of nutrition.

DERMATITIS.

In the section on erythema it was stated that the essential element of inflammation of the skin is hyperemia; and in the beginning is, in fact, the only one. We have also referred to the superficial inflammations of the skin which are called forth by irritating substances (toxins, medicaments), showing the close relationship of, and the very slight differences between, hyperemia and inflammation. In the following brief summary we shall refer to inflammations of higher degree. These are caused either by pathologic processes in the organism or are the results of direct thermic, chemic, or mechanical injuries, to which the skin is often subject. As to the inflammations due to traumatic injuries, we consider such as belonging properly to the province of surgery.

Experience has taught that **diabetics** are predisposed to various kinds of cutaneous inflammation. Such individuals may suffer from anidrosis, asteatosis, pruritus cutaneus, sometimes erythemas, eczema, furunculosis, anthrax, and even diffuse dermatitis. Such dermatitides on the extremities occur as a result of slight pressure or slight injuries. It may easily happen, therefore, in such instances that the subcutaneous tissue of the soles of the feet, toes, ball of the foot, and dorsum of the foot become the seat of inflammation, which may lead to gangrene and bone necrosis. Kaposi has described a **gangræna diabetica bullosa serpiginosa,** which occurs mostly on the side of the toe, but may also occur on the dorsum of the foot or on the sole. It presents a livid color and the formation of blebs with discolored contents, and may lead to deep inflammation of the cellular

tissue and bone necrosis; septic symptoms may develop, with lymphangitis and periphlebitis, and the malady finally may end fatally.

The pathogenesis of these conditions is not entirely clear. Kaposi holds the view that the sugar deposited in the tissue ferments, and thus gives rise to the inflammation. We might also call attention to the lessened resisting power of the organism as a factor in such patients; especially as it is known that diabetics are not equal to much fatigue or to continued mental effort—in fact, their power of resistance and recuperation is much compromised. Diabetics are, further, sensitive to temperature influences and intolerant of alcohol. Experienced surgeons are well aware of this fact, and, if possible, avoid operations of gravity in such people.

Inflammations and even tissue necrosis are encountered in enfeebled individuals after acute diseases, such as variola, typhoid, etc. In spite of the greatest care in some cases, one is not able to prevent the formation of bedsores.

In this same class, too, belong marasmic subjects and old men, in whom the circulation is weak (*senile* or *marasmic gangrene*); finally, cases in which there is contraction or closure of the arteries, as in atheroma of the vessels; in endarteritis obliterans, as sometimes observed in the distal arteries after syphilis, which leads to inflammation of the peripheral parts of the extremities and to progressive gangrene.

The **multiple cachectic gangrene** of the skin (**ecthyma gangrænosum** of Kreibich) is observed almost exclusively in *cachectic children* one to two years old. It appears as a redness and papules, out of which pustules and ulcers develop. The ulcers have sharply cut borders and a punched-out appearance, and are mostly to be found in the gluteal region, on the thigh and neck—seldom on other parts. It is to be distinguished from syphilis by the absence of other symptoms of that disease, the predilection localities, and the profuse pus formation.

Kreibich and Hitschmann consider the bacillus pyocyaneus as the cause of the malady, a view that needs confirmation. It is probable that the fecal and urinary discharges have some influence in its production.

By **neurotic gangrene** one understands that inflammation of the skin, followed by loss of substance, which is due to some nerve disturbance; the pathogenesis is, however, in most instances still obscure. Bedsores have been considered as of trophoneurotic origin (Charcot). To the neurotic group of gangrene stands in first importance that known as **Raynaud's disease** or **symmetric gangrene** (Plates 28 and 29), which is observed chiefly in nervous and anemic women, and which has the prodromal symptoms of pain and local anemia of the extremities. In marked cases the pain increases, the affected parts of the skin become bluish to blackish and are anesthetic. These attacks can often recur and, without leaving any permanent damage, disappear. Frequently, however, in a short time a dry gangrene sets in, and two symmetric phalanges of the finger or toes will finally be cast off. During the attacks two stages of action can be demonstrated in the blood-vessels; contraction and local syncope (whereby the skin becomes white and cool), and dilatation, local asphyxia, with dark-blue cyanotic discoloration.

Paresthesias and anesthesias are observed in cases of symmetric gangrene preceded by markedly severe nervous disturbances.

The question whether Raynaud's disease is a disease *sui generis* is not yet decided. By some it is looked upon as a pure vasomotor disturbance without primary disease of the vessel, dependent upon an affection of the central nervous system (Hochenegg, Nonne). Quite frequently it has been observed simultaneously with hemoglobinuria, and this latter symptom is of possible etiologic significance. In numerous cases diseases of the vessels and affections of the brain and spinal cord (tabes, syringomyelia, tumors of the spinal cord, etc.) have been noted.

Syringomyelia is also often associated or followed by

trophic disturbances of the skin; it is, however, to be distinguished from Raynaud's disease by the asymmetric appearance of the ulcerations, as well as by the appearance of various other eruptions in consequence of the dystrophy, as eczema, rhagades, panaritis, bleb formation, gangrene, etc.

Multiple neurotic gangrene of the skin, or *hysteric gangrene*, is related to herpes zoster gangrænosus. With a feeling of burning, frequently also with intense neuralgia, appear atypic macules or urticaria-like efflorescences, which rapidly become darker in color and gangrenous. In most cases fever is present and the general condition disturbed; the affected parts become anesthetic. After the gangrenous tissue is cast off, cicatrization takes place. In consequence of the appearance of numerous fresh outbreaks of new blebs (which likewise undergo necrosis) the malady is long-continued, but almost invariably comes to an end. It is to be remarked that it is not possible in all of the cases of so-called hysteric gangrene to prove the hysteric or even nervous origin of the disease. We are, in fact, as yet considerably in the dark regarding the etiology.

Perforating ulcer of the foot has been considered by some authors likewise as a trophoneurosis. It appears most frequently on the flexor side of the large toe and over the ball of the foot. Mostly a callous condition of the epidermis or a corn-formation precedes it. This accumulation is thrown off by underlying inflammation, and leaves an ulcer, which extends deeply and may even lead to necrosis of the bone.

The original ulcer rarely heals, but usually the process, in spite of any operative treatment, advances steadily. As mentioned, the malady has been considered as a trophoneurosis, and also as due to an endarteritis. Lately Tomaszewski has expressed the opinion that the substantial cause lies in the local conditions; through pressure upon exposed parts of the sole a thickening of the horny layer ensues, which, by relative loss of sensi-

tiveness in the affected part, may through accidental causes lead to an inflammatory process.

GANGRENOUS GENITAL ULCERS.

The phagedenic or gangrenous ulcers of the genital region constitute a disease *sui generis*, and are to be clearly divided from spontaneous gangrene, from septic gangrene, and from other forms. They appear suddenly in the genital region, in the form of isolated ulcers with accompanying fever. The ulcers are covered with a dirty-gray coating and surrounded by a narrow bright-red halo. They give forth a foul odor like spoiled meat, and are spontaneously, and also by touch, extremely painful, so that the patient avoids anxiously every possible motion. After the pulpy coating of the ulcer is cast off—which is toward the border sharply demarcated—the floor is noted to be a clean, granulating wound surface; the process, which runs a violent course, exhibits a great tendency to heal. In its rapid course, however, in a short time deeply lying parts can be destroyed, and after the falling off of the slough a deep funnel-shaped depression is seen. They can, for example, on the genitalia destroy large parts of the skin and mucous membrane; in consequence of a wide loss in the preputium the glans may come through such side-opening; the glands and spongy bodies, by great substance-loss, become much smaller; and when on the scrotum the process may extend so deeply as to destroy the testicle. The gangrenous genital ulcer appears sometimes at the termination of, or along with, a venereal ulcer, and the diagnosis of the latter be rendered difficult, inasmuch as the gangrenous process may in a short time involve and completely destroy the venereal sore. When a sclerosis is involved in the gangrenous process the inguinal-gland swelling is not developed, as was observed after excision of the chancre. We have observed such cases, in which a sclerosis, which eventually was producing a paraphi-

mosis, was involved in the gangrenous ulcer and brought to a rapid disappearance, similar to the rapid healing of the initial lesion by an intercurrent infectious disease.

In the histologic investigation of the gangrenous skin is found an inflammatory process, which leads to a rapid coagulation necrosis of the tissue. In the slough several bacteria were found, and considered the cause of the malady; culture experiments were not successful. According to the views of several authors (v. Herff, Matzenauer, and others) these gangrenous ulcers are an infectious disease and identical with hospital gangrene. Other authors defend the old view that gangrene of the genitalia is the result of mechanical causes, circulatory disturbance, through pressure and counter-pressure, by which the involved parts undergo necrosis. By this view one can understand the rapid demarcation of the process. The bacteria found in the sloughs are considered by these as purely secondary and accidental, as, for example, derived from the preputial sac in an existent balanitis. According to this view the malady would not be contagious, and for this reason auto-inoculation is also negative.

NOMA.

Noma is mostly observed in children on the face, but also in the genital region; it is characterized by similarly rapid tissue destruction as in genital gangrene and leaves behind considerable loss of substance. As soon as the slough becomes demarcated the temperature declines and the local pain disappears entirely. Repeatedly a number of cases have been met with in hospitals, giving rise to an extremely foul odor. The malady in the majority of cases appears at the end of a grave systemic disease (typhus, scarlet fever, syphilis), which seem to leave a predisposition to it.

Matzenauer found in his noma cases bacteria analogous to those in genital ulcers; and identifies the malady with hospital gangrene. Other authors consider it due to

disturbances of the circulation, to the marasmus following the diseases named, or to a trophoneurosis. Ranke, in a later publication, expressed the opinion that it is a mycosis, inasmuch as he found constantly in the diseased tissue streptothrix.

The gangrenous genital ulcers as well as noma belong to the rarest maladies, in contradistinction to hospital gangrene, which before the days of antiseptics occurred in extensive epidemics in field hospitals.

COMBUSTIO (BURNS).

Under the term "combustio" are designated those cutaneous inflammations due to the action of heat or caustic chemic substances upon the skin. The tissues react after such injury in different degrees of inflammation, provided vitality has not been completely compromised or destroyed. On account of the frequency of this accident the skin inflammations in this group are of first importance. The most common cases in which burns are observed are from heated bodies or hot liquids, as hot pitch, hot water, petroleum, explosive materials; and of the chemic materials, mostly lime, caustic acids, etc. The surface of the body is always the seat of the first symptoms, although almost immediately thereafter also disturbances of a constitutional character present themselves. According to the effects produced, it is customary to divide burns into the first, second, and third degrees. The various grades of burns are dependent upon the degree of heat and the duration of exposure to its action. Mostly the first two grades, or all three grades, of burns are observed in the same case (Plate 31).

1. *Burns of the First Degree.*—In this grade (*combustio erythematosa*) a small or large surface of the skin reddens with slight swelling, as observed in erythema, but diffused and not in wheal or papular form. This slight inflammatory condition of the skin is followed in a few days by a brownish coloration; it then gradually returns, with slight

exfoliation, to the normal state. Generally, with this degree of combustio the general equilibrium is not disturbed, except in those instances in which a large surface is involved.

2. *Burns of the Second Degree* (*Combustio Bullosa*).—The surface involved is the seat of vesicles and blebs from pea- to fist-size, tolerably well filled with serous fluid. The epidermis is not equally lifted up, as it is, for example, in pemphigus blebs; and the covering is mostly thicker, the base of the blisters being the rete Malpighii or even the papillary layer. The surrounding skin is dark red and shining. The patient experiences a feeling of burning or heat in the part, which often extends beyond the immediate boundary of the burn itself. The smaller blisters remain unbroken, their contents becoming milky; the epidermis dries to dark crusts, which drop off and disclose the newly formed epidermis. The larger blisters are torn upon removal of the burnt clothing or from pressure or contact in lying in bed, so that when first observed by the physician they are seen as irregular folds of epiderm or bared red areas. These are covered with whitish spots or specks, and in a few days become quite red, and are followed by an exudation and a cell formation which gradually lead to complete over-skinning.

The subjective symptoms in these cases consist of marked pain and burning, which are heightened by the pressure in bed and by the removal of dressings or clothing. If a large part of the surface is involved, the life of the patient is endangered.

3. *Burns of the Third Degree* (*Combustio Escharotica*).—In these cases, in addition to the symptoms of the other grades, there is observed, as especially characteristic, a condition of mortification of the tissues, resulting from the intense action of the heat. The soft parts present, at least as to extent and depth of the burns, in every case all possible degrees. Most frequently the part, both skin and tissue, appears as if it had been cooked with steam or hot water. Very seldom are to be seen on the burned areas

bullous elevations; but for the most part the skin is observed hanging in shreds. In other cases the affected regions present a mortification, in which the skin is whitish, alabaster-like, hard and tough to the touch, and lifeless in appearance. Worse still are those cases in which the skin and soft parts are converted into a dry, leathery, and hard dark-brown slough. The sloughs are irregular in area, and on the periphery symptoms of burns of the milder degrees are observed. In those unfortunate cases in which the body is exposed to direct flame the condition is one of carbonization and distortion. Many authors designate this stadium as burns of the fourth degree. The patients are in the highest degree of agitation, and in this severe grade of burn succumb often in four to six hours (nerve shock (Kaposi)).

More frequently, after a period of excitement there follow an apathetic condition, yawns, sighs, and gradually singultus, and even vomiting of gall. Especially the last symptom, vomiting, is of ominous import as to the outcome; these cases end, almost without exception, fatally (according to Kaposi, out of 3000 such patients only 1 recovered). The patients grow restless, bewildered, are attacked with cramps and opisthotonos, lose consciousness, become delirious, and fall into a stupor. In these cases the bladder is found to contain but a small quantity of urine. The breathing becomes superficial, the pulse weak, and a fatal result soon ensues. If the patient survives the first two or three days there begins a sharply defined inflammation with suppuration. The slough contracts, and in the course of one to three weeks is cast off by the suppurative action. On the less-involved areas granulation begins. This period is for the patient also a dangerous one, inasmuch as he may suddenly die from heart failure. According to Kreibich, in extensive slough formation there is secondary infection with pus-producing organisms. An examination of the blood discloses a clearly marked leukocytosis. The urine frequently contains albumin. Quite often autopsies disclose intestinal ulcers and peritonitis due to perforation.

Irrespective of these direct dangers from the actual burn there are other risks to the life of the patient later, due to intercurrent disease, as pneumonia, Bright's disease, erysipelas, and pyemia.

The scars following burns are often keloidal, hypertrophic, and cause in later years more or less difficulty; the blood-circulation may be compromised, as a result of which the peripheral part becomes enlarged by edema and elephantiasis. Very often the movements of the head are hindered by scars on the neck. Contraction of scars on the extremities impairs the usefulness of the limbs, and the arms are not infrequently drawn into fixed angles or drawn to the trunk.

Histologic examination shows the blebs to be many chambered and having fine, thin, elongated rete cells running through them. The rete cells are changed into a homogeneous mass. In the bleb contents are found fibrin coagula, and on the bleb floor collections of leukocytes (Spiegler).

The cause of death in burns has been attributed to various factors. It is first of all clear that the suspension of skin respiration, even of great extensive areas, as well as the great loss of albumin in consequence of the serous exudation, will not suffice to explain the symptom-complex so resembling systemic intoxication or poisoning. Many authors consider death to be due to a breaking down of the red blood-corpuscles, others to the formation of toxic substances in the organism, derived from the division products of the albumin.

The opinion of Kaposi that death, especially in the rapidly fatal cases, is due to nerve shock is shared by many others. Yet this explanation scarcely suffices for all such cases. Weidenfeld, from a clinical and experimental study, came to the conclusion that the cause of death is somewhat variable, partly to nerve shock and the decomposition in the blood, as well as the loss of albumin; and also in some cases, or partly, to an intoxication of the organism with the products produced by the burn. The

most important and the most frequent cause of death is the absorption of toxic substances, which come principally from the products of the burns themselves.

The **prognosis,** as already hinted, depends upon the extent and intensity of the burns. Single deep burns have but little influence upon the general condition, while lighter first and second grade burns can lead rapidly to death when they include two-thirds, many times even one-third, of the entire surface. According to Weidenfeld, if burns of the third degree include one-eighth to one-sixth of the surface, death is quite frequent. Experience shows that with children burns are of much greater gravity than with adults.

Treatment.—In burns of the first degree: Dusting the parts with an indifferent dusting-powder, or ice-water applications frequently changed, or aluminum acetate.

In burns of the second degree: Opening the blisters and applying mild salves spread upon bandages. The bared rete or corium is dusted with iodoform in a thin layer, and over this a bandage of boric acid salve or dressings of equals parts of oil and lime water. Von Bardeleben recommends for the burnt areas solutions of carbolic acid (3 per cent.) or salicylic acid (3 per cent.), and then to be enveloped with soft gauze bandages which have been previously covered with equal parts of bismuth and starch. Such a dressing may remain several days.

Sattler, likewise, extols the dry treatment of burns, in which he employs xeroform powder; he states that with this treatment the pain instantly disappears.

In extensive cases the continuous bath, according to Hebra, is especially serviceable. Internally alcohol is to be given; and if there is great restlessness with loss of sleep, morphin, chloral hydrate, and the bromids.

Lustgarten recommends atropin, and lately Tommasoli the subcutaneous injection of artificial serum (that made of salt and sodium bicarbonate).

The management of burns of the third degree is to be according to the same general plan. Weidenfeld, on the

basis of experimental observation referred to, tried in burns of the third degree the removal of the slough. Certain it is that in such a manner the mass of the toxic absorption products can be much lessened. It is understood that such a measure must be carried out with attention to the strictest antiseptic precautions.

CONGELATIO (FROST BITE).

Frost bite arises after more or less prolonged exposure to low temperature. The time necessary for such action differs materially with different persons. Anemic individuals or those weakened by wading through snow suffer more severely than robust, healthy people. The appearances upon the skin are, as in burns, divided into the three grades—erythematous, bullous, and escharotic.

Frost bite is most common in such parts as the uncovered hands, the poorly clad feet, the nose, ears, and cheeks. The patient experiences slight burning; soon loses, however, this feeling, and is only subsequently made aware that he has been frost bitten by the thawing out, which is accompanied by sticking pain and intense itching. In this manner arises dermatitis erythematosa, so-called frost bite, or *perniones*, or *chilblain*, appearing as variously sized, slightly raised spots of livid color. The blood-vessels become paretic, to which are due the bluish color, the serous infiltration, and the slight swelling. If these inflammatory appearances are followed by greater infiltration and exudation, the epidermis will be lifted into vesicles or blebs, the contents of which may be more or less hemorrhagic. Sometimes these give place to torpid ulcerations, which from their exposed situation heal slowly, and may be troublesome through such complications as lymphangitis and adenitis.

As already mentioned, anemic individuals are especially exposed to this affection, especially the hands and ears; and in even moderate cold, after having once suffered from frost bite, with its consequent blood-vessel changes,

may readily be attacked again. Frequently recurrences present at certain times of the year.

In extreme cases of frost bite (*congelatio escharotica*) there always arise hemorrhagic blebs or a bluish, marbleized, cold-feeling, and insensitive surface. One cannot at first sight gauge the extent and the consequences in such cases, inasmuch as experience teaches that the soft parts, which may present the appearance of having been frozen, may yet recover, since the blood-vessels may remain permeable. In its further course a reactive inflammation occurs around the mortified areas; or after exposure to intense cold the mortification may not only extend through the soft parts, but even involve the bone.

Necrosis—casting off of the ear lobes, or phalanges or entire fingers—is not infrequent. In these long-continued cases there is always the possible danger of absorption of putrid material, with consequent phlebitis and septicemia and death.

According to Hodara, histologic examination of the frozen parts of the skin shows collections of leukocytes and thrombi in the vessels. In the cutis the connective-tissue fibers in many places are pressed apart by fibrin; and edema and marked dilatation of the vessels are also observed.

Treatment.—As already stated, anemic individuals are the frequent subjects of these accidents, especially of the first grade, on ears, nose, hands, or feet; it is therefore evident that in such cases the internal administration of iron preparations is to be advised. Locally, painting with tincture of iodin, collodion, or the use of—

℞ Acidi tannici, 2 (gr. xxx);
Glycerini seu,
Spiritus camphoræ, q. s. ad 50 (f℥iss).—M.

Sig.—To be rubbed in.

℞ Camphoræ tritæ, 3 (gr. xlv);
Lanolini,
Vaselini, āā 15 (ʒss);
Acidi hydrochlorici pur., 2 (gr. xxx).—M.
Ft. unguentum (Carrié).

℞ Bals. peruviani, 5 (gr. lxxv);
Misturæ oleoso-balsamicæ,
Aquæ colonienisis, āā 30 (ʒj).—M.
Sig.—For external use (Rust).

℞ Calcis chlorat., 1 (gr. xv);
Unguent. paraffini, 9 (ʒij gr. xv).—M.
Ft. unguentum.
Sig.—Rub in a pea- to bean-sized piece five minutes and bandage (Binz).

The so-named Russian chilblain salve is:

℞ Acid. hydrochlor., 30 (ʒj);
Camphoræ, 10 (ʒiiss);
Medull. oss., 40 (ʒxj);
Extract opii, 2.5 (gr. xl);
Terebinth. laric., 20 (ʒv);
Ungt. altheæ, 120 (ʒiv).—M.

Besnier and Brocq recommend bathing with a solution of walnut leaves and painting on

℞ Aquæ rosæ,
Acidi tannici, āā 0.5–1 (gr. viss–xv);
Glycerini, 30 (ʒj).

Then dust with salicylated bismuth powder (1 : 6).

In acute cases it is advisable first to place the person in a cool room, and to rub the parts with snow and administer the usual analeptica.

ERYSIPELAS.

Erysipelas is a disease due to infection, and is always accompanied by systemic disturbance. The eruptive phenomena may be found upon any part of the body. The affected area is swollen, tense, and smooth, and fiery red. The disease not infrequently continues to spread peripherally, and in some cases it cannot be determined beforehand how far the process will extend. The affected parts are tender to touch, and, especially on the peripheral zone, painful.

The disease does not invariably spread regularly from all sides, but sometimes shoots out in lines; or a neighboring part may be spared and it appear some distance from the original affection. Not infrequently it spreads along the lymphatics over the entire extent of the limb. A peculiarity is noticed in some cases, in that the disease heals at the place of first appearance and then spreads to the adjoining surface, extending in this way peripherally for some time and possibly involving a considerable surface (*erysipelas migrans*). Sometimes the parts already healed again become affected. In severe cases vesicle and bleb formation is a noticeable feature (*erysipelas bullosum*). In extreme cases the parts may even become gangrenous.

The most frequent site for the disease is unquestionably the face. It often begins at the nasal apertures, in consequence of some exfoliation or fissure; or from the corner of the eye, or from some other point where there has been an injury or break in the continuity of the epidermis through which the infection gains a foothold, and then spreads out over the face, ears, and the hairy scalp, sometimes extending down the neck and possibly to the trunk.

Even before the redness appears there may be more or less fever and a feeling of being unwell; the temperature rises to 104° F. (40° C.) with every exacerbation. In cases involving the entire head the patient is soporific or often

violently delirious; in those who drink freely—alcoholics—the disease is almost always accompanied with delirium tremens.

Experience teaches that recurrences are not uncommon, due either to the fact that some of the cocci remain in the tissues or that the disease arises from a new infection. Such recurrences frequently leave behind thickening of the connective tissues and elephantiasic enlargement; as, for example, on the lower extremities when in association with foot and leg ulcers. Falling out of the hair is a frequent consequence of erysipelas of the head.

Erysipelas heals with a lamella-like exfoliation of the epidermis or with the gradual dropping off of the crusts—the latter resulting from the dried-up blebs and vesicles.

It is worthy of note that the exanthemata, as syphilis, psoriasis, and lupus, often disappear during the course of the fever in this disease, and even new growths (carcinoma, sarcoma) can undergo a temporary retrogressive metamorphosis (*erysipelas salutaire* of the French).

The streptococcus erysipelatis (Fehleisen) is admittedly the cause of this disease. Inoculations of pure cultures of this micro-organism have succeeded in producing true erysipelas.

The **prognosis** depends upon the constitution of the individual, upon the severity of the attack, and especially upon the duration of the disease.

With erysipelas the so-called pseudoerysipelas (*phlegmon*) may be confounded. This phlegmonous inflammation usually has its origin at the seat of an injury, which either by immediate infection or subsequently is inoculated by septic material. Accompanied by chilliness and fever it may spread over an entire extremity—a thick, hard, painful, tense, and red swelling. Very seldom is there any tendency to retrogression; but usually pus formation in the subcutaneous tissues takes place. Sometimes the process results in extensive purulent melting away of the tissue. The purulent action involves the fascia and

muscles, often down to the bone. On opening a pus collection great masses of bad-smelling pus mixed with tissue débris are poured out. The patient, on account of the general infection and the severity of the local process, becomes emaciated and weak; and if he does not die in the acute stage of pyemia, he is endangered by the long-continued cachexia.

Treatment.—This consists of regulation of the diet, antipyretics, and alcohol. In investigating the source of inoculation, as, for instance, in facial erysipelas, inspection of the mouth and nose should be made, when it will often be found that the starting-point has been an abrasion from rhinitis or from a tooth abscess.

Local poultices of aluminum acetate or lead water, painting of the bordering healthy skin with iodin tincture, collodion, or ichthyol-collodium (10 per cent.), etc. We employ preferably the following salve applied on bandages:

℞ Iodoformi, 5 (gr. lxxv);
Creolini, 15 (ʒss);
Lanolini,
Vaselini, āā 30 (ʒj).—M.
Ft. unguentum.

Of the many other remedial applications recommended may be mentioned absolute alcohol applied on compresses of lint, and which are wetted every fifteen or twenty minutes, over which are placed a dry cloth and gutta-percha tissue paper (von Lausdorf); painting with guaiacol and olive oil, equal parts (Maragliano); oil-of-turpentine treatment after Luecke, in which rectified oil of turpentine is rubbed four or five times daily into the affected parts with a brush or a piece of lint.

The treatment of variola in a "red" room, with the exclusion of the chemic rays, inaugurated by Finsen, is said also to be of service in erysipelas, the process being milder and the duration shortened (Schouli, Festner, Schüler, and Kruckenberg).

FURUNCULUS.

Furuncle is an acute inflammatory process of the skin, which may arise on any part of the same, as well as also in the subcutaneous tissue; a rounded inflammatory swelling arises, which in the further course becomes gangrenous at the apex and forms a necrotic core, which is cast off.

Furuncle is frequently observed to have its origin in an acne pustule, or at least in an inflamed follicle. In the beginning there is noticed a painful inflammatory nodule in the skin. The apex gradually shows pustulation, in which sometimes a hair is found sticking. This pustule dries to a crust; after three or four days the purulent infiltrated plug may be pressed out; or this may be facilitated after the part has been linearly incised, the opening being thus enlarged.

After the core has been cast off the subjective symptoms of pain and tension disappear rapidly. The cavity thus made is gradually healed by granulation. For the most part those regions of the skin where the sebaceous and sweat glands are most numerous are the favorite sites for boils, as the nape of the neck, anal region, etc. Furuncle may also appear idiopathically in association with an infectious disease. In face furuncle, phlebitis and thrombosis, with secondary fatal meningitis, may result. Seldom is a single furuncle seen in a given case, but mostly several appear simultaneously or in rapid succession, one after another, generally through auto-inoculation (from scratching, clothing, etc.) (Plate 34). This multiform and consecutive appearance of furuncles is generally designated as *furunculosis;* this is seen quite often in badly nourished infants, and also during the period of puberty, and preponderantly in males.

Histologically a furuncle shows an infiltration extending into the subcutaneous tissue, as well as well-marked edema of all the layers, collections of lymphocytes between the connective-tissue septa of the cutis, and in the central part purulent softening and necrosis. In the contents

staphylococci, and many times streptococci also, can be found. Furuncles result from the entrance into the skin of staphylococci, and for the most part through the duct of the sebaceous gland.

Treatment.—For softening the painful infiltration several measures are resorted to: salicylated soap plaster, mercurial plaster, and hot cataplasms. As soon as softening has taken place the formation can be incised, and the wound treated according to surgical principles. In small furuncles the Pacquelin cautery has been commended, a plan which at the least seems to stop the pain instantly (Arning). In extensive cases of furunculosis which are not due to external causes (uncleanliness), the first object is to give consideration to the gastro-intestinal tract, the regulation of the diet, and the administration of intestinal antiseptics (menthol, sulphur, calomel). Very good results have been recorded in such cases from yeast preparations.

An examination of the urine, in general or recurrent furunculosis, should not be omitted; if sugar is found, the treatment must be directed against the diabetes.

CARBUNCULUS.

The carbuncle appears, in contrast with furuncle, in advanced years, and is to be distinguished from the latter by its size, by the amount of inflammatory infiltration, the marked painfulness, and the cribriform perforation of the skin. It occurs most frequently at the nape of the neck, on the back, in the buttock region, and in the face. It is a nut- to fist-sized, hard, painful connective-tissue inflammation, by which the skin over considerable surface shows a board-like infiltration. Under high fever the pus breaks through the skin at several points. With added pyemia death could take place in a few days. A carbuncle, either as a rapid or slow formation, is always to be viewed as of possible grave and fatal import. Furuncle and carbuncle are etiologically related, since both

are due to the entrance of pus cocci into the follicles, so that probably carbuncle might be looked upon as a rarer and more severe form of furuncle (furunculus compositus).

The **treatment** is purely surgical (star-like incisions through the infiltration down to the fascia, or extirpation of the carbuncle according to Riedel).

PUSTULA MALIGNA.

This is a disease of the cutaneous structure due to infection by the bacillus anthracis of splenic fever, which, as known, occurs in animals, as horses, sheep, horned cattle, etc.

Inoculation occurs either directly to men who may be employed among animals, such as coachmen, hostlers, and shepherds; or among those who have to do with the products from animals, as it is known that even hair and skins may convey the bacilli, especially the spores, which have an extremely tenacious vitality. The infection may take place through insect bites or by direct inoculation; less frequently through inspiring dust containing spores, or through the digestive tract from eating diseased flesh. It can also be accidentally acquired in an animal section (autopsy, Hermann). In the latter instance, after a section on a cow—dead from the disease—the inoculation took place apparently at the site of a bite on the arm, about thirty-five pustules appearing; two days later the patient succumbed to the disease.

The course of such an infection is always dangerous, although it sometimes happens that the pustules, accompanied by mild systemic disturbance, finally heal, the infiltrated tissue being cast off. The surgical removal of the lesion, and also the neighboring swollen glands, when sufficiently early done, will usually check the malady.

EQUINIA.

Equinia, or glanders, arises most frequently through direct inoculation from affected horses or mules. The

cause of the disease is a specific microörganism. It is known that remaining in an infected stall or handling affected animals exposes to possible infection. Probably the upper air passages are the ports of entry. Nodules appear in the skin and subcutaneous tissue with suppuration and necrosis, as well as inflammation of the lymphatic glands.

The course of the disease is rapid, and frequently, in consequence of the chills, fever, pain, edema, suppuration of the joints, phlegmon, and gangrene, the individual's life becomes endangered.

Some cases may persist for years. In such instances, even when many nodes are present in the subcutaneous tissue with subsequent breaking down of the lymphatic glands, recovery may finally take place.

The **treatment** of the primary lesions on the skin and mucous membrane is surgical and consists of the complete destruction or extirpation of the infected parts. In general infection an injection of mallein is indicated, although its action, it is true, is uncertain. Cure has resulted in some cases from a mercurial inunction course, and in others by the systematic administration of iodid and arsenic preparations.

EXFOLIATIVE ERYTHRODERMIAS.

The common characteristics of the group of diseases described under this head consist in a persistent diffused redness and scaling without any other substantial changes in the skin. The dermatoses **dermatitis exfoliativa** and **pityriasis rubra** do not admit of well-defined division, the only practical difference being that the dermatitis exfoliativa represents the more intensive grade of the exfoliative erythrodermias. Besnier divides the erythrodermias, according to their course and termination, into acute and chronic.

Under the acute and subacute forms belong **erythema scarlatiniforme recidivans** (*dermatitis exfoliativa*

acuta), in which with accompanying febrile action a scarlatinous general redness with secondary lamellar exfoliation of the epidermis develops. Generally the first evidences are observed on the flexor surfaces of the extremities. From extension over the trunk and confluence of the efflorescences the redness, in the course of a few days, involves the entire surface, with edema of the eyelids or lips. At the end of about a week the exfoliation begins. In numerous cases the scalp hair falls out, and many times the nails are also lost. The malady generally runs a favorable course. From scarlet fever it is to be distinguished chiefly by the universal lamellar exfoliation.

In the majority of cases, as suggested by the active sudden prodromal symptoms, the disease is probably of toxic origin (*dermatitis scarlatiniformis exfoliativa toxica*) (Plate 15).

Pityriasis rubra (Hebra), in general a rare disease, is the type of the chronic exfoliative erythrodermias. It is distinguished by its chronic course, lasting years; and consists of an intensive reddening of large areas of skin with thick scaliness, or in a quite generalized constant exfoliation of the upper epidermis layers as fine white lamella. In this malady there is no marked infiltration, no papules or vesicles, and never any oozing. In its further course the skin, especially about the joints, where it is more tense, becomes shriveled, and in these places rhagades and even ulcers may form. Falling of the hair, and also thickening and fragility of the nails are often noted. The subjective symptoms are rarely troublesome, occasionally itching being present. In most cases, after years of duration, there is a disposition for the malady to become more serious; digestive disturbances, profuse diarrhea, and vomiting are added; the general nutrition suffers, the patients become emaciated, and finally die of marasmus. Cases of cure in this disease are seldom observed.

In the histologic examination of these cases one finds a heightened proliferation of epithelial cells, which are

incompletely cornified, and at the same time slight evidences of an inflammatory process in the upper layers of the corium.

The etiology of the malady is completely unknown. It has been variously considered as a trophoneurosis and also as an infectious disease. A relationship between this malady and tuberculosis has been entertained (Jadassohn). In this connection I can say that in the case here pictured (Plates 16 and 17), which is identical with pityriasis rubra chronica, the autopsy disclosed tuberculosis of the lungs.

As contradistinguished from these generalized exfoliative erythrodermias, several circumscribed varieties of the same have been described in the past few years. Here belong *parakeratosis variegata, pityriasis lichenoides chronica* (Juliusberg), *dermatitis psoriasiformis nodularis,* and the *erythrodermie pityriasiques en plaques disseminées* of Brocq.

The question whether these three forms are in fact different diseased processes cannot for the present be answered, especially as such cases have only been observed in scant number, and histologically, beyond evidence of a parakeratosis, show nothing characteristic. All have in common patch-like hyperemic, slightly raised efflorescences, which have a branny exfoliation, and upon scratching off the scales only exceptionally show bleeding points (as opposed to psoriasis); and further, they all are rebellious to every therapeutic plan. The cases of parakeratosis variegata appear to be the most influenced by treatment. With this malady there can occur coalescence of nearby plaques.

Brocq has classified all these cases as having some connection with psoriasis, under the name of *parapsoriasis.* Still more recently Himmel has contended for the individuality of pityriasis lichenoides chronica.

KERATOLYSIS OR EPIDERMOLYSIS BULLOSA HEREDITARIA.

This malady, first described by Köbner in 1886, is characterized by an inborn or hereditary disposition to the formation of blebs, by which the slightest trauma can give rise to their formation. The malady may exist from the time of birth, or begins shortly after birth, and is then observed at various times throughout life. The blebs appear arbitrarily upon any part where the skin surface is exposed to mechanical irritation. First, a red hyperemic, slight itchy patch presents, in the middle of which in the course of a few hours develops a cherry- to nut-sized bleb with clear contents. After a short time these blebs break and dry up. No scars are left, a proof of the superficial site of the affection. As a rule, there result no permanent changes in the skin; the general condition of the subject is, during the whole course of the malady, likewise not affected. Inasmuch as hyperidrosis has often been observed in connection with epidermolysis bullosa hereditaria, the former has been looked upon as having an etiologic bearing. It is, however, by no means settled that hyperidrosis is really the primary causative factor. Some of the cases described in recent years under the name of keratolysis hereditaria appear more properly to belong to the pemphigus group.

Treatment is powerless to remove the disposition to the bleb-formation, and is, therefore, purely symptomatic, with a regard for lessening the discomforts of the affection. Jarisch has stated that he saw favorable action from the administration of Fowler's solution.

DERMATITIS EXFOLIATIVA NEONATORUM (Ritter).

This malady is one only observed in infants, and usually in epidemic form. It begins with an intense dark-red color of the skin, very similar to that in erysipelas; for this latter reason it was first described by

Ritter under the name of *dermatitis erysipelatosa*. The redness appears, as a rule, first on the lips and in the neighborhood of the mouth, the lips appearing puffed and thickened, preventing full opening or closing of the mouth. The redness then spreads rapidly over the face and the trunk. In its further course the skin is thickened, with numerous rhagades, and here and there lifted up into blebs. Frequently the hairs and nails share in the malady.

Histologically it has been found to be an inflammatory process, especially in the upper layers of the corium. The cause is unknown.

In consequence of the secondary infection through the cracked and morbid skin, phlegmon and gangrene may supervene, which, in emaciated and weakened infants, lead to death. The malady is, in fact, a fatal one in 50 per cent. of the cases. In many cases, in which large areas of the epidermis is lifted up with serous undermining or extensive bleb-formation, constituting the preponderant symptom, there is great resemblance to burns or scalds, and on this account may become of medicolegal importance (Ostermayer). This author observed in one case a contact infection from the infant to the mother on the nipple; while the affection in the mother remained limited to the breast region, the child, with universal bleb-formation, succumbed.

Treatment.—In the inflammatory stage, applications of aluminum acetate; when there are abrasions, mild spread salves (zinc oxid salve, boric acid salve); and further, the employment of those remedies locally which exert a cornifying influence (resorcin, ichthyol). Frequent baths in a decoction of oak bark (a pound to about five quarts of water to be added to the bath) are said to have a favorable influence. The body warmth should be cared for by means of coverings and envelopment in cotton wadding.

VESICULAR AND BULLOUS ERUPTIONS.

EXANTHEMA BULLOSUM NEUROPATHICUM.

This malady distinguishes itself from other vesicular and bullous eruptions by the fact that it presents itself as a localized, irregularly distributed eruption of bullæ, and usually upon an extremity; the lesions when at all recent have crystal-clear contents, soon break, and are surrounded with a reddish-brown pigmented halo (Plate 18). The eruption develops mostly on the distal end of the extremity, accompanied with burning and shooting pains, and spreads from this original point of outbreak; the fresh outbreaks of blebs are always associated with a painful feeling of burning. Many of the blebs do not reach full development, and look like brown-pigmented spots or patches of skin. While the freshly developed blebs with clear contents are well distended, the older are noted to be somewhat flaccid and exhibit milky or hemorrhagic contents.

The disease relapses frequently on the same region. Its etiology is unknown, especially as to its relations with changes in the nervous system. The malady is mostly met with in anemic and chlorotic individuals.

HERPES ZOSTER.

Herpes is a name given to a group of dermatoses which appear acutely as groups of vesicles, which are upon inflammatory bases and associated with subjective symptoms of burning, pricking, or neuralgia; and which dry to crusts.

The main representative of this group is *herpes zoster* (Plates 12 and 13). Its appearance is frequently announced by sensations of pain in the domain of the nerves in which the eruption is about to occur; or patients often feel only a burning sensation in the affected area shortly before the lesions appear. Slight inflammation and swell-

ing of the skin in the region of one or more nerves ensue, and papules crop out on the surface, which in one to three days become translucent vesicles, varying in size from a grain of buckwheat to that of a pea. This condition may retrograde and abort. The disease, however, often continues to spread; the bullæ frequently attain the size of a bean and cover the entire affected areas of the involved region, with the exception of the red borders.

The contents, at first serous and transparent, gradually become turbid, and finally dry up into brown scabs. The inflammation declines; the pain becomes less intense or ceases, or is limited to atypical recurrent neuralgias, which annoy patients once or several times daily. The disease usually lasts three to six weeks.

This typical course differs very materially in some cases; extravasations of blood, accompanied by violent neuralgic pains, may impart a blue or dark-red color to the bullæ (*zoster hæmorrhagicus*). Not only the bullæ, but also the tissue base (upper layer of the corium) are permeated by hemorrhages. The severest variety, known as *zoster gangrænosus*, is accompanied by high fever and pain, and the accompanying dark-greenish discoloration indicates necrosis of the skin (Plate 19). As a result of mixed infection, pustules may result.

Zoster of an uncomplicated type, as already remarked, gets well in several weeks and new epidermis is formed under the scabs. In zoster gangrænosus the gangrenous eschar is separated by suppuration and an ulcerated surface results, which cicatrizes slowly and leaves keloidal cicatrices behind. After the objective phenomena have disappeared, patients frequently, more particularly those of advanced years, complain for a long time of anesthesia in the affected areas; more frequently, however, of neuralgias, paralyses, and trophic disturbances, manifested by atrophy of the muscles, and sometimes by falling of the down or hair of the involved part.

Histologically the malady presents the findings of an acute circumscribed inflammatory process with bleb-

formation, and a peculiar coagulation necrosis of the epithelium.

Herpes zoster faciei et capillitii corresponds to the region controlled by the trigeminus. In the domain of the first branch of the trigeminus zoster occurs most frequently on the eye, upper eyelid (nervus supra-orbitalis), angle of the eye (n. supra-orb. et trochlearis) (Plate 20). Zoster cervicalis (Plate 21) corresponds to the domain controlled by the second, third, and fourth cervical nerves. The occiput, nucha, neck, and region of the shoulders also belong to the cervical plexus. The region of the upper extremities is supplied by the brachial plexus and by the first and third intercostal nerves. The region of the chest is controlled by the intercostal nerves. The nates, abdomen, and genitalia, and part of the thighs belong to the domain of the lumbar and sacral plexuses, herpes lumbosacralis (Plate 19). The last supplies the skin of the perineum, of the genitalia, and of the posterior surfaces of the thighs, and the nates downward over the extremities to where the crural nerve begins on the thigh.

This disease, originating solely under the influence of the nerves, is usually unilateral and follows the distribution of single nerve branches. The intervertebral ganglia have been found to be diseased, which, as we know, receive an anterior motor and a posterior sensitive root from the spinal cord. Consequently, the most frequent form of zoster is one which follows the peripheral distribution of a spinal nerve. Of the cephalic nerves it is usually the trigeminus, in which the ganglion Gasseri plays the same rôle as the intervertebral ganglia, already mentioned, do in the spinal nerves. Besides this common etiologic factor, central diseases of the brain and spinal cord, especially diseases of the vasomotor centers, may give rise to zoster; *bilateral zoster* is attributed to this cause. Finally, the nerve branches may develop a perineuritis in their peripheral distribution or irritability, due to pressure, and in this manner a herpetic eruption may ensue without the central part participating. In this case

the herpetic eruption follows the ramifications and anastomoses of the peripheral nerves, and does not always adhere to the main trunks; consequently there occur completely isolated foci of herpes zoster which are not covered by the main nerve trunks.

The clinical pictures of zoster correspond to the localization and to the severity with which the nerves have been affected by the toxic influence. In thoracic zoster we notice the first eruption of vesicles at the greatest curve of the ribs, in about the posterior axillary line. The anterior pectoral portions usually follow. Vesicles in groups, corresponding to a small cutaneous branch, five to eight in number, invariably appear, and are developed in a certain place contemporaneously and in the same manner. The succeeding crops behave likewise, and we can frequently demonstrate fresh vesicles at the periphery along with central groups which are drying up. It is noted that the herpetic vesicles frequently do not adhere strictly to the region which the ramifications of the nerves seem to assign to them, and appear on the median lines or ascending or descending in the domain of neighboring nerves. The anastomoses of the cutaneous nerve branches (known to exist) alone can be held accountable for this.

Hemorrhages into the ganglia and inflammatory changes in them, or when long continued leading to death of the nerve elements, diseases of foci of the brain or of the spinal cord, cicatricial formation with remnants of pigment and preceding hemorrhages, lead to diseases of the nerves or nervous system, giving rise to zoster. Direct causes are frequently traumatic in character, as an injury, a blow, pressure on a nerve or ganglion by neighboring organs—*e. g.*, exudations, inflammations, diseases of bones (periostitis, exostitis), or carcinomata. Sattler has observed toxic forms of zoster, especially in the domain of the trigeminus, follow carbonic oxid poisoning; and Blaschko and others have observed it follow arsenical administration. Malaria may also lead to neuralgia and zoster.

Besides these recognized causes, the etiology of a number of cases of zoster is entirely unknown. Its epidemic appearance, frequently associated with other acute infectious symptoms or diseases, appears to point to an infectious cause, which, however, still remains to be proved.

Zoster usually attacks adolescents and young adults, old individuals less often, children infrequently.

Treatment.—The affected areas are to be dusted with an indifferent powder, or mild salve can be used; when the pain is severe, extract. opii, extr. belladonnæ, or orthoform may be added. To control the neuralgic pains sodium salicylate, antipyrin, pyramidon, aspirin, chloral hydrat., quinin. hydrobromat. (Wolff); occasionally hypodermic injections of morphin must be employed to relieve the torturing neuralgia of some patients. Scharff injects Schleich's solution in the intercostal space, close to the point of exit of the nerve:

℞ Cocaini hydrochlor., 0.2–0.4 (gr. iij–gr. vi);
Sodii chlorid., 0.4 (gr. vj);
Morph. hydrochlorat., 0.05 (gr. ¾);
Aq. destill., 200.0 (f℥viss).—M.

Sig.—Liquor anæstheticus (Schleich).

HERPES FACIALIS ET PROGENITALIS.

The frequent herpetic eruptions on the face and genitalia do not follow the type of zoster. They are preceded by slight itching, and appear on the mucous membranes and neighboring skin and form groups of vesicles, each vesicle the size of a pinhead to that of a lentil, situated on a slightly reddened and somewhat raised base. Herpetic eruptions around the entire mouth, involving the carmin of the lips and extending to the mucous membrane, are only infrequently met with, and in such instances only when catarrh of the cavity of the mouth exists. Herpes around the nostrils is frequently associated with herpes

labialis. This form of herpes occurs almost exclusively in young subjects with slight catarrhal affections accompanied by fever, coryza, and bronchitis; also in grave diseases of the respiratory tract, pneumonia, and intermittent fever. In earlier times an outbreak of herpes labialis in a general systemic disease was considered an important diagnostic symptom of pneumonia as against typhus, typhoid, and other febrile maladies.

Herpes facialis has also been observed to follow the administration of certain remedies (arsenic, antipyrin).

The so-called "*idiopathic herpes facialis*" presents a picture of an acute infectious disease with abundant herpetic lesions about the mouth and nostrils, frequently also in the mouth and throat (*angina herpetica*).

Genital herpes behaves in a similar manner. In men it occurs most frequently on the prepuce (*herpes præputialis*), more rarely on the glans. Although of short duration, this disease often occasions diagnostic difficulties, and is of great importance to the physician, inasmuch as energetic caustics and strong remedies may convert it into a chronic torpid affection resembling infectious ulcers. Very frequently slight swelling and tenderness of the inguinal glands accompany herpes progenitalis. In women genital herpes is met with on the labia minora and majora, which are more or less swollen; we have repeatedly seen herpes spread over the entire external genitals, the perineum, and the inner surfaces of the thighs as a very grave and painful disease.

In both sexes it can also be localized in the urethra and stimulate a urethritis.

The exact causes of these forms of herpes are unknown; they are probably of nervous origin. Fright, excitement, and slight febrile disturbances at times give rise to herpes labialis and facialis. In some individuals herpes præputialis may be due to persistent erection, and also may show itself within two or three days after sexual intercourse. Herpes genitalis is noted for its tendency to frequent recurrences.

According to Kopytowski, the histologic picture in herpes progenitalis and zoster are the same.

Treatment of this herpetic disease consists in application of mild dusting-powders or salves. The parts should be protected; caustics should be avoided. The remedies variously recommended as having some influence in warding off recurrences have shown no special value.

PEMPHIGUS NEONATORUM SIVE CONTAGIOSUS.

Pemphigus neonatorum is a disease which appears in the first or second week of life; the main symptom is the formation of bullæ, inasmuch as important disturbances of the general health are absent. The contents of the bullæ become opaque in one to two days; they grow flaccid and rupture. New red epidermis, surrounded by the remnants of the elevated epidermis, appears at the base. There are no special parts of predilection; generally the hands and feet remain free. Should any of the secretion of the broken blebs get in between the eyelids, a conjunctivitis results.

The localization of the disease differentiates it from pemphigus syphiliticus. The latter occurs on the palms and soles along with other evidences of syphilis on the rest of the body; the base and surrounding tissue are more infiltrated, this condition being entirely absent in the affection acute pemphigus, now under consideration.

In most instances the malady is at an end in a month, without any disturbance in the development of the child. The rarer form with malignant course belongs more properly to the group of dermatitis exfoliativa (Ritter). Pemphigus neonatorum is frequently observed epidemically, and in such instances, especially when it occurs in foundlings, it may have an unfavorable course.

Histologically the blebs are found to lie between the horny and prickly layers; the vessels of the corium are dilated (Luithlen). In the contents of the blebs leuko-

cytes (from the papillary vessels), epithelial cells, and staphylococci are seen.

The staphylococci, particularly the staphylococci aureus, the only bacterial organisms found in the intact blebs, are to be looked upon as the cause of the disease, inasmuch as they are constant findings in the blebs, as well as in less number in the lymph vessels; further, inoculation with pure cultures of staphylococci obtained from these blebs has produced true pemphigus contagiosus. Thus is explained the contagiousness of the malady and its epidemic appearance. In many cases of pemphigus neonatorum septic conditions of the mothers have been associated, which, as is well known, are due to streptococci as well as to staphylococci. In these cases a connection between the two processes, such as an intra-uterine infection of the child with staphylococci, is not impossible.

According to Matzenauer, pemphigus neonatorum is bacteriologically and histologically identical with impetigo contagiosa. He believes that, in consequence of the difference in firmness and consistence of the skin in infants and older children and adults, the malady appears in the latter as impetigo contagiosa.

In the **treatment,** of first importance is the recognition of the contagiousness of the malady and the necessary measures to limit and prevent its spread.

In the stage of bleb-formation, powder applications are the most satisfactory; the bathing of the infants should be omitted, in order to prevent its extension. It is not necessary to remove the bleb covering. If the blebs have ruptured, more rapid skinning can be obtained by the use of spread salves.

IMPETIGO SIMPLEX.

This malady, described by Bockhardt [first of all, however, as a distinct malady, by Prof. Duhring—Ed.], appears in its earliest formation as bright-red papules on the skin, which rapidly enlarge and develop quickly into

pustules. Sometimes the suppurative action ends in the formation of true furuncles. The lesions are usually found in groups on any part of the body, rarely also on the mucous membrane of the mouth and genitalia. The pustules heal with central depression and scar-formation. The primary papular efflorescences of the disease are provoked by staphylococci invasion (staphylococci aureus et albus). The affection runs its course, as a rule, without any general disturbance worthy of mention.

IMPETIGO CONTAGIOSA (Tilbury Fox).

As already mentioned in the description of pemphigus neonatorum sive contagiosus, impetigo contagiosa, according to the investigations of Matzenauer, Luithlen, and others, is only a variety of pemphigus neonatorum. It is observed also with adults (Plate 33); mostly in children's nurses, and in an epidemic manner among infants. It consists of pinhead- to pea-sized vesicles, which develop acutely without any accompanying general symptoms, and dry to honey-yellow crusts, and after healing leave for a short time a livid discoloration. The fresh blebs have a glistening, yellowish appearance. From peripheral extension together with central drying arise ring or segmental lesions (*impetigo contagiosa circinata*, *annularis*, *serpiginosus*). Unna separates impetigo circinata from impetigo contagiosa sive vulgaris, considering it a special form of disease. In the impetigo pustules are found several kinds of staphylococci (staphylococcus aureus et albus). Pure cultures from these bacterial forms which have been taken from intact impetigo pustules have given rise to the typical impetigo pustules with the characteristic straw-yellow crusts.

In adults the malady is relatively infrequent, occurring chiefly in those with tender skin, and in whom it usually presents in the circinate form.

Treatment.—Softening and removal of the crusts with oil or salve applications, and following with application

of a 2 to 5 per cent. white precipitate salve or Lassar's paste. An associated disinfection of the involved regions, recommended by many, is in general superfluous. Energetic washing with soap and water can be employed without risk of infecting new points.

IMPETIGO HERPETIFORMIS.

This rare skin disease has been observed, with but few exceptions, only in pregnant women and during the puerperium. The eruption begins on the inner surfaces of the thighs and inguinal region, on the umbilicus and breasts, spreads over the whole body, and even appears on the mucous membranes. Innumerable whitish vesicles of pinhead size, situated on a reddened, slightly swollen base, develop, whose contents become opaque and dry into a thin whitish crust. The eruption, which at first is confined to areas the size of a pea to that of a penny, spreads rapidly, and in a few days larger regions of skin are invaded. The vesicles are arranged in circles, ellipses, or bands (Plates 22, 23, and 24). The eruption extends in the following manner: A reddened and swollen zone appears at the periphery of a desiccating area or border, upon which new lesions form. Upon removal of the above-mentioned thin, dirty-white crust, newly formed epidermis is either found underneath or the skin is moist after the manner of eczema rubrum. In an advanced stage of the patches, when the generally extending peripheral vesicles and blebs pustules are absent, the affection bears resemblance in appearance to a psoriasis.

The gravity of the disease is indicated by the condition of the general health. The patients have continued or remittent fever and rigors; they are prostrated and have lost interest in everything; the tongue is dry; there are vomiting at times, stupor, and even delirium.

The **prognosis** is very unfavorable. Of fifteen cases, thirteen ended fatally (Kaposi). A pregnant woman, who passed through the disease after delivery, and devel-

oped grave symptoms, came under our observation; she recovered so far as to be able to leave her bed; the fever, however, returned, and she perished rapidly, exhibiting signs of collapse. Postmortem findings were negative, as in other cases reported.

The **etiology** of this disease is unknown. Inferring from the course it pursues, it may be regarded as an infectious disease allied to some erythemas and varieties of herpes and pemphigus. Neumann's opinion, based upon the frequently present concomitant puerperal diseases, that the malady is to be viewed as a pyemic metastasis to the skin, under the name of *herpes pyæmicus*, is not supported by the numerous negative section findings. Kaposi has observed the disease in a male adult, who died of tuberculosis.

Treatment is wholly symptomatic. In all cases so far observed it could not be demonstrated that the disease is influenced by any therapeutic remedies.

PEMPHIGUS.

We apply the name pemphigus in its narrower sense to bullous eruptions whose course is distinguished by an eminently chronic character. We recognize several varieties of chronic pemphigus, but these are all examples of the same morbid process with a preponderance of one or several of the usual symptoms.

Pemphigus Vulgaris.—The far greater number of pemphigus vulgaris cases must be designated as a febrile disease, as they are ushered in by rigors, rise of temperature, nausea, and other disturbances. Usually outbreaks of erythema precede the eruptions of bullæ, and wheals resembling erythema annulare, figuratum, and urticatum appear. Tense blebs develop on these wheals or erythematous spots. They may, however, appear on apparently normal skin without being preceded by other formations. The bullæ, which at first are the size of a pea, attain the size of a nut; or when numerous and close together

they become confluent and develop various irregular forms.

According to the arrangement or configuration of the blebs, such varieties or types as **pemphigus circinatus, pemphigus serpiginosus,** and **pemphigus gyratus** are described. Pemphigus circinatus is frequently the early stage of a **pemphigus foliaceus.** If the floor of the blebs is covered with an adherent membranous exudate, such a variety is designated as *pemphigus crouposus* (Hebra). So-called *pemphigus pruriginosus* is characterized by its troublesome itching.

It is not so much the size as the number of bullæ appearing on the skin at the time of the eruption which characterizes a case as being of more or less gravity. The contents, at first serous and limpid, become opaque in a few days, the bulla ruptures, and the covering and exudate dry into a scab which is usually of a hemorrhagic character. In rare cases blood is in the earliest stage mixed with the contents of the bullæ. The inflammation is more marked where the bullæ and, later, the scabs cover large areas. The skin becomes hot and painful. Sometimes the disease is complicated by lymphangitis and adenitis.

Subjective symptoms are partly dependent upon impairment of the general health, thirst, anorexia, and marasmus being not infrequently associated; partly upon the processes on the skin, as burning, pains, tension, and itching, which interfere with sleep. The scabs gradually fall off and a young bluish-red epidermis appears underneath, which later becomes pigmented and may remain so for varying lengths of time. Cases pursuing a benign course may terminate in two to six months, although such individuals may expect recurrences sooner or later.

There are, however, very mild cases of pemphigus, in which the disturbances referred to are only observed in a minimal degree, and whose course is accompanied by only slight formation of bullæ. On the other hand, malignant cases occur, in which numerous lesions appear and in which the above-mentioned systemic disturbances are very marked.

In these latter cases the mucous membranes are also usually involved; and in such we may meet with bullæ and erosions having a whitish coating on the mucous membranes of the oral cavity, of the lips, tongue, palate, larynx, and pharynx, which are not only painful, but when involving the larynx may give rise to symptoms of suffocation. Blebs occurring in parts of the upper air passages are rapidly broken by the reflex muscular movements and the coughing; only in the nasal mucous membrane is opportunity given to see intact blebs (Seifert); presence of which gives rise to a peculiar sipping noise. Inasmuch as the cleaning of the affected mouth cavity causes considerable pain, it is apt to be neglected, and, as a result, is the source of a strong fetor. In consequence of the constant irritation of coughing, and of the hindrance to the taking of proper nourishment (on account of the mouth condition) and the difficulty of breathing in patients with pemphigus blebs in the upper air passages, the strength is soon undermined and they have a deplorable appearance.

The conjunctiva and cornea can also be attacked with pemphigus. It can lead to the formation of a symblepharon, the cornea can become covered with a gray coating, and, in fact, the whole eyeball can be destroyed.

According to the severity and course of the malady, it is usual to recognize a *pemphigus vulgaris benignus* as distinct from *pemphigus vulgaris diutinus* (Plate 25). But these two names do not indicate two distinct disease processes; pemphigus benignus presents only a preliminary step of pemphigus diutinus.

Pemphigus Foliaceus.—Pemphigus foliaceus differs from the pemphigus variety just mentioned by its more severe type and graver course. This condition develops either after a long duration of pemphigus vulgaris, out of the form of pemphigus circinatus, or appears simultaneously with the latter; or quite flaccid bullæ appear from the first, whose cover is macerated and rapidly lifted off, leaving the corium denuded and red. Pemphigus foli-

aceus is a result of the thinness of the epidermis, which can no longer be lifted up with serum into blebs, but is simply torn by the serous exudation in numerous places. The cause of this cessation of bleb-formation is to be found either in this thinning of the skin, due to preceding bleb-formation, or is due to the weakened general health of the patient, in which condition the skin shares.

Owing to very deficient regeneration of the epidermis, we meet with large excoriated areas which are partly covered with remnants of epidermis and with epidermic lamellæ, dried into thin crusts. Between the lamellæ the denuded corium or an imperfect epidermis appears. The scales are loosely adherent to the surface and exfoliate very readily (therefore, "foliaceus"). Owing to the gradual spread of the disease, the entire body surface becomes affected. Irregular lines of skin denuded of its epidermic cover extend between the scales and exude serous fluid, which causes the clothing and dressings to adhere to the body. The hair of the entire integument is loose and usually falls out; the nails are thin and brittle.

Pemphigus foliaceus, on account of the profuse serous exudation, which means the loss of quantities of albumin, is a grave malady. Patients experience great pain with every motion; owing to fever and excessive diarrhea they become markedly emaciated and sooner or later succumb. In those cases especially in which the whole or a greater part of the entire surface is involved in the exudative process, death is apt to follow quickly. According to Fabry's histologic investigations the local conditions of the malady is to be explained by the strongly developed granuloma of the cutis with secondary parakeratosis.

Pemphigus vegetans (*pemphigus framboesioides*) (Plates 26 and 27) is a very malignant form of chronic pemphigus, which is especially characterized by warty and papillomatous vegetations on different parts of the body. About the entrance of the mouth and nasal openings, in the axillary regions, about the navel and about the genitalia or anus appear small millet-seed-sized vesicles

with milky contents. These break and the floor becomes covered with a dirty-white secretion. These coalesce and upon them arise papillomatous vegetations, which continue to spread in a serpiginous manner. At the edge of such areas one often sees fresh vesicles, which are soon broken or torn. In almost all of the cases the mucous membrane of the mouth shares in the malady, and, indeed, it often begins here. When the navel is involved it becomes the seat of a projecting flesh-colored growth. The papillomatous vegetations have a rancid, bad-smelling secretion; they remain more or less stationary, without a tendency to necrosis.

The flesh-colored torpid vegetations about the anus and genitalia, at whose borders, or neighborhood, fresh vesicle-formation can be still observed, are comparatively easily distinguished from the luxuriant moist papules of syphilis, the latter being associated also with other syphilitic symptoms. The greatest resemblance is to luxuriantly developed verruca acuminata (venereal warts, venereal papilloma, Lang), so that often only the involvement of other parts will make the matter wholly clear. Generally, under increasing cachexia, pemphigus vegetans leads to death. However, there are midway cases to pemphigus foliaceus, in which the process can come to a stand. The papillomatous vegetations, under drying and disinfecting applications, flatten down, skin over and cicatrize, and can leave behind a deep-brown pigmentation. Repeatedly pemphigus vegetans has been observed at the end of childbirth.

The histologic investigations in most of the forms of chronic pemphigus have as yet not given either a typical site of the bleb or any other characteristic feature.

Weidenfeld in his histologic investigations of pemphigus vegetans distinguished four stages: the formation of an epidermal bleb, the intrabullous vegetation, the completed vegetation, and finally the vegetation with connective-tissue proliferation.

The **prognosis** of pemphigus chronicus is very un-

favorable. Kaposi estimated that for all the various forms scarcely 10 per cent. recovered permanently.

The **etiology** of chronic pemphigus has as yet not been explained. Many authors accept its trophoneurotic origin, since often disturbances of the central nervous system (syringomyelia, paraplegia, etc.) or injuries of the peripheral nerves are followed by an outbreak of pemphigus. It is to be said, however, that in numerous cases a histologic examination of the nervous system has shown no demonstrable changes.

Just as little light has been thrown on the subject by bacteriologic examination of the contents of the intact blebs (which in intact blebs is sterile), or from examinations of the urine and blood.

Postmortem investigations have not developed anything tangible; the individuals either succumbed to an intercurrent affection or to marasmus. [Comparatively few of the cases described in this country under the name dermatitis herpetiformis, which Kaposi contends are pemphigus cases, are of a fatal character.—Ed.]

Occasionally, in some instances, we are enabled by a study of the cases to advance hypotheses attributing pemphigus as a symptom of another affection of the organism, appearing on the skin. Otherwise the etiology of most cases is enveloped in darkness, and such will be the fact until we possess a more intimate knowledge of the disturbances of metabolism and of the associated chemic and toxic processes in the organism.

One form of pemphigus, as already indicated, may develop from another type of pemphigus. Usually, however, when the condition has lasted for years, we observe one form on one part and another on a different part of the body; for instance, pemphigus pruriginosus and pemphigus vegetans (case shown in Plate 33), and pemphigus foliaceus, etc.

We therefore are led to suppose that the several varieties of pemphigus are only one disease.

The **dermatitis herpetiformis** (Duhring), which is

characterized by a polymorphism of the efflorescences, troublesome itching, and for the most part a benign course, is likewise only a variety of chronic pemphigus, and is in general identical with it [a conclusion with which exceedingly few dermatologists who have opportunity of studying these cases will agree.—Ed.].

Treatment.—As the entire organism participates in this disease, the general health must receive proper attention first. The strength must be improved by tonics, proper diet, and alcohol. Of internal remedies, arsenic preparations are worthy of most confidence, although their action in pemphigus must be said to be unreliable.

Externally, inert dusting-powders, bandages, and ointments of boric acid and zinc oxid, and Wilson's ointment, etc., are used. When there is tendency to severe itching, painting and rubbing with tar and tar ointments are indicated. When large areas are denuded of epidermis and considerable serum has been lost, and treatment with ointments, owing to the general condition of the patient, is difficult to carry out (pemphigus foliaceus), the use of the continuous water bath is recommended; patients usually feel quite comfortable in it.

For the removal of the papillomatous vegetations in pemphigus vegetans both the curet and painting with tincture of iodin have been commended (Unna).

SQUAMOUS DERMATOSES.

PSORIASIS.

This disease frequently appears in individuals about puberty and early manhood. Children are comparatively seldom attacked; in advanced years it is met with, but usually as a recurrence or as a persistent eruption or remnant from the disease in earlier life.

Positive observations concerning the period of the first outbreak in adults are the least numerous. The frequency of psoriasis appears to differ very materially in different

countries, in the aggregate proportion of cases as well as to its relative frequency in the two sexes. In German countries the men furnish its greater number of subjects, while, for example, in England it is observed more frequently in women.

In the beginning the eruption consists of red papules, which in a few days show scaliness of a somewhat adherent character. The lesions increase in size and numbers, so that in the course of a few weeks the older efflorescences are to be seen as flat, rounded, scaly patches with a red border, while recent lesions are seen near by. Scratching off the scales brings the bleeding papillary body into view, an important differential sign between this and other squamous dermatoses.

Typical psoriasis vulgaris has as favorite localities the extensor surfaces of the extremities, particularly the elbows and patellar regions, and also the scalp, breast and abdomen, the sacral region, and the glans penis. In almost all cases the palms, soles, the face, and the mucous membrane remain free.

According to the predominant form and size of the lesions, it is customary to designate the eruption by various names. In the early stages, when the lesions are mostly of small size, as already mentioned, it is designated *psoriasis punctata* (Plate 35); if the plaques are flat with considerable scaliness, it presents the so-called *psoriasis guttata*, from its resemblance to the condition which would be produced by sprinkling a handful of mortar over the skin (Plate 35). If the eruption consists of moderate-sized, flat, and scaly patches, it constitutes the most common clinical variety—*psoriasis nummularis* (Plates 37 and 38).

When there is a marked tendency for the lesions to become confluent and to melt into each other, the result is an eruption of various forms, concave and convex lines—*psoriasis confluens figurata* (Plate 36).

Further along in the course of the disease, or in some cases appearing early in its course, the central part of the

patches tends to disappear and the disease spreads peripherally, producing rings of various sizes—*psoriasis annularis, psoriasis circinata* (Plates 40 and 41). In this variety, if the circles run together, the meeting borders melt away and give rise to irregular, tortuous, scaly bands—*psoriasis gyrata* (Plate 42).

Finally, if the lesions grow to considerable size and new outbreaks occur, large confluent areas result, infiltrated and scaly, along with the ordinary, scattered, variously sized lesions—*psoriasis diffusa universalis.*

The process may involve the nails, which become milky, break easily, crack, and from time to time may crumble or be cast off entire. Schutz describes a nail condition characteristic of psoriasis, the so-called "dot psoriasis" (Tüpfelpsoriasis) of the nails, characterized by cracked, small cavity-like depressions of the nail plate. In rare instances, and then only after long-continued psoriasis of the hairy scalp, the hair may fall out to some extent.

As a rule, patients are apt to have psoriatic patches on the extensor surfaces of the knees and elbows for years, and then for some unknown reason efflorescences show themselves on the trunk and limbs.

In rapidly developed cases the inflammatory characters may sometimes, in the course of three or four weeks, show considerable retrogression; the plaques become much flattened and the scaliness less marked. In most cases, either through spontaneous retrogressive changes or as the effect of treatment, most of the patches disappear; but frequently there remain slightly perceptible remnants on the places of predilection—the knees and elbows. When this is the case the patient can be almost sure that the disease will in some months begin to spread afresh.

As to subjective symptoms, the most common is itching, especially associated with the disease in those cases in which are marked infiltration and inflammation of the papillary layer. In severe cases there may be gastric disturbance, restless nights, and the appearance of painful fissures about the joints and flexures, so that the patient becomes incapa-

ble of getting about, and is obliged to give up work and for a long time to keep his bed.

The pathologic basis of psoriasis is an inflammation in the papillary layer. The vessels are hyperemic, the upper corium and stratum papillaris are infiltrated with serum, and around the vessels are seen cell-collections. The rete is somewhat relaxed and edematous; to this is due the fact that in the matured lesions the accumulated and horny epidermis may be rubbed off by light scratching, and from the underlying hyperemic blood-vessels bleeding is readily produced. The hyperemia of the psoriatic patches, according to Unna, depends chiefly upon the dilatation and spiral formation of the venous capillaries, the arterial capillaries being normal. It is still undecided whether the psoriatic process originates in the papillary vessels or from the rete. According to the age of the psoriatic plaques the color and appearance vary slightly.

To the rapid reproduction of the epidermis cells is due the fact that the scales are silvery and shining, not having time to go through the process of cornification. Old patches, on the contrary, show thickening of the skin due to hyperplasia in the papillæ and connective tissue, even to the extent of becoming somewhat wart-like (Kaposi).

In the **diagnosis** between psoriasis and the papulo-squamous syphiloderm, the more pronounced brownish color of the lesions and the grayish-white color of the scales of the syphilid, as well as other syphilitic evidences, are different from the bright-red color of the psoriasis papules and the silver-white color of their scales.

Ringworm of the body differs from psoriasis by its predominant appearance on the trunk, the rarely failing itching, and the peripheral arrangement of the scaliness. [It is to be remembered that this type of ringworm occurring in numerous patches is uncommon with us, and also that many of the German authors still continue to consider pityriasis rosea as ringworm; the differentiation here given being based largely upon these cases.—Ed.]

The psoriasiform lichenoid exanthem (pityriasis lichenoides chronica) shows no typical localization as psoriasis and also shows great rebelliousness to any treatment.

On the hairy scalp psoriatic scales can give the malady a resemblance to favus; the characteristic odor and the usually present scarring or atrophy and hairless areas and the demonstration of the fungus in favus confirm the diagnosis of this latter disease.

Several **atypical forms of psoriasis** have been described which were distinguished either by peculiar appearances on the skin itself or by complications with joint or organic diseases. As yet, it is not proved whether these complications have any relationship to the psoriasis, or whether, as is more probable, they are accidental only.

We have repeatedly observed psoriatics with marked disturbances of the general health. The patients feel weak, show atypical temperature changes, and complain of unrest, sleeplessness, and loss of appetite. The psoriatic patches may be succulent, elevated, covered with dirty-white scales, and surrounded by an inflammatory halo or band several millimeters in width. Gradually the subjective symptoms abate, the psoriatic plaques flatten, and there develops the usual picture of psoriasis, in which the involution period is apt to be more rapid than usually observed. This peculiar course and condition we do not venture to ascribe to the cause responsible for the psoriasis; but it impresses one as being due to some toxic agent, as in the erythemas.

We have pictured a case of this kind with dollar-sized and larger plaques with inflammatory appearances (Plate 39). It was also remarkable in that on the hairy scalp was seated a large and hard scaly or crusted plate-formation of a dirty-white color, which we were able to loosen in mass, representing a cast of the parts. Under this the skin was infiltrated, slightly reddened, and covered with recent epidermis.

In other instances we observed eczema in psoriatic patients which partly masked the clinical picture of psori-

asis; an unfortunate complication, inasmuch as the patients were troubled with constant itching; and we frequently, on account of the presence of the eczema, could not treat the psoriasis with the ordinary therapeutic methods. These cases are in reality a psoriatic variety of the so-called eczema seborrhoicum, and are peculiar to uric acid subjects, and who may continue to be troubled with the malady for years.

In recent years cases of psoriasis complicated with joint affections have been described. Such a case was observed in Lang's Clinic, and described as *psoriasis ostreacea* by Dr. Deutsch in *Wiener klinische Wochenschrift*, 1898, No. 6. This case, owing to its extent and the intensity of the process, and the peculiar form of the efflorescences and the associated joint affection, is especially interesting. Gassmann published a similar case as *psoriasis rupioïdes*, and Grube several such associated with gout and diabetes.

We have (Plates 43, 44, 45) pictured a similar case, and saw also, on a visit to the City Hospital in Ragusa, a second case, which in addition to severe joint affection presented horn-like, heaped-up, pyramid scales and large, dirty-white, mortar-like crusts. As yet we are not certain that these cases simply represent a very intense process; but must believe that uric acid is the additional causative element.

The **etiology** of psoriasis has been the subject of numerous attempts at solution, but from which there has evolved as yet no uniform opinion. Inasmuch as psoriasis generally is seen in well and strongly developed individuals in the prime of life, one cannot well believe that the malady is an expression of cachexia or a general systemic dyscrasia, especially as the patients are commonly in the best of health when the eruption presents. [This might be questioned, and at all events there are many exceptions to such a sweeping statement.—Ed.]

From many sides the infectious character of the malady has been, and is still, maintained. Lang described an epidermophyton as the cause of the disease, a finding especially negatived by the investigations of Ducrey. The

attempts by Lassar and Tommasoli of the conveyance of the disease from man to animals are without tangible results. As a proof of the infectious nature of the disease some observers have cited alleged examples of psoriasis after vaccination, of its communication from one individual to another with whom he had been in constant and intimate contact (nurses and children, husband and wife, etc.), but these are too few and uncertain to carry any weight.

In 394 cases of psoriasis analyzed by Greenwich a hereditary disposition was disclosed in 97 (25 per cent.).

Of the numerous theories may be mentioned that repeatedly a neuropathic basis for psoriasis has been alleged and accepted. Koebner looks upon psoriasis as the result of a hereditary, sometimes acquired, disposition of the skin to react, in the form of psoriatic efflorescences, to internal or local irritants. In support of this view he cites the well-known observation that in psoriatic patients new spots can be provoked by local irritation on healthy parts, as, for example, at the point of vaccination, in tattoo marks. In apparent agreement with this conclusion Weidenfeld lately has declared that for the development of psoriasis a peculiar condition of the skin is necessary, and cites in substantiation of this belief an interesting case: In a case of poliomyelitis anterior acuta in an individual with psoriasis, paralysis of one of the lower extremities resulted; on the paralyzed limb some psoriasis, it is true, began to appear, but disappeared after a short time, for the reason, as he considers, that the psoriasis, apparently in consequence of the nerve lesion, did not find the proper or necessary skin condition for its further growth and development.

The **prognosis** in psoriasis is usually favorable. Spontaneous involution of the psoriatic patches of the first attack and the recurrences is not uncommon. Besides, modern methods of treatment have an influence. Severe, complicated cases, such as those mentioned, or the accidental infection through the fissures, which may occur about the

joints, with the erysipelas or phlegmon microörganism, may threaten the life of the patient.

Treatment.—Internal Remedies.—1. *Arsenic.*—(*a*) *In the Form of Fowler's Solution.*—Six drops are given daily, divided into three doses and taken diluted. Every day the amount is increased by one drop. One can in this manner increase the quantity up to thirty drops daily, remaining at the dose at which involution of the psoriasis is observed to take place; not to be discontinued suddenly when apparently completely cured, but returning gradually to a less and less quantity (Kaposi).

(*b*) *As Asiatic Pills.*—

℞	Arsenici albi,	0.75 (gr. xj);
	Pulv. piperi nigri,	6.0 (ʒiss);
	Pulv. acaciæ,	1.5 (gr. xx);
	Pulv. althææ,	2.0 (gr. xxx);
	Aquæ fontan., q. s.	Ft. pil. No. 100.

Sig.—Three pills to be taken daily.

Every fourth day the dose is increased by one pill up to ten or twelve pills daily; and in the same manner as with Fowler's solution, gradually lessening this quantity after an apparent cure. The pills are to be taken immediately before meals. [Less apt to disturb if taken after meals. —Ed.]

In addition to these methods of administering this remedy, it may be given by subcutaneous injection—of Fowler's solution 0.2 (♏iij) pro die; of arseniate of sodium, 0.02 (gr. $\frac{3}{10}$) pro die.

Danlos and Rille recommend sodium cacodylate for subcutaneous injection (sodii cacodylat., 4 (ʒj); aquæ destill., 10 (fʒiiss); daily a syringeful. We are indebted to this plan of treatment for some very good results, while the later-recommended atoxyl treatment (in 20 per cent. aqueous solution, Schild) has repeatedly failed.

Herxheimer injects 0.001 (gr. $\frac{1}{65}$) arsenious acid (in solution) in a skin vein of the elbow or knee region.

Every day the dose is increased 0.001 (gr. $\frac{1}{65}$) till it reaches 15 mg. (gr. $\frac{9}{40}$), at which it is kept till complete disappearance of the efflorescences.

2. *Potassium iodid* (Greve, Haslund) in increasing dosage, beginning with 3 to 4 grams (gr. xlv–gr. lx) pro die, increasing every third day about 1 to 2 grams (gr. xv–xxx), and may even be increased to 60 to 70 grams (ʒxv–ʒxviiss) pro die. Generally, this energetic treatment is well borne, but the large doses should be given while the patient is under direct observation; the result in many cases is not to be doubted.

3. *Thyroid preparations* (Byrom Bramwell); especially of these, however, the more reliable preparation, iodothyrin Baumann (Paschkis and Grosz). One begins with 0.5 (gr. viiss) of the commercial triturate, and increases the dose every three or four days by about this same quantity. Untoward heart action and psychical symptoms are to be guarded against. Should head pain and heart palpitation appear, the dose is to be intermitted; if no symptoms appear, one may increase the dose to 5 to 6 grams (gr. lxxv–ʒiss) pro die. The effect in some cases is surprisingly favorable.

External Treatment.—First of all, softening preparations, as salves, oils, sapo viridis, besides baths and rubber clothing, are employed in getting rid of the scaliness. Only after the scales have been removed is it advisable to begin with those special remedies which are commonly used in this disease. As such, may be named:

1. *Tar preparations:* Ol. cadini (oil of cade), ol. rusci (oil of birch), ol. fagi (oil of beech), pix liquida, ol. lithanthracis (coal tar), tinctura lithanthracis Leistikow (ol. lithanthracis, 30 (ʒj); spiritus, 95 per cent., 20 (ʒv); æther. sulph., 10 (ʒiiss)), solutio lithanthracis Sack (ol. lithanthracis, 10 (ʒiiss), benzol, 20 (ʒv); acetone, 77 (ʒiiss)), liquor anthracis simplex, liquor anthracis compositus (Fischel), liquor carbonis detergens (Wright, Jaddassohn); finally, anthrasol (a purified colorless tar), commended recently by Sack.

These may be applied to the psoriatic areas, either as a liquid preparation, painting on, or rubbing in, with a brush, as, for example:

℞ Olei rusci,
Ol. olivæ, āā 24 (fʒvj).—M.

Or in salve form:

℞ Pix liquidæ,
Lanolini, āā 50 (ʒiss).—M.
Ft. unguentum.

℞ Ol. rusci, 20 (fʒv);
Saponis viridis, 5 (gr. lxxv);
Lanolini, 75 (ʒij et ʒij).—M.
Ft. unguentum.

2. *Chrysarobin*, in salve form, 5 to 15 per cent. strength, or with a drying vehicle (traumaticin, collodium, linimentum exsiccans, filmogen), as, for example:

℞ Chrysarobin, 10 (ʒiiss);
Traumaticin (liq. gutta-perchæ), 90 (fʒxxiiss).

Also as chrysarobin plaster (Beiersdorf), and a 30 per cent. collætinum chrysarobini (Turinsky).

With the chrysarobin treatment the affected parts become white and the surrounding skin violet to brown. During the application of this remedy and for some days afterward baths should be prohibited, as such may tend to bring about a slight universal dermatitis.

Lately, Kromayer has recommended chrysarobin triacetate (eurobin) and chrysarobin tetracetate (lenirobin).

Less valuable is anthrarobin.

3. *Pyrogallic Acid.*—Its method of application is the same as with chrysarobin; the urine is to be watched, as absorption may take place when used too extensively.

Unna recommends "pyrogallolum oxidatum" as a safer preparation.

Kromayer applies pyrogallol triacetate (lenigallol) and pyrogallol monoacetate (eugallol).

℞ Eugallol,
Acetone, āā 10 (ʒiiss).

℞ Lenigallol, 1–5 (gr. xv–gr. lxxv);
Pasta zinci oxidi, q. s. ad 100 (ℨiij).—M.

Less valuable appears to be the application of gallanol (Cazeneuve and Rollet), and likewise gallacetophenone.

4. *Sulphur.*—This in the form of the natural spring-water baths; as Vleminckx's solution (liquor calcii sulphurat.). In using the latter the patient is first thoroughly washed with soap and water; immediately thereafter the affected areas painted with it, and the patient then gets into a warm bath and remains one to two hours.

Very efficient is the treatment with unguentum Wilkinsoni:

℞ Sulphur sublimat,
Ol. fagi, āā 50 (ʒxij);
Saponis viridis,
Adipis, āā 100 (ℨiij);
Cretæ albæ, 10 (ʒiiss).—M.
Ft. unguentum.

This salve is to be rubbed into the affected spots twice daily. After a week exfoliation of the epidermis begins; after its completion a bath is ordered.

The Röntgen-ray treatment of psoriasis has, according to reports by numerous authors, in the majority of cases shown favorable influence. We can ourselves confirm their good results. However, this method is about as powerless as the others mentioned in preventing relapses.

LICHEN.

Under the name of lichen have been understood, since Hebra, diseases of the skin characterized by the formation of papules, which during their course do not undergo any change, but persist as such. In this form appear all those dermatoses which are included under the name of lichen ruber. The two chief forms of this are lichen ruber acuminatus and lichen ruber planus. The pityriasis rubra (Devergie) is at present considered by the majority of authors as identical with lichen ruber acuminatus.

Lichen ruber acuminatus appears in the form of millet-seed-sized, reddish, irregularly scattered papules which terminate in hardened, horny epidermic points. The papules increase rapidly in number, and form either lines or bands, or cover, in a period of two or three months, large plaques of skin; they are especially thickly set, and contiguous in closely arranged lines or in large crowded areas, on the flexor surfaces of the extremities, especially the upper.

The skin of the affected areas is then uniformly red, thickened, and cracked. The surface is uneven, furrowed, feels dry, rough, and to the hand passing over it not unlike the surface of a nutmeg-grater. The crowding together of the papules in rows, with linear depressions or furrows between, gives it the appearance of shagreen leather, to which Hebra has aptly likened it.

The hairs become atrophic and fall out. The nails lose their brilliancy and become fragile. The palms and soles are the seats of markedly thickened, hardened epidermic accumulations, by which the mobility of the hands and fingers is compromised.

The patients, who from the beginning of the disease are troubled with severe itching night and day, grow very nervous and tend to become emaciated and much weakened. When the malady involves the face, the latter, in consequence of the rigidity of the thickened skin, is given a stiff, aged appearance. Among the first fourteen

cases first described by Hebra the disease ended fatally in thirteen. At present the prognosis of lichen ruber acuminatus is, however, in general to be considered as much more favorable, inasmuch as under the arsenical treatment inaugurated by Hebra the great majority of cases are cured, leaving atrophic grooves and stripe-like furrows. Nevertheless, malignant cases are still encountered. [The cases of pityriasis rubra (Devergie) as met with in this country, which this writer and many others consider identical with lichen ruber acuminatus, while often extensive, exist without any material influence upon the general health rarely end fatally, and seem uninfluenced by arsenical treatment.—Ed.]

Histologically the malady is characterized by abundant collections of cornified cells about the hair follicles, a considerable thickening of the stratum corneum with hypertrophy of the rete Malpighii, and inflammatory infiltration in the papillary layer (lichen exsudativus ruber, Hebra). In addition, the sebaceous glands are markedly hypertrophied, the sweat glands increased, and the arrectores pilorum materially enlarged (Riecke). The nature of the malady consists essentially of a marked hyperkeratosis.

The **pityriasis rubra pilaris** (Devergie) is, as already stated, scarcely to be divided from lichen ruber acuminatus. By many the milder course, the much less inflammatory character, as compared to the cornification, are cited as characteristic symptoms of the individuality of pityriasis rubra pilaris. These are, however, simply to be recognized as indicative of mere differences due to mildness or severity of the disease. Inasmuch as we are still in the dark as to the etiologic factors in both types, and it is a fact that the external symptoms of both are much alike, the question of identity is as yet still to be considered an open one. Kaposi, Neumann, Morris, Lang, Kreibich, all consider the two maladies identical; while among those holding to the individuality are Neisser, Jadassohn, Unna, and Tschlenow. The last named found by his histologic examinations [apparently of pityriasis rubra pilaris—Ed.]

primary disease of the epidermis with secondary inflammatory changes in the cutis, which by long duration could lead to atrophy. This author holds that the toxic origin of pityriasis rubra is the most probable.

Lichen ruber planus, or **lichen planus** (Plate 46), as it is usually termed, occurs much more frequently than lichen ruber acuminatus. In this variety the papules appear millet-seed- to hemp-seed-sized, and are elevated, flat, and waxy. At first limited to single regions, later the papules are found extending over larger areas or possibly over the entire surface. In the center of each lesion is a slight depression or umbilication. The earlier scattered lesions, by new accessions, gradually form band-like, linear, or dime- to dollar-sized, more elevated, dark-red plaques. Most lesions show firmly adherent whitish scales. The increase of the papules and the spread of the disease are seldom so rapid as with lichen ruber acuminatus. The groups remain longer stationary. The involution of the papules begins in the middle, the center of the patch or plaque becoming brownish in color, while on the border fresh bright-red lesions continue to appear.

The substratum of the process consists of an inflammatory infiltration in the corium and papillary layer, which leads to the above changes in the epidermis.

According to the degree of hyperemia, and sometimes also to increase in the exudation, depend the clinical appearances. Whether, however, such varying conditions are ever sufficiently marked to influence or change completely the ordinary picture of lichen is very questionable; at all events the appearance of vesicles, for example, as has exceptionally been reported, is not a part of this disease. It is probable, and as Lesser rightly says, that such unusual manifestations are accidental and due to the arsenic administered.

In the beginning the lesions are millet-seed-sized; but they may become hemp-seed- or even pea-sized, and, according to their grouping, may present various pictures upon the skin. For instance, we may meet with diffused,

red, slightly scaly patches on the extremities, and near by or on the trunk scattered papules. Sometimes the lesions form in bands or branches or garland-like rows (*lichen moniliformis*), arranged apparently along nerve tracts, a fact that has given ground for the belief in some such relationship (Blaschko).

On the palms and soles the disease causes thickening of the epidermis (*tylosis palmaris et plantaris*), and gives rise to the consequences of such accumulations—fissuring, loss of mobility, etc.

The mucous membrane of the cheeks and tongue may share in the process. We meet with such as epithelial accumulations in the form of white, irregularly shaped plaques with red, hyperemic edges. Owing to the possibility of mistaking it with other processes—syphilis, for example—it is to be remembered that the disease may also appear on the genitalia. The dark-brown pigmentation, surrounded by fresh papules, the troublesome itching, and the duration of the process sufficiently characterize lichen.

The disease appears in the adult, mostly in well-nourished individuals. It is neither inherited nor contagious. Its pathogenesis is as yet wholly unknown. Other skin diseases, as, for example, eczema may occur at the same time, and are sometimes produced indirectly by the lichen, by the attempts to gain relief from the itching by rubbing and scratching. The course is protracted, but not so active or tempestuous as in lichen ruber acuminatus. In this eruption (lichen planus) there is rarely ever febrile action in the acute stage. In how far both processes differ from one another, we are not in position to say. Histologic investigations give no conclusion, the slight differences found are not sufficiently characteristic, and, moreover, we have observed cases in which both forms existed alongside of each other.

The very troublesome itching gives rise to various discomforts, as unrest by day and loss of sleep by night; the appetite is lessened, and when no relief is obtained the

nutrition suffers. The patients lose their power of resistance and frequently become the subjects of intercurrent disease.

The **diagnosis** of lichen planus is, if a careful consideration of the above-described symptoms is given, and no other skin disease temporarily masks the symptoms, not difficult.

Many forms of psoriasis, especially when accompanied by itching, may occasionally give rise to some confusion in the diagnosis. The more frequent occurrence, the greater participation of the extensor surfaces of the elbows and knees, the less infiltration of the skin, and the loosely adherent silvery-white scales, and the bleeding from the papillary vessels, readily produced by scratching off the scales, speak for psoriasis.

Eczema squamosum will usually yield a history of preexisting vesicles, and eventually in its course fresh outbreaks of similar lesions point to this disease. Pityriasis rubra (Hebra) is distinguished from lichen planus by the absence of infiltration, and also by the thin atrophic skin. Arsenical hyperkeratosis is readily excluded by the history.

The so-called psoriasis syphiliticus—papulosquamous syphiloderm—and the mucous patches (resembling somewhat the mouth patches of lichen) of syphilis are associated with other characteristic symptoms of this disease. The mucous patches have not the characteristic red edge of lichen-planus plaques. Orbicular papules of a syphilitic character about the genitalia, which bear resemblance to those of lichen ruber planus, are usually found with a history of syphilis and other symptoms of that disorder, such as plaques on the mucous membranes, hair loss, glandular swellings, etc. In addition, these syphilitic papules are seldom dry as are those of lichen planus.

Treatment.—The itching is to be treated by local douches, baths, and alcoholic lotions of carbolic acid, salicylic acid, menthol, etc. Lassar touches the efflorescences with the galvanocautery. To promote involution of the lesions Unna advises:

℞ Ungt. zinci benzoinat., 30 (℥j);
Acidi carbolici, 1.25 (gr. xx);
Hydrargyri chlorid.
corros., 0.03–0.3 (gr. ss–gr. v).—M.
Ft. unguentum.

Or

℞ Acidi carbolici, 5–10 (gr. lxxv–℥iiss);
Hydrargyri chlorid.
corros., 1–5 (gr. xv–gr. lxxv);
Creosoti, 2 (gr. xxx);
Collodii, 50 (f℥xiiss).—M.
Sig.—Apply with a brush. Use with caution.

Arsenic internally, as in lichen ruber acuminatus, is also valuable.

The other recommended remedies, as potassium chlorate (W. Boeck), asafetida and mercurials (T. Fox), do not seem to have any appreciable influence upon the disease.

LICHEN SCROFULOSORUM.

This disease is met with in young individuals, especially between the ages of fourteen and twenty. The skin of the extremities or the trunk is beset with grayish rough papules, which occur in groups or scattered over large surfaces. It is without subjective symptoms, and the patients, therefore, often carry the rough patches until their attention is called to them accidentally. The affected skin is rough and greasy to the touch, and in places almost smeary; never so dry as in ichthyosis and chronic eczema. The seat of the papules is in the follicles and the perifollicular tissue. The epidermic plugs protruding from the follicles of the sebaceous glands often contain a hair or are covered with small thin scales which may be easily brushed off. Not seldom, especially in badly nourished and run-down individuals, the papules are brownish from the admixture of blood-pigment; often,

however, particularly on the lower extremities, they may be bluish red or even brownish red (*lichen lividus*).

If inflammation of the follicle and the perifollicular tissue is associated with the papule-formation, acne-like pustules result (acne cachecticorum), which are to be looked upon as a higher developmental stage of lichen scrofulosorum lesions. The latter holds a close relationship to those affections of the skin due to the tubercle bacillus or its toxins, and commonly is described under the general group of tuberculides. That lichen scrofulosorum stands in some etiologic relationship to tuberculosis was suspected by Hebra himself, as the name given to the affection indicates. The malady is, as mentioned, met with only in pale, poorly nourished individuals, associated with scrofulous swelling of the glands in the submaxillary region, in the neck, or with purulent fistulæ from broken-down glands. Sometimes lichen scrofulosorum is found in an individual having lupus vulgaris; as, for example, lupus on the forearm, upper arm, and lichen papules on the trunk. Impoverished circumstances, faulty care, and want of cleanliness often lead to the development of other skin diseases, such as eczema about the suppurating fistulæ, or in the neighborhood of the eyelids from conjunctivitis lymphatica; further, to pustules, ecthyma, and furuncles. All these maladies are, however, not a necessary part of lichen scrofulosorum. The histologic investigations by Riehl, Lukasiewicz, Porges, and others disclosed true tubercles (round cells, epithelioid cells, giant cells); the tubercles are always connected with the follicles. Porges observed an eruption resembling lichen scrofulosorum follow an infection of tuberculin.

The serum reaction as diagnostic help is, unfortunately, as unreliable in this affection and other tuberculides as in the diagnosis of early tuberculosis of the internal organs.

Treatment.—The chief consideration is the general treatment, which has for its object improving the nutrition with tonics, such as iron, arsenic, cod-liver oil with phosphorus, iodin, change of scene, etc. Locally, according

to the practice of Vidal and Hebra, the affected areas are rubbed with cod-liver oil.

ECZEMA.

This widespread and therefore important disease is an inflammatory affection of the skin accompanied by the subjective symptoms of itching and burning. Many different clinical pictures are presented in eczema, so much so that formerly these several varieties or manifestations were considered different diseases; Hebra proved, however, that the various phases and clinical pictures really expressed but one disease. Unna defines all forms of eczema as "chronic itching and scaly parasitic diseases of the epidermis, having a tendency to diffuseness, and in which there is an inherent disposition to react against irritation with the formation of serofibrinous exudation (moist varieties), or with epithelial proliferation, or with excessive cornification, abnormal fat-production or a combination of the latter (dry varieties)." The eczematously diseased skin reacts also in many protean ways to the widely different internal and external irritants. The disease may be acute or chronic.

Acute eczema (Plate 49) begins with the appearance of irregularly scattered red papules (*eczema papulosum*), which give rise to troublesome itching. The papules may retrogress, the redness disappearing and a superficial epidermal exfoliation taking place. Frequently, however, through intensity of the inflammatory process, these lesions change rapidly into vesicles (*eczema vesiculosum*) (Plates 47 and 48).

If the intensity of the process continues, there arise numerous millet-seed-sized to lentil-sized vesicles and small blebs (the latter rarely). In the beginning or earliest stages these lesions have serous contents, which soon, from the admixture of cell-elements, become milky and even purulent (*eczema pustulosum*). The overlying epidermis is either broken by scratching or is rubbed off, and the red surface exudes a liquid secretion.

Sometimes the lesions dry to yellowish crusts, which, when mixed with blood, which sometimes exudes from the hyperemic rete or results from scratching, give rise to brownish or even blackish crusts (*eczema crustosum*) (Plates 50 and 51). Very rarely, and then only as a consequence of violent scratching, is any loss of substance noticed beneath the crusts, so that when the process has run its course and healing has taken place by a regeneration of the epidermis, no scarring remains.

Frequently, also, acute eczema appears as a diffused redness and swelling (*eczema erythematosum*). In many of these cases, on passing the finger over such affected areas, one may be able to detect slight, scarcely perceptible elevations or irregularities, from which vesicles may develop.

The patient first feels a sensation of tenseness in the affected areas, which soon changes to intense burning and itching. The vesicles become confluent, new outbreaks rapidly taking place; the part is soon deprived of its epiderm, and there appears a reddened, oozing surface, the base of which consists of the rete Malpighii and papillary layer. The profuse secretion mixes with the epidermic cast-off cells and becomes thereby thicker and more smeary (*eczema madidans, eczema rubrum*) (Plates 54 and 55). If the affected areas are not confluent, or if the intensity of the process and the consequent secretion subside, the parts become covered with extensive yellowish translucent lamellæ, which crack, and through such fissures underlying collected liquid oozes out.

If the hyperemia, and with it the swelling, subside, the secretion likewise correspondingly lessens; the epidermis begins to reform, and the epidermic cells lie upon the still reddened, infiltrated skin as loosely attached scales (*eczema squamosum*). This scaly condition may persist for some time or rapidly disappear, and a normal condition be reëstablished.

As already stated, all stages of acute eczema may pass directly and rapidly to cure. More frequently, however,

we observe that the papular or vesicular stages change into the squamous stage or variety. Often we meet with a squamous type on one part of the body, on another a crusted form; this is especially noticeable in universal eczema and in recurrent or relapsing forms.

As a peculiarity of eczema, it may be mentioned that often a long-continued mild eczema, to which the patient gives but little thought, without recognizable cause develops into acute eczema on distant situations. Many authors (Kaposi) look upon such as due to vasomotor neurosis. Czillag has lately, upon the basis of his experiments with chemic irritating substances (tincture of arnica, iodoform, mercurial salves, etc.), denied the possibility of a so-called reflex eczema, and is of the opinion that in such cases there is always a conveyance of the irritating material, if only in minute quantity, to which the so-called reflex eczema areas are due. On the contrary, however, Kromayer rightly alleges that nevertheless in these places there must exist a heightened sensitiveness to irritation, which can be considered as due to trophic nervous influence. Many individuals have at certain seasons of the year an unmistakable disposition to eczema, and even after freedom for a number of years the old trouble returns.

Acute eczema, fortunately, is rarely encountered as a generalized disease; but it produces a severe, sometimes dangerous, condition when it involves the whole surface in various degrees of severity. Some parts of the body, as the face, the genitalia, and the hands, are markedly swollen, and the patients experience tension, burning, and itching, which, with the accompanying fever and systemic disturbance, are very troublesome. The clothing adheres to the oozing places and causes further irritation; the patients find no relief or rest and lose sleep. They complain of weakness, loss of appetite, and frequently chilliness; and these conditions, together with imperfect nourishment and by loss of the blood-plasma, may lead to a critical issue. [Such extreme cases must, however, be rare,

and it is even questionable in those instances whether the disease is not complicated or other than eczematous.—Ed.]

The duration of universal eczema is uncertain, since after subsidence of the acute stage it only partly disappears, remaining on several parts as chronic eczema.

Of the localized forms of acute eczema, the most frequent is eczema of the hands (Plate 52), these parts being the most exposed to external irritating agencies. It appears with swelling of the back of the hand and fingers, which sometimes extends up the forearm. The hard and thick epidermis of the palms is slowly cast off. Frequently painful fissures (rhagades) arise, and sometimes the surface around the nails becomes raw-looking, with at times granulation-tissue formation, so that for a considerable time the patient is unfitted for using the hands. The same appearances and conditions obtain with acute eczema about the feet, only on these parts the disease is much less common.

The face is a frequent site for acute eczema (Plate 49). Marked swelling of the eyelids, cheeks, nose, lips, and even the ears is noted, and gives rise to a feeling of tenseness. Not infrequently eczema of this part is mistaken for erysipelas faciei. This latter, however, is wanting in papules, vesicles, and pustules, and consists of a diffused firm infiltration, usually with sharply defined borders, with tenderness and continued high fever. It is, unfortunately, seldom that the eruption on all parts in acute eczema of the face so completely disappears that there is but slight prospect of recurrence or relapse; the simultaneous involvement of the ear lobes with the face is especially unfavorable for such outlook. An uncomfortable result or consequence of acute eczema is the dryness and brittleness of the skin, which in spite of apparent cure remain and give rise apparently to recurrence.

Acute eczema of the genitalia occurs more frequently in men, and is accompanied by great edema and swelling of the penis and scrotum. It begins with a feeling of weight

and tenseness, and obliges the patient to seek rest in the recumbent posture. Soon the skin of the affected parts becomes inflamed and fissured; there is also abundant oozing, which adds to the patient's discomfort, inasmuch as crusts form, which crack or are more or less torn by the scratching and rubbing and cause painful burning. In women the disease usually first affects the labia, and then rapidly involves the genitocrural folds, and sometimes spreads down the thighs.

Eczema intertrigo is not uncommon, and may involve considerable surface; it is accompanied with a scanty secretion and with constant casting off of the epidermic cells, which together constitute a greasy covering over the reddened corium. The process is most frequently observed on contiguous surfaces, as the anal fold, under the breasts, in the flexures of the legs and arms, and in many other regions in fat children and corpulent adults.

Chronic Eczema.—Morphologically, chronic eczema is but slightly different from acute eczema. Clinically, however, there are many points of difference in the course of the affection which distinguish the chronic process from the acute. Chronic eczema arises either in the wake of a rapid incomplete involution of the acute disease, as already stated, or an acute eczema gradually becomes less and less marked and passes almost imperceptibly into the chronic process.

The chief forms of chronic eczema are the oozing (*eczema madidans*, *eczema rubrum*) and the scaly types. Although sometimes papules and vesicles of a markedly inflammatory character may be noted from time to time, the chronic type is characterized essentially by persistence, frequent recurrences, obstinacy, and rebelliousness. To these characteristics may also be added consecutive changes which are brought about by the chronic disease: Brittleness and vulnerability of the skin, disposition to branny scaliness, scurfiness, and finally the painful fissures which usually appear in the flexures and about the joints. As a further result of the chronic disease may be

mentioned an increase in the pigmentation of the affected regions, sometimes thickening of the epidermis, thickening of the corium, and increased connective-tissue growth. These latter may under certain circumstances, especially when involving the lower leg, almost approach an elephantiasic condition in appearance. Finally it may bring about degeneration of the follicle and hair-loss.

Among the subjective symptoms stands, first of all, the intense itching, which is the source of so great distress to patients that they continually rub and scratch, both when clad and unclad.

It is rare that chronic eczema involves the entire surface; as a rule, only certain parts are predisposed to it. There are several places of predilection:

Chronic pustular eczema of the scalp is frequently associated with eczema of the ear muscles and the face. The scalp is covered with broken-up yellowish or yellowish-green, frequently brownish, crusts. Here and there in the hair are found cast-off or rubbed-off fragments of crusts, and in some cases also lice and nits. On removing the crusts from the underlying skin the latter is seen to be red, oozing, and deprived of its epidermal covering. The hairs become matted or project irregularly through the crusts. This condition is not infrequently seen in women and children as a result of pediculosis capitis. These parasites may be primary (the eczema resulting) or they may be secondary. The children have, moreover, frequently swelling of the cervical glands, which the mother is apt to look upon as scrofulous. If this condition of pediculosis is neglected, and to it added extraneous dirt and filth, the hairs become tangled in masses or into long, thin bunches (*plica Polonica*).

Chronic eczema of the face seldom involves this whole region; usually only certain parts, such as the mouth, lips, ears, eyebrows, and eyelids.

A special variety of eczema of the face is observed in infants, in which the face and ears are covered with crusts (*crusta lactea*). The ears, cheeks, and brow are

most commonly the seat of this troublesome and itchy affection.

Eczema of the lips, which often occurs in association with eczema of the nose, leads to thickening of the border, and often of the entire lip, with fissuring of the vermilion; even after complete healing of the lesions the lips may remain permanently enlarged, with linear cicatricial or atrophic furrows. Unna refers to those uncommon cases where in lupus of the face the lupus picture is made much worse by the addition of an eczema of a fatty, crusty nature, but between which there is necessarily no interdependent connection.

Eczema of the genitalia and anal furrow leads to many consequences, brought about by the itching and scratching: Thickening of the skin, growth of the chronically inflamed furrows, etc.

It remains to mention eczema of the flexures of the extremities, of the nipples, of the mammæ, and of the navel, which presents symptoms in no respect different from the disease in other parts. The eczema of the breast is, however, of peculiar importance, as, according to the opinions of many authors, a long-continued eczema of this part may lead to the development of carcinoma (Paget's disease), a belief which has been disproved by Matzenauer (and others), who, in his histologic findings, could readily demonstrate a clearly defined division of the two processes.

The occupation of many individuals provokes *eczema of the hands*, fingers, and even the finger-nails (trade eczemas). These eruptions are not only characterized by vesicles and pustules, but the epidermis of the palms and of the fingers is thickened, brittle, and fissured, so that the many places deprived of their epidermis render it painful for the patient to work. A similar condition of affairs, in somewhat less degree, occurs also on the feet.

In conclusion, we will make mention of *eczema marginatum* (Hebra) as a special form of eczema. It appears in palm-sized areas, confluent circles and ellipses, which

show vesicles on their borders; the central parts being either covered with scabs and scales, or, if of long duration, showing a somewhat dark-pigmented skin. The sites chiefly affected are the inner thighs and the genitalia. A variety in its beginning or early stage is shown in Plate 53. [This is again referred to under the head of Ringworm.—Ed.]

The so-called *eczema seborrhoicum*, owing to its seborrheic nature, has already been referred to in the consideration of the Disorders of the Sebaceous Glands.

According to Unna's histologic investigations, eczema is characterized by a superficial dermatitis, increase in the connective-tissue cells, and dilatation of the blood- and lymph vessels; further, a parakeratosis of the epidermis, which Unna defines as an edema of the transition epithelia. There exists an interstitial edema of the prickle layer (spongy transformation of the epithelium).

Diagnosis of Eczema.—When the symptoms are considered, it will be seen that acute eczema is scarcely to be confounded with any other skin disease; at the most, the acute face eczema with erysipelas, already mentioned, the differential points of which have been pointed out.

Chronic eczema, on the contrary, may, when of long duration and from its tendency to scaliness, be confounded with psoriasis and with lichen ruber planus. It is to be remembered that chronic eczema often has its beginning in the acute type—that is, there is an entirely different history from that of the other diseases named; and that on one or more regions outbreaks of an acute character may occur from time to time which are quite diagnostic. Eczema is, moreover, chiefly an affection of the epidermis and rete, and is distinguished from psoriasis in that it does not appear in numerous uniform plaques, as does the latter. In lichen planus the papules arise from infiltration of the skin, with less scaliness in disappearing, and never present an oozing surface. The subjective symptom—namely, itching—occurs always in eczema, seldom in psoriasis, but frequently, however, in lichen.

Prurigo, ichthyosis, lupus erythematosus, tinea tonsurans and circinata, and favus can scarcely be confounded with eczema. On the other hand, however, a combination of one or several of these diseases with eczema is not a rarity.

The **causes** are divided into two classes: One comprises those cases in which the disease seems to have been excited by external irritants—external causes; the other, those cases which have been called forth by some general disturbance of the whole organism—internal causes—symptomatic eczema.

By far the more frequent are the first named—mechanical, thermal, and chemic irritation. By eczema due to mechanical irritants we mean those cases brought about by pressure or rubbing, especially if the skin had been previously subjected to heat or irritated in any way. In such instance the constant rubbing of the clothing and the pressure and irritation of bandages suffice to call forth mild forms of the disease. In this connection also should be mentioned those diseases in which itching is a prominent symptom, and necessarily gives rise to rubbing and scratching, and resulting eczema: Lousiness, scabies, prurigo, pruritus cutaneus, urticaria, lichen ruber, ichthyosis, and pemphigus pruriginosus. Among the mechanical causes belong also circulatory sluggishness or congestion due to varicose veins in the lower extremities, especially the lower part of the leg, and sometimes the scrotum. The itching induced by the congestion or blood-stagnation causes the patient to rub and scratch. The epidermis, thinned by frequent hemorrhage or by exudation in the cutis, is easily injured. The repeated eczematous outbreaks give rise to new inflammations and changes; the subcutaneous tissue grows, is thickened; the blood- and lymph vessels are in part dilated, partly new formation; many anastomoses of these (varicosities) arise anew; the connective tissue immediately surrounding these becomes thickened and increases; with time it becomes still more marked,

more or less sclerosed; the affected part increases in volume, and we have the picture of elephantiasis.

Thermal irritation, as, for example, in boilermakers, often leads to diffused inflammatory disturbances either of the hands, face, or breast region (*eczema caloricum*), in which there is marked vesicle and bleb formation. The heat of the sun (*eczema solare*), as, for example, in rowers and bathers, calls forth, for the most part, papular eczemas.

Frequently we see in long-continued sweating a minute papular or vesicular eruption (*eczema sudamen*). The profuse sweat secretion collects either in the ducts of the sweat glands, lifting up the epidermis, or, also in addition to this, by serous oozing out of the papillary vessels and collecting in the epidermic layer. The rubbing of the clothing or the rubbing and maceration of contiguous surfaces add to the condition and lead, in the further course of the disease, often to true eczema.

Finally, as to the numerous chemic irritants, as, for example, arnica tincture, which is a popular remedy for wounds and injuries; the resins, as turpentine, a constituent of various plasters, and which is also used by many persons in their work, as painters, printers; many medicinal substances, as croton oil, cantharides, mustard, iodoform, sulphur, carbolic acid, corrosive sublimate, old mercurial salves, potash solutions, lye, soaps (owing to the excess of free alkali), particularly in washerwomen; and macerating poultices of cold water, or as a result of cold-water cures (the cutaneous irritations formerly looked upon as "critical" eruptions)—these all provoke in some individuals an eczematous eruption.

The symptomatic eczemas result from various diseases which involve the organism and engender in the skin a state of irritation or vulnerability. It is especially in those general states of the health which bring about depressed nutrition and reduce the individual power of resistance that the skin is responsive to the slightest irritation. In this class belong scrofulosis, rachitis, diabetes, gout, excessive corpulence, and the various anemic and dyspeptic

conditions which especially dispose the peripheral parts of the body (head, hands) temporarily to eczematous outbreaks. That eczema may arise from conditions of the nourishment furnished, and the reverse is proved by the interesting observation by Heubel: an infant, presenting a weeping eczema, was being given the milk from a cow that was fed with feed highly salted; a change of the milk was followed by rapid subsidence of the eczema.

Eczema may also arise in consequence of an injury to a nerve, and can appear in strip- or band-like configuration corresponding to the distribution of the injured nerve, and can be associated with disturbances of sensation (Bettmann, Orlipski).

Course and Prognosis.—Concerning the course of acute eczema there is but little to say. The slight, localized acute forms disappear in two to four weeks. On the contrary, generalized acute eczema terminates for the most part, at least in certain regions, in the chronic form.

The course of the chronic form depends upon the causes which have provoked the disease and upon the changes which have been brought about by it, such as thickening of the skin, fissures, etc. Chronic eczema is not infrequently associated with furunculosis, the latter dependent, doubtless, upon the scratching and the consequent ready inoculation by the cocci. The fact that eczema may last for years without in any way leading to a septic affection speaks against any etiologic relationship of eczema with sepsis, and therefore also with furunculosis (Unna).

As troublesome and obstinate as eczema is, nevertheless one can say, in general, to the patient that recovery is probable. If the cause disappears or is modified, or if the patient avoids the exciting factors, very often slight local therapy will suffice to remove the disease.

Eczema heals without leaving any traces worthy of mention; at the most, here and there some slight pigmentation or insignificant thickening of the skin. As it is *par excellence* a disease of the epidermal layer, no scarring, even in the pustular form of the disease, is left; and

should such be observed, is due to accidental causes. Syphilitics, in order to conceal the fact that they have had syphilis, occasionally state that they have suffered from eczema which had been preceded by nerve or organic disease; such a statement, however, is not to be believed if an examination discloses scar-formation occurring in groups and pointing to a preëxisting syphilitic manifestation which had disappeared spontaneously or as the result of treatment. It is true that sometimes eczema is present conjointly with a syphilide, giving the latter a brighter red color, and a predominant seborrheic character, making the former more rebellious to antisyphilitic treatment.

Internal Treatment.—Especially by the French writers, in all cases of acute and chronic eczema, extensive dietetic directions and a number of internal remedies are recommended. Up to the present, however, proof is wanting that all cases are in reality dependent upon constitutional causes, diathesis, etc.; the probabilities, on the contrary, are rather against such acceptance. The constitutional treatment will therefore be limited to those cases in which there is some disease or functional disturbance of some other organ, as the possibility of some connection between the skin disease and such may exist. A persistent anemia is to be treated by appropriate remedies; and in cases of diabetes, nephritis, uric acid diathesis, oxaluria, the proper dietetic directions should be given and alkalies, diuretics, etc., ordered. It must be admitted that better results are to be obtained when attention is also given to the general health than when treatment is directed to the skin alone. In fact, for successful treatment each individual case demands careful study.

External Treatment.—(*a*) Acute Eczema.—In eczema intertrigo and papulosum, dusting powders, such as starch, talc, or this combination:

℞ Amyli oryzæ, 100 (℥iij);
Zinci oxidi,
Pulv. iridis florent., ā ā 5 (gr. lxxv).—M.

Sig.—Dusting powder.

When the inflammatory symptoms are of high grade ice-cold poultices, aluminum acetate, poultices of 2 per cent. resorcin solution, 2 to 5 per cent. tumenol solutions (Neisser), and similar applications are to be recommended.

If itching is troublesome, it can be moderated or controlled by applications of alcoholic solutions ($\frac{1}{2}$–2 per cent.) of carbolic acid, salicylic acid, with subsequent powdering, and finally with weak tar applications. Most authors advise against the application of tar so long as oozing is present; but Lassar, on the contrary, sees no contra-indication to its employment in such cases.

In the crusted stage or forms of the disease the softening salves and oils are especially useful, especially that sovereign remedy, the unguentum diachyli Hebræ. In persistent scaly forms salves applied as plasters, such as vaselin, unguent. aquæ rosæ, unguent. zinci oxidi, unguent. Wilsoni, Lassar's paste, unguent. cascini, with or without other medication, and cooling salves (Unna):

℞ Lanolini, 10 (ʒiiss);
Adipis benzoinat., 20 (ʒv);
Aquæ rosæ, 30 (ʒviiss).—M.
Ft. unguentum.

(*b*) **Chronic Eczema.**—In addition to the various local remedies mentioned above are to be commended softening salves, salicylated soap plasters, and rubber fabric. In those cases of considerable thickening and epidermic accumulation in which tar fails to soften and relieve, strengthen the tar by the addition of sapo viridis (equal parts) and carbolic acid.

In many chronic, thickened eczema cases very useful are β-naphthol salve, pyrogallic-acid salve, chrysarobin salve (1:10–1:50 vaselin); and cauterizations with caustic-potash solutions of varying proportions, 10 to 50 per cent., which Spiegler follows up with an application of silver nitrate (25 per cent. aqueous solution). The several reducing remedies can be prescribed in combination, as follows:

℞ Chrysarobin,
Pyrogalloli,
Resorcin,
Acid. salicylici, āā 2.5 (gr. xl);
Ichthyol, 10 (ʒiiss);
Vaselin, 80 (ʒii ʒv).—M.
Unguentum reducens (Unna).

PRURIGO.

Prurigo (Plate 56) is a chronic and extremely troublesome disease, persisting, by frequent and repeated recurrences and relapses or continuously with exacerbations, throughout life. The accidental secondary lesions of the skin are more conspicuous than its own pathologic products. The disease begins in childhood, in the first or second year of life, with outbreaks of intensely itching hives. The wheals and scratch marks may be made to disappear by means of baths and care of the skin; but soon recur. The wheals repeatedly make their appearance, finally resulting in the formation of papules. These are pinhead in size, pale or pale red, and itch intensely, so that they are not infrequently observed covered with blood-crusts. Their sites of predilection are the extensor aspect of the lower leg, the thighs, the sacral and gluteal regions, and the extensor surface of the arms, both upper and lower parts. These prurigo papules are scarcely elevated above the level of the skin; only by persistent rubbing do they become prominent. When scratched open they become depressed and a blood-crust marks the site; this disappears and leaves a white scar or speck. The flexures of the knees, groins, and elbows, likewise the face, are usually uninvolved, and are soft, white, and moist, so long at least as they remain free from eczematous manifestations, which in severe cases are often associated or result from the persistent irritation and scratching.

The milder grade of prurigo is often without striking

or urgent subjective annoyances, in consequence of which it may lack the resulting secondary phenomena. This type may, by frequent baths and great care of the skin, in individuals favorably circumstanced, be kept stationary and eventually cured. In many such cases outbreaks are often limited to the lower leg and thigh, and at the most appear only in winter and for a short time.

These milder types of the disease are usually designated *prurigo mitis*, in contradistinction to the severe forms—*prurigo agria* or *prurigo ferox*. In the latter variety of the disease the outbreaks of prurigo papules are so numerous and the consequent itching so intense that the patient is obliged to be constantly rubbing and scratching. The skin becomes covered with roundish and linear, brownish, dry blood-crusts, which may be surrounded by an inflamed red or purulent areola. Near by are also to be seen recent red or older white scars. Owing to the repeated cutaneous outbreaks, and the resulting hyperemia and persistent scratching in trying to obtain relief, the skin becomes more or less pigmented, is noted to be hard, rough, and board-like, and can scarcely be lifted in folds. In severe cases the lanugo hairs are wanting, or here and there are broken off or pulled out by the constant scratching. Especially about the knees and ankle joints the skin is thickened and shows deep furrows. The intense irritation of the skin, added to by the constant scratching, produces infection and leads to chronic inflammation of the lymphatic glands, more particularly of the femoral, inguinal, and axillary glands. The patients are troubled night and day by the itching, look pale and badly nourished, and are often looked upon by their associates as suspiciously scabietic and are avoided.

This disease disposes the affected individual to eczema, which may attack the few free places in the flexures of the joints and on the face. Besides, pustules and ecthymata on the extremities are not uncommon complications or additions.

Histologically, according to Riehl, Neisser, and others,

the prurigo papules represent small urticarial papules; one finds a diffuse edematous saturation of the connective tissue in the papillary body, dilatation of the lymph- and blood-vessels, and small-celled infiltration about the subpapillary vessels.

The **diagnosis** of prurigo, when the disease is not complicated or masked by a coexisting eczema or scabies, is not difficult, the characteristic symptoms already described, the localities affected, and its course furnishing sufficiently characteristic points; excepting from this statement the earliest stages, when the disease usually presents solely urticarial symptoms. At this time the possibility of the malady being strophulus infantilis (lichen urticatus, urticaria papulosa) cannot be entirely excluded, and it is only after the second year of life that the characteristic features of prurigo are clearly developed.

The etiology of the disease is unknown. While Hebra attributed it to a tuberculosis in the mother, in later times the trend has been to consider it due to heredity and to nervous influences (neurodermitis, Brocq). As also with erythema multiforme prurigo has also been ascribed to an auto-intoxication having its origin in the alimentary tract, and this seems the more likely, especially as such children are frequently the subjects of digestive disturbances.

As already intimated, the prognosis in prurigo agria is very unfavorable. In reports of alleged cures in the milder forms of the malady the suspicion that these may have been cases of lichen urticatus cannot be entirely excluded.

Treatment.—Prurigo patients are, as a rule, weakly, and are slow in development and ill-nourished, and for these reasons an effort should be made to build up the general health. Internal medication (carbolic acid, menthol) is without direct effect on the skin; but as supporting and alterative remedies may be mentioned cod-liver oil, alone or with iodin (iodin, 0.10 (gr. iss); cod-liver oil, 100 (℥iij), one or two teaspoonfuls, t. d.), and phosphorus, as in the following:

℞ Ol. morrhuæ, 30 (f℥j);
Phosphori, 0.01 (gr. $\frac{3}{20}$);
Acaciæ,
Sacchar. alb., āā 15 (℥ss);
Aq. dest., 40 (f℥j ℥ij).—M.
Sig.—One to four teaspoonfuls, t. d.

Of external applications, tar deserves most prominent mention, applied thoroughly; sulphur (Vleminckx's solution (liquor calc. sulphuratæ), sulphur salves); Wilkinson's ointment (a course of ten to twelve rubbings); β-naphthol (5 per cent. salve in courses of four rubbings, and after each course a bath). In addition, sweat baths (hot baths followed by hot pack); subcutaneous injections of pilocarpin, 0.01 (gr. $\frac{3}{20}$) each dose; internally jaborandi leaves as infusion, 4 : 100; and sulphur baths.

Murray and Hatschek recommend massage of the affected skin, which is said to have a remarkably favorable influence upon the itching.

STROPHULUS (LICHEN URTICATUS; URTICARIA PAPULOSA).

By this affection we mean an affection of the skin chiefly occurring in children, and characterized by the appearance of shot-sized, intensely itchy papules, which are to be seen principally on the same predilection parts as prurigo; in contradistinction to prurigo, however, inside of some months at the most they have entirely healed. As it is, moreover, somewhat less itchy than prurigo the scratching effects are less intensely marked, and decided glandular swelling is wanting in most of the cases.

While Kaposi considered strophulus a variety of the papular form of erythema multiforme, other authors, as Riehl, Neisser, and others, have contended for the relationship to prurigo, recognizing between the two only graded differences; likewise has the usual urticaria infantilis as a preliminary stage of strophulus been entertained. Strophulus is only met with rarely in adults, most frequently in

children at the time of dentition. The latter is, however, certainly not to be looked upon as the cause. Etiologically the same influences as mentioned in connection with prurigo are true here also, probably autotoxic influences; these latter, according to Blaschko, giving rise to a faulty innervation of the blood-vessels of the skin.

The **treatment** has first of all in view a regulation of the diet, placing the children upon least possible irritating food. Internal medicaments seem to have but little influence, although many authors speak well of such remedies as bismuth carbonate with magnesia carbonica, antipyrin, etc. Externally sulphur baths especially, and the other applications employed in urticaria, are variously prescribed.

NEUROSES.

In the descriptions of some of the preceding diseases reference was made to the fact that they originated from or were influenced or modified by irritation of the nerves; diseases which might well be termed *trophoneuroses*. Inasmuch as great influence upon the nutritive processes of the skin must be through the vasomotor-nerve branches and the sympathetic plexus, the number of diseases believed to have a neuropathic etiology is gradually becoming greater and greater. Unfortunately, in the overwhelming majority of affections the manner of this nervous influence is not yet sufficiently fathomed, so that the more exact classifying of such diseases must be left to the future.

It is our purpose, however, to consider here the cases which belong strictly to the neurotic class, in which itching is the essential symptom; those disturbances of sensibility which are not associated with any external cause and without primary anatomic changes of the skin. This may be present in mild or severe degree.

Pruritus.—The extreme sensibility or irritability of the skin characterizes itself by itching—*pruritus cutaneus*, *pruritus*. This affection may occur as *pruritus universalis* or *pruritus localis*. The patient suffers from attacks of

violent itching of the skin, so extreme in its intensity that he cannot withstand the desire to rub and scratch, nor usually stop till the skin is reddened or excoriated, and some parts scratched opened and bleeding. The itching is usually then replaced by a feeling of burning, and the patient feels weak or exhausted by the effort and the suffering. The attacks are most common in the evening, especially when undressing, and through the night, so that often sleep is broken or fitful. The skin shows diffuse redness, or at the most urticarial wheals near the blood-crusted excoriations; it is frequently found dry, is seldom moist, and after long duration of the disease brownish colored. The sweat secretion is mostly limited to the joint flexures. In young individuals disturbances of digestion are noted, and in women disturbances of the sexual organs are often associated with the cutaneous affection. Mental emotions may also have an influence in promoting cutaneous pruritus. The itching generally increases as soon as the patient has once begun to scratch.

Of troublesome nature is the pruritus of those advanced in years—*pruritus cutaneus senilis*—which may persist to the end of life. Pruritus due to other causes than advanced age may be benefited and relieved; and even the pruritus of senility may often be ameliorated and occasionally temporarily or permanently controlled.

The diagnosis is not always possible upon first sight. One must carefully consider the various dermatoses of which pruritus may be a symptom; also the possible presence of parasites must be excluded.

Treatment.—In the treatment of pruritus the possibility that certain diseases may through noxious influence be causative must be considered: Diabetes, gout, stomach and intestinal disease, liver affections, and disease of the genito-urinary apparatus in women. If any one of these causes is found to be operative, then the treatment must be directed toward its removal; or, if this is not possible, then toward its modification.

The remedies, both internal and external, which have

been recommended for the treatment of this disease are very numerous. We name as the first in importance in the constitutional treatment, sodium salicylate; also, atropin, quinin, pilocarpin, tinctura gelsemii. Externally, baths and douches are recommended; in many cases a low temperature of the water, in others a high temperature, seems to be more valuable. Of the external remedies controlling the itching, which may be applied in lotions or salves, are the following: Carbolic acid, salicylic acid, ichthyol, naphthol, tar, chloral hydrate, camphor, menthol, thymol, etc.

The following prescriptions may be given:

℞ Chloral. hydrat.,
Camphoræ,
Acidi carbolici,
Glycerini, equal parts.—M.

Sig.—Apply morning and evening. Use with caution.

℞ Bromocolli solubil., 5–20 (gr. lxxv–ʒv);
Zinci oxidi,
Amyli, āā 20 (ʒv);
Glycerini, 30 (℥j);
Aq. destillat., q. s. ad. 100 (℥iiiss).—M.

The most frequent pruritus limited to a region is **pruritus pudendorum.** The external genitalia and frequently also the vulvæ (**pruritus vulvæ**) are attacked by intense itching, and the mechanical irritation produced by attempts to gain relief results in thickening, hypertrophy, and catarrhal affections of the mucous membrane.

In men, mostly in those of advancing years, the itching may be limited to the scrotum (**pruritus scroti**) and perineum, and leads quickly to eczema and the above-mentioned changes. Sometimes the urethral orifice, the urethra itself, and the anal crease are also affected. **Pruritus ani** is frequently associated with the various diseases of the rectum, as hemorrhoids, fissures, etc.

The nature of that variety of pruritus which presents, especially in the winter months—**pruritis hiemalis** (Duhring)—is not fully known.

Treatment.—In these various local forms of pruritus attention is always to be given to the possibility of its being due to the various diseases named (hemorrhoids, oxyuris vermicularis, fissures, endometritis, malpositions of the uterus, etc.). The remedies already mentioned in the treatment of general pruritus are also to be advised in the treatment of the local forms.

Anesthesia of the skin we have almost always observed circumscribed in character. It results from some disturbance of the nerve branches or from disturbance of the central nervous system. Two forms are recognized—one in which the anesthesia is to temperature and the other to the touch. Complete disappearance of the sensibility of extensive areas is sometimes noticed, as, for example, in lepra anæsthetica.

ANOMALIES OF THE EPIDERMIS.

In consequence of the pathologic accumulation of abnormally thick horny masses result the so-called hyperkeratoses. The epidermis is often produced in great quantity, and cast off either in small scales or larger lamellæ; or the horny layer cells hold abnormally firmly together, lack the regular usual exfoliation, and give rise to the formation of callosities and scales, and finally to cylindric or angular plates and spines and horns.

CALLOSITAS.

Callositas (*tyloma*, *callus*) is a thickening and hardening of the epidermic layers, which may become several millimeters thick. The form of these thickenings depends somewhat upon the character and extent of the pressure which has called them into existence. They arise from pressure, generally on those places where the underlying bones furnish a mechanical counter-support. The sensi-

bility in the part is more or less lost; and by continued action of the cause the underlying parts may become inflamed in the corium, and the mass is cast off with an undermining of serous and sometimes hemorrhagic exudation; especially painful, in consequence of long-continued pressure, are those callosities on the heels. In those callous accumulations which form on the flexures of the joints of the fingers painful cracks often result (Plate 61). The fissures in the calloused skin can be the starting-point of phlegmon and erysipelas.

CLAVUS.

Clavus, or corn, is a horny accumulation with a cone-shaped core or hard center, which is pressed into the cutis, the apex downward. The formation originally consists of concentric layers of cells heaped one upon the other, lies in a sweat-gland duct, and presses upon the cutis, and may thus cause disappearance of the underlying papillæ. At the base there is often to be found a mucous cyst, whose formation has resulted from the constant pressure. According to their consistence, corns are frequently divided into two varieties—the hard and the soft; the latter arises through maceration of the superficial horny layers, and can also be artificially produced with foot baths and salves. Repeatedly cases have been observed where operations upon corns with insufficiently cleaned instruments have resulted in grave infectious and septic processes.

Lewin has described a so-called clavi syphilitici, observed in syphilitic subjects, occurring upon the hands and feet, and appearing as horny formations covered with scales.

CORNU CUTANEUM.

Cornu cutaneum, or cutaneous horn, takes its origin from the surface of the skin, from apparently fibrous tissue, and is observed on the scalp, on the brow, and on the prepuce; more frequently in the female sex and in those

of advanced years. The horns are for the most part spiral and bent, wider at the base, and of a dirty-brown color.

Histologically two varieties of cutaneous horns can be distinguished—one in which there are strongly marked inflammatory changes in the cutis, and the other in which the changes in the cutis, except as to the hyperkeratosis of the stratum cornuem and the hypertrophy of the mucous layer, are less pronounced. The latter, when with less involvement of the cutis, forms the transition growth between it and warts, and gives rise to that formation described by Unna as fibrokeratoma; the other group shows resemblances to epithelioma.

Treatment consists in operative removal of the growth together with the underlying base.

VERRUCA.

Verruca, or *warts*, are flat, variously elevated, projecting growths of the skin; they are not sensitive and are seldom smooth, but mostly have a cleft, rugous, dark-gray surface. They consist of considerably enlarged papillæ and an increased and hardened epidermis.

The favorite sites are the hands and face, less frequently the hairy scalp; it is not uncommon for several to be in close proximity. It is rarely possible to assign a cause for their appearance; in some cases a persistent irritation of the skin seems a possible factor. They sooner or later disappear spontaneously; or new ones continue to appear, singly or more numerously. Sometimes they appear at the periphery of a group, the central, older growths undergoing involution, and in this manner forming irregularly circular areas.

Ordinarily, warts are merely a disfigurement and occasion no discomfort; but they may become torn and sometimes fissured, and in this way give rise to various infection possibilities.

Treatment.—Warts are removed with the sharp curet or curved scissors, and subsequent cauterization of the

base with nitric acid, chromic acid, liquor ferri sesquichloridi, or glacial acetic acid. The growths may also be removed by the thermocautery or by electrolysis.

ICHTHYOSIS (FISH-SKIN DISEASE).

Ichthyosis is a disease chiefly of the epidermis, dependent upon hereditary disposition. It develops early in life, mostly in the second year. According to the type or degree of the disease, several varieties are encountered.

Ichthyosis simplex is observed chiefly on the extensor surfaces of the extremities; but may also appear upon the trunk. The surface of the skin feels rough, and the small papular—follicular—elevations are covered with firmly adherent scales, upon the removal of which the surface hairs are observed. This mild type causes the patient very little annoyance.

A more marked type of the disease is the so-called *ichthyosis serpentina*, which is characterized by dirty-brown, horny scales and scaly plates on the surface of the trunk and extremities. Over the elbows and knees the condition is often distinctly papillomatous or warty in appearance. The skin of the face is also dry, scaly, and grayish (Plate 59).

The most pronounced grade of ichthyosis is the so-called *ichthyosis hystrix*, in which the affected epidermis consists of polyhedral plates and accumulations, papules, or spines, apparently made up of lamellar and fibrous tissue. There are also numerous markedly enlarged papillæ. The under surface of these spines is uneven, projecting from which are seen hardened papillæ. Not only are these various formations of a dark color, but the skin as a whole also assumes a dirty-gray or brownish hue, so that the patient presents a remarkable appearance (hystricismus). A family of such extreme cases (the Lamberts, father and two sons) was exhibited and described in the last century as "porcupine men." When the overlying, or superficial, horny masses are removed, the

fresher plate-like scales are disclosed. Horny wart-formations are often found in ichthyosis in which the distribution corresponds to nerve tracts (Kaposi).

Excepting the increased horny formation of the corneous layer, the eventual obliteration of the granular layer and the atrophy of the papillary body, histologic examinations show nothing characteristic which might have a bearing upon the solution of the pathogenesis of the malady. Most authors consider a hereditary disposition of the skin to cornification as the substantial etiologic factor. Cases are observed where the ichthyosis is inherited by both sexes of the descendants, but also so-called crossed heredity is also seen; Kaposi observed an ichthyotic mother whose five sons all presented the disease, while the three daughters remained free. Inasmuch, however, as in a number of instances the hereditary nature of the malady is lacking, some authors, but chiefly Tommasoli and Unna, are of the opinion that it is of an inflammatory origin.

Unfortunately, ichthyosis is a disease which remains incurable, and in the more severe cases at least, owing to its recognized hereditary tendency, is, with properly minded people, a hindrance to marriage. The mildest types practically disappear during the heated season, and the more severe cases are also favorably influenced by a warm temperature. It is only possible to lessen the symptoms of the more marked cases and to keep those of the milder types in more or less abeyance by certain hygienic and therapeutic external measures.

Treatment.—The removal of the scales and horny formations is attained by rubbings and washings with sapo viridis, Wilkinson's ointment, β-naphthol salve, and salicylic-acid-resorcin-tar salves, in combination with baths and prolonged wet packs. In average cases the skin is made smooth and flexible by these measures, and it can be kept in this favorable condition by applications of fat, glycerin baths, starch baths, and sweat baths daily or occasionally, according to the type of disease and the season of the year.

The horny papillomatous outgrowths in ichthyosis hystrix are to be removed by caustics or by operation.

Internal treatment has, up to the present time, proved of no value.

In a close general relationship to the lightest grade of ichthyosis stands **lichen pilaris** (Plate 57). It is likewise most marked or developed on the extensor surfaces of the upper and lower extremities, and consists of pale red papules surmounted with a central epidermic scale. After removal of the epidermic scale a rolled-up lanugo hair is observed. In consequence of this affection the skin is given, especially in the period of puberty, a goose-flesh appearance. Often the malady is observed generally distributed in association with ichthyosis.

The so-called **ichthyosis congenita** (**keratosis universalis congenita**) is only to be found as a malformation in dead-born fetuses [not always, according to the observations of other observers as well as of myself.—Ed.]. It consists of a universal accumulation of thick horny scales and plates, mostly in combination with deformities of the face. The entire body is covered with whitish, yellowish, reddish or brownish, large horny masses, which, especially on the back, is suggestive of a coat-of-mail (*harlequin fetus*).

ACANTHOSIS NIGRICANS (KERATOSIS NIGRICANS (KAPOSI); DYSTROPHIE PAPILLAIRE ET PIGMENTAIRE OF THE FRENCH).

Acanthosis nigricans (Plates 62 and 63) is a very rare disease and is characterized by two features: deposit of pigment in the papillary layer and—in addition to a mild degree of hyperkeratosis—marked hypertrophy of the papillary body. The hyperkeratosis, which mostly can only be recognized histologically, is, as compared to the above-mentioned characteristic factors, inconspicuous. The sites of predilection are the neck, the axillæ, the breast, the navel, anal and genitocrural regions, and the

poplitea. In isolated cases the mucous membrane of the mouth and the tongue also share in the process. This condition of the skin causes no special trouble beyond the fact of its presence and the disfigurement caused; but as the disease is usually on covered parts, this latter is of comparative insignificance.

It is worthy of note that in the majority of the cases so far reported carcinomatous disease of the stomach or of the uterus was present, so that the skin conditions were overshadowed by the symptoms produced by this latter disease. In a case reported by Spietschka there was a deciduoma malignum, after operation for which the skin affection disappeared. In Grosz's case there was a carcinoma of the uterus together with metastases in the inguinal and retroperitoneal glands. Alcoholism has been repeatedly noted.

Histologically, one finds pigmentation, papillary growth, and thickening of the stratum corneum. The pigment is chiefly seated in the basal cylinder cells, in stratum papillare and subpapillare, and in the lymph channels of the glands. Changes in the cutis are of an unimportant nature. Kaposi viewed the malady as a hyperkeratosis, and for this reason designated it keratosis nigricans.

The **treatment** is to be based upon ordinary hygienic rules, modified by circumstances. The clinical observation that in some cases after the surgical removal of the causative or associated malignant new-growth the skin affection disappeared is to be kept in view in the management of cases. In the case observed by us resorcin salves seemed to exert a favorable influence.

PSOROSPERMOSIS FOLLICULARIS VEGETANS (DARIER).

Darier has described an independent disease in which there are growth and hardening of the epidermis, an affection in which apparently the cutis has no share. There appear small horny formations due to hyperplasia

in the stratum corneum, which are pointed toward their outer part and project from the epidermis.

These small papules are not only found in the sebaceous-gland outlets, but also can be found everywhere in the epidermis, and can eventually even arise also in sweat pores. The stratum Malpighii underlying the formations is here and there thinned. Neck, brow, inguinal region, axillæ, and backs of the hands are attacked. The psorosperms which Darier found are not now believed to be in reality these bodies, but arise, according to the latest investigations, through concentric cornification of the epidermis cells. They are met with in two forms—as rounded little bodies ("corps ronds") the size of an epidermis cell, with a nucleus, most abundant in the granular layer; and as an irregular formation ("grains"), without nucleus, in the upper epidermis layers. These latter are gradually developed out of the former bodies, and are to be viewed as changed epithelial cells (Jarisch). The later investigations (Boeck, Mourek, Jarisch, and others) show that the parasitic nature of the malady [so far so concerns these bodies—ED.] is negatived; this Darier himself has lately conceded. Another satisfactory solution of this peculiar malady has not yet been found.

Treatment.—Keratolytica (salicylic acid, resorcin) are, as a rule, badly borne, mild pastes and salves (with zinc oxid, boric acid) are much more satisfactory.

Jarisch lately made use of paintings of Vleminckx's solution, followed by a protracted bath with soap washing, and finally applications of boric-acid lanolin with a favorable influence, which unfortunately was only temporary. At all events, it is well to guard oneself as well as the patient against too much hopefulness in this malady, for as yet a cure has not been attained.

KERATOMA HEREDITARIUM PALMARE ET PLANTARE.

This peculiar hyperkeratotic malady begins without any subjective symptoms in the earliest infancy, and presents

as thick-fissured callous accumulations or coatings on the palms and soles. Many times the usually smooth surface is beset with honeycomb-like depressions. Almost always there is an associated hyperidrosis of the involved parts. The malady remains stationary throughout life; only seldom are superficial maceration and exfoliation noted.

According to Vörner, the histologic investigation shows that the corium is practically normal, while the epidermis is substantially changed; marked increase in the horny-cell layer, excessive development of the prickle layer, increase of the keratohyalin in the stratum mucosum and of the eleidin in the stratum lucidum.

As to etiology, the chief and only known factor is that of heredity, both direct and crossed, as has likewise been observed in ichthyosis.

The malady is incurable, and the patients, owing to the lessened delicacy of touch, are unfitted for the better class of work. Fissures and rhagades on the soles can also impair the comfort and capacity for walking.

SCLERODERMA, EDEMA NEONATORUM, AND SCLEREMA NEONATORUM.

Scleroderma, which, contrary to edema neonatorum, with which it is often confused, occurs mostly in adults. It appears in circumscribed areas on the skin, which show hardening and brownish discoloration. On the attacked places first of all an edema develops, this becomes indurated, and an atrophic stage follows. In most cases the extremities are first attacked, and there arise, in irregular extension, hard nodules in the skin, which in the lower layers can coalesce, so that the skin becomes over great areas thickened and stiff. Frequently there is paresthesia of the fingers (*sclerodactylia*), which formerly was looked upon as an independent disease. The form of scleroderma which occurs as rounded patches has been known as **morphea.** The marked tension of the indurated skin can give rise to an exceedingly unpleasant feeling, so that

patients have the sensation of being in a strait-jacket. The sclerodactylia exposes the patient to many occupation injuries. Hairs and nails become atrophic in many cases and fall out.

Histologically, the first steps in the process consist chiefly of changes in the corium, connective-tissue increase, with here and there hyaline degeneration; in the later stages atrophy of the stratum corneum as well as of the papillæ or of the whole mucous layer. Most authors have classed scleroderma as a trophoneurosis or an angiotrophoneurosis. In some instances it is congenital. In such cases complete cure takes place (Luithlen).

Brocq commends the electrolytic treatment of individual plaques (2–10 milliampères).

Œdema neonatorum appears in the very first days of life, in weakly, premature, or syphilitic children, and consists of an edematous swelling of the lower extremities, the skin of the mons veneris, and many times also of the eyelids and upper extremities. If the malady is universal, death rapidly takes place; nevertheless, milder cases have been observed with a favorable outcome. According to Luithlen, the malady histologically is merely a common edema of the skin and subcutaneous tissue, which, in consequence of incomplete or imperfect development of the skin (corresponding to that of a six- to eight-month fetus), presents the favorable conditions for edematous infiltration.

Sclerema neonatorum, or **sclerema adiposum,** is likewise only met with in badly nourished infants in their earliest life, and gives rise on all places, where there is an underlying adipose layer, to symmetric arrangement of a hard, board-like thickening of the tissues, in consequence of which motion and mobility are much compromised. The skin feels very cold, like the corpse of one frozen (Widerhofer). The histologic findings (abundant fatty acid crystals) indicate an abnormal condition of the fat, perhaps from small quantity of the oleic acid (Knöpfelmacher). The prognosis is most unfavorable.

ANOMALIES OF THE HAIR.

Alopecia.—Congenital alopecia is observed mostly as an insufficient hair growth with lanugo hairs, which may sometimes be replaced by normal or increased hair production.

Alopecia senilis is the alopecia coming almost invariably with advancing years, which begins from the brow, extending toward the occiput, the hair still remaining on the sides.

Acquired hair loss—*alopecia præmatura*—appears between the twentieth and thirtieth years, as a result usually of hereditary predisposition. Frequently this form of alopecia is met with in several members of the same family. As also in the senile form, the hair loss on the involved region in these cases, with the exception of insignificant lanugo, is complete and permanent. The skin is smooth and shiny, and the follicles are atrophic.

Alopecia traumatica can result from mechanical influences, as, for instance, on the back of the scalp with those ill, who have been obliged to keep their bed for a long period.

Alopecia atrophicans idiopathica is characterized by irregularly scattered hairless spots on the scalp, which, in consequence of their shining, cicatricial appearance, have a resemblance to the hair loss of favus. The etiology is obscure.

Folliculitis decalvans is that form of partial alopecia in which the hair is lost in consequence of a folliculitis.

Alopecia Totalis Præmatura Neurotica.—Sometimes the hair falls out in young individuals inside of a few days or weeks, without any recognizable disease of the hair. At times it is noticed to be dry, and with a tendency to split or break. The most conspicuous loss is of the hair on the scalp; but the eyebrows and eyelashes also fall out, and frequently the pubic and axillary hair, and, in fact, the surface hairs of the entire integument.

The hair that sometimes grows after such loss is thin

and atrophic, and soon falls out. The skin shows no changes worth mentioning. It is to be noted that frequently the nails share in the disease, and are milky and fragile. Almost always nervous symptoms are associated, such as nervous disturbances, migraine, and psychoses. The hair fall in these cases is considered to be a trophoneurosis.

Temporary hair loss is noted after acute infectious diseases, as, for example, after typhoid, puerperium, etc., and often months afterward (**alopecia symptomatica**). Gradual alopecia may present in eczema, psoriasis, lichen ruber, pityriasis rubra. In erysipelas, on the contrary, loss of hair may be rapid. The alopecia after seborrhea (**alopecia pityrodes** or **alopecia furfuracea**) mostly leads to partial baldness, which in young individuals can be gradually reproduced.

After **syphilis** hair loss is scarcely ever complete, and can be either universal or come out in spots after a local relapse of the syphilid.

Alopecia Areata (Plate 64).—Without apparent skin changes bald spots appear on the scalp, which peripherally enlarge; frequently only one or several at a time. The hairs seem of normal appearance. Those which are at the immediate periphery of the patches, as a rule, may be easily pulled out. The skin is pale, but without change in the sensibility. Frequently contiguous bald spots become confluent, and then there arise larger hairless areas; seldom, however, complete baldness of the entire scalp. After some months lanugo begin to appear, which later are replaced by normal hair. Such regrowth usually takes place in from one to two years, sometimes in a shorter period.

As to the etiology of this malady, as yet there has not been a uniformity of opinion. Inasmuch as it has been repeatedly observed in apparent epidemic form in orphan asylums, barracks, etc., a parasitic origin by means of the hair apparel, communicated from one to another through the hair covering or toilet articles, is likely. Other authors place the malady among the trophoneuroses. Max

Joseph was able to produce experimentally on the ears of cats patch-falling of the hair, similar to alopecia areata, by means of extirpation of the spinal ganglion of the second cervical nerve. Since for both these views there is much evidence, the opinion of Lesser seems the correct one—that there are etiologically several processes with the same clinical picture. The theory of Jacquet that alopecia areata arises from dental irritation has recently been negatived by Bettmann.

Treatment of alopecia naturally should be based upon what seems to be the possible etiologic factors in the case under consideration. It must, however, be remarked that this theoretic division in the treatment is not closely followed, but that substantially all therapeutic efforts have in view a local irritation, and the various local remedies employed to produce this are of stimulating and antiparasitic character. For the neurotic type internal tonics are especially recommended, such as iron, arsenic preparations, pilocarpin, local massage, application of the faradic and galvanic currents. Of the local remedies may be named the application of salt solutions, acetic acid, tincture of cantharides, tar tincture, oil of mace, chrysarobin, resorcin, etc. If seborrhea is associated, it must be treated according to approved methods, as this condition has an important etiologic bearing in such cases.

The Röntgen-ray treatment of alopecia has worked well in some cases, but failed in the majority. It does not show any superiority over the other employed methods (L. Freund).

The hairs can also show **changes in their structure.**

Trichorrhexis nodosa occurs more commonly on the bearded region, as nodular excrescences on the hairs. On the hair shaft may be seen one or several such swellings. The hairs break easily at these points, and there remains a brush-like extremity. Hodara states that he has found a microörganism in this disease and has cultivated it; he was able to produce on sound hairs the

same disease. Spiegler has also had a like experience. Kreibich rightly points out that the supposed micro-organisms must have their seat in the hair follicle and not in the hair, inasmuch as shaving of the hair does not have any influence in inhibiting the malady.

Treatment.—Treatment is usually fruitless. Besnier advises depilation of the diseased hairs and the application of tincture of cantharides. Eichhoff advises keeping the hair closely cut and the rubbing in of

℞ Vanillini, 0.20 (gr. iij);
Adipis, 10 (℥iiss).—M.
Ft. unguentum.

Tar-sulphur salves, aqua ammoniæ, etc., have also been recommended.

The splitting up of normally appearing hair in its length is called **trichoptilosis**; the hairs are thin and dry. Perhaps the malady depends upon the lessened fat-constituent of the hair. Sometimes hair shows hyperkeratotic, spindle-shaped swellings (**spindle hairs**).

Hypertrichosis (**hirsuties**), or abnormally strong hair growth, develops in consequence of some freak of nature on parts not normally hairy; on women on the upper lip and chin, on the sternum, in the sacral region, or in a nevus on any part. Generally the hairs in hypertrichosis are unusually thick and long. In rare instances hairiness is observed in children in places which are only normally hairy at puberty.

The congenital universal lack of pigment (**albinismus**) results in yellowish-white, soft, thin, silky shining hairs, from which the pigment is completely absent. The circumscribed form of inherited lack of pigment we name **poliosis.** Acquired whitening of the hair is observed temporarily after alopecia areata, erysipelas, zoster; and after vitiligo it may remain permanently.

Graying of the hair or **canities** (Plate 65) appears physiologically with increasing years; premature graying

begins generally on the temples and spreads from here over the rest of the scalp and on the bearded region.

According to Ehrmann, graying of the hair is due to the lack of pigment-bearing cells (melanoblasts) in the rete and in the bulb. Thus, one finds hairs which have a dark end and a white proximal growing part. Spiegler has shown that whitening of the hair results from the entrance of air bubbles as well as upon a white pigment that he is able to demonstrate. The cases of sudden blanching of the hair after psychic affections, as communicated by Brown-Séquard, Landois, Raymond, Levy, and others, must likewise be ascribed to the entrance of air, the reason for which, however, remains unknown.

Recently Matsuura, from his investigations in the pathologic institute in Strassburg concerning the various thicknesses of scalp hair in healthy and sick individuals, has made some interesting statements, which have received corroboration, especially by Kromayer. He found in those who had suffered with a general or febrile disease both the color and the diameter of the hair grown during the illness had lessened. Accepting that the hair grows 0.4 mm. daily; by taking a hair from such an individual from the root out and examining it, one can tell approximately the date of the beginning of the malady, the duration, and perhaps also the intensity. In this manner one could subsequently, as regards these several points, complete an imperfect or incorrect history of the case. Such an investigation might also be now and then of medicolegal importance.

Control experiments with rabbits poisoned with strychnia and thallium acetate led to the same results.

ANOMALIES OF THE NAILS.

Irregular formation and shapes of the nails arise from excessive growth, by thickening and malformation in consequence of hypertrophy of the nail bed. The nails become claw- or talon-like, and twisted like a horn

(onychogryposis). The latter arises from the fact that the nail body is lifted up from the nail bed by the accumulation of hardened masses beneath; or such growth and accumulation may take place at the forward part of the nail bed only. The borders are hypertrophied and the lamellar masses show a structure similar to that of cutaneous horns. While Virchow and Unna attribute the malformation to mechanical action of the shoeing, Heller believes it due to a trophic disturbance. Onychogryposis develops after syphilis, after ulcerating lupus, lepra, burns, in tabes, and peripheral paralysis, but also in older individuals without any demonstrable disturbances.

Absence of the nails is observed after paronychia, in atrophic conditions of the end phalanges, and possibly in disease of the neighboring epidermis (psoriasis, etc.).

From penetration of air in the nail plate arise the well-known **white spots, flores unguium, leuconychia punctata**; less frequently white markings running across the nails with normal nail substance between (**leuconychia striata,** Morison), or a leuconychia totalis. Brauns believes that leuconychia arises in consequence of a parakeratosis.

Softening and fragility of the nails are named **schizonychia,** hard thickenings as **scleronychia.** Ehrmann describes a division of the nail into two lamellæ (**onychoschisis symmetrica**).

A splitting up of the nail plate in its anterior portion, which only occurs in old people, Dubreuilh reported as **onychorrhexis.** Pit-like depressions of the nails arise in consequence of hyperkeratosis of the anterior nail bed, the edges often being thrown upward and often cracked (**koilonychia,** Heller). Similar cases of **platyonychia hereditaria** have been described by Waelsch.

In giant growth and in acromegaly hypertrophy of the nails is observed. The **hyperkeratosis subungualis** (Hebra) consists of the development of thick, dirty-green, horny masses, which shine through the normal nail plate, and which develop in the matrix of the fingers and toes.

Diseases of the matrix with milkiness of the nail substance is found also in eczema and psoriasis.

The **syphilitic onychias** and **paronychias,** which on account of the resistance of the hard uplifted structure, are often very painful affections; they arise mostly secondarily, in papular or pustular infiltration of the nail bed. They frequently result in a softening and splitting up of the nail plate (**scabrities unguium syphilitica**). Heller describes a **syphilonychia ulcerosa hereditaria.**

The parasitic onychoses, as in favus and trichophytosis, will be referred to in the section treating of these affections.

PIGMENT ANOMALIES OF THE SKIN.

Paleness or **whitening of the skin** occurs in anemic states, in consequence of lack of blood after hemorrhages, after depressing diseases, and in chlorosis and dropsy. It is also observed in alternation with the hyperemic reddening in the symptom-complex of Raynaud's disease.

Congenital want of pigment (**albinismus universalis**) occurs as a hereditary anomaly. The otherwise normal skin of such individuals (*albinos*) is completely without pigment, white, pinkish, or reddish in color. In consequence of the blood-vessels shining through the iris the eye appears red. Albinos, as a result of the lack of pigment, are sensitive to light and have nystagmus. The hairs are fine, silky, shining, and completely white.

Also after certain diseases of the skin the pigment normally present disappears completely.

Albinismus partialis occurs as congenital loss of pigment in circumscribed regions of the skin. Its distribution frequently corresponds to the domain of a nerve, and, unlike acquired pigment atrophy, the areas are surrounded by normally pigmented skin. The hairs in such pigmentless regions may also remain white; this, however, is not invariably the case.

The acquired form of pigment loss (**vitiligo, leukoderma,** *leukoderma acquisitum*) (Plate 66) begins at first as small white spots, which spread slowly and irregularly; the bordering skin is overpigmented. There is no textural change in the skin of such areas beyond the loss of coloring matter, the integument being otherwise anatomically normal; moreover, there are no functional disturbances. The disease may in the course of years involve almost the entire surface, a few dark stripes or areas being left. The hairs become white with the skin. Innervation disturbances have been looked upon as responsible for this variety. It is only occasionally that an external factor may be productive of these spots, as, for example, pressure of bandages or constriction of scars. It is known that after certain acute diseases, as, for example, typhus, scarlatina, etc., vitiligo has been observed to occur. In most cases, however, the affection is seen between the tenth and thirtieth years in individuals apparently otherwise in normal health. We had opportunity to observe an achroma in a psoriasis case after treatment with iodothyrin (Plate 69).

The displacement of pigment by the melanoblasts from the epidermis, as well as from the cutis, is shown in vitiligo, without, however, our knowing the actual causes of the process. While Ehrmann and Oppenheim regard the melanoblasts as pigment-forming cells of mesodermal origin, these have been considered by others as optical illusions, effusions from the intercellular spaces (Kromayer).

After syphilis spot-like loss of pigment has been observed, mostly in women, in the neck region, most frequently after a macular or papular syphilid (**leukoderma syphiliticum**). According to Riehl, this is due to the fact that the epithelium in the neighborhood of a syphilitic product loses the capacity of retaining the pigment, and it is given up to the chromatophores. Inasmuch as the latter in their function—formation and the retention of pigment—are damaged, a portion of the pigment in the

neighborhood of the spots remains and give rise to a hyperpigmentation.

Increase in pigmentation may occur as a congenital condition; it is, however, more frequently an acquired affection.

Brownish, brown, and black discoloration of the skin, in variously sized areas, is observed as a congenital affection—pigmentary moles (*nævus pigmentosus*) (Plate 67). Small moles may also be an acquired blemish.

On several regions of the body are observed circumscribed pigment spots, such as **freckles** (*lentigo, ephilids*). They are, as well known, millet-seed-sized to pea-sized, or possibly larger, yellowish brown or brownish in color, which are met with in summer on the face and on the hands, but occasionally also on parts covered with clothing, disappearing partly or completely in winter time. They are observed more frequently in blondes and red-haired individuals than in brunettes. After the fortieth year of life they, along with other hyperpigmentations, disappear. The direct influence of sunlight and the sun-heat in the production of freckles is, in the majority of cases, undeniable, but they are also sometimes congenital.

Of other varieties of pigmentation, there remains to be mentioned that which sometimes occurs in association with diseases of the female sexual organs—the so-called **chloasma uterinum,** a yellowish and grayish or brownish discoloration on the face, on the areola of the nipple, and in the linea alba. Discoloration of the buttocks, trunk, and extremities was observed in cystic degeneration of both ovaries (Neusser); after double ovariectomy the discoloration rapidly disappeared. In consequence of long-continued pressure of the clothing and belts and bandages, as well as from long-continued scratching, arises the so-called **chloasma traumaticum. Chloasma caloricum** results from the highest degree of erythema caloricum.

Treatment.—From a prophylactic standpoint, the shutting out of the ultraviolet rays is of importance (wearing of red veils, quinia salves). In persistent

freckles and also in chloasma and other discolorations the application of corrosive-sublimate solution, alcoholic or aqueous, ½ to 1 per cent. strength, is to be recommended. Covering the affected areas with compresses wet with the solution is useful; its action should be carefully watched if the stronger solutions are employed. Also the application of the following:

℞ Bismuthi subnitratis,
Hydrarg. præcip. alb., *āā* 5 (gr. lxxv);
Adipis, 50 (℥iss).—M.
Ft. unguentum.

Or salves of β-naphthol or resorcin, already referred to.

In addition to these several methods for the removal of freckles and chloasma may also be mentioned the application of:

℞ Adipis lanæ, 5 (gr. lxxv);
Vaselini, 10 (℥iiss);
Hydrog. peroxid., 20 (f℥v);
Hydrarg. chlorid. corros., 0.05 (gr. ¾);
Bismuthi oxychlorid., 0.5 (gr. viiss).—M.
Ft. unguentum (Unna).

Very valuable also is the use of Unna's sodium superoxid soap (2.5–5 per cent.), of which a piece as large as a bean is rubbed into the affected skin with water; the resulting lather is, after some minutes, washed off.

Leloir advises washing the parts with sapo viridis or alcohol, and then painting on a 15 per cent. solution of chrysarobin in chloroform; the spots, after this dries on, are painted with a solution of gutta-percha. Hardy recommends the application of:

℞ Hydrarg. chlorid. corros., 1 (gr. xv);
Zinci sulphat.,
Plumb. acetat., *āā* 2 (gr. xxx);
Aquæ destillat., 250 (f℥viij).—M.
Sig.—For external use.

In many of the cases of acquired pigmentation large areas, or indeed the entire surface, may be more or less pigmented. The pigment often arises from hyperemia, and this usually from some direct irritation of the skin. On the other hand, in some cases pigmentation results as a consequence of diseases of one or more organs; in such the pigment may also be deposited within the viscera as well as in the skin. The several diseases or conditions which lead to pigmentation are:

Melasma is a discoloration of large areas, frequently on the lower extremities, widespread, brownish in color, following chronic inflammations and congestions in cachectic and emaciated individuals of impaired nutrition. A like condition, consisting of a general darkening of the skin, is observed in consequence of neglect in individuals with flabby panniculus (chloasma cachecticorum), as, for example, in phthisics, in whom the skin appears greasy, smeary, and discolored.

Vagabonds' disease (Vogt) is a melanosis observed in tramps, which arises from neglect of the skin, lice, and heat.

A dirty-gray discoloration of the skin is observed in malarial cachexias.

The discoloration in *pellagra*, a disease which has been described in connection with the erythemas, may also be mentioned here.

Further, *melanoicterus* of the skin is observed in cirrhosis of the liver and in chronic forms of icterus gravis. It may assume on some regions of the body a peculiar bronze color.

In diabetes mellitus melanodermic conditions (diabète bronzé of the French) are likewise observed. Also in those cases with which are associated polydipsia, polyphagia, polyuria, and glycosuria, the pigment accumulation being present in the various organs and lymph glands as well as in the skin. This pigment contains iron, and is to be looked upon as a derivative of hemoglobin.

In this group belong also the melanodermata observed in affections of the pancreas, with or without associated glycosuria.

Morbus Addisonii.—This disease, described by Addison, associated with disease of the suprarenal capsules, occurs as a bronzing of the skin, expressing itself also in disturbances of the digestive tract and nervous system, and almost always ending fatally. According to Lewin, disease of the suprarenal capsules is observed in 88 per cent. of the typical cases. In autopsies, tuberculous or carcinomatous degeneration of the suprarenal capsules has been noted. In some cases tuberculosis of these bodies has been diagnosed in life (Pospelow and Gautier-Dufayer). The discoloration appears some time after the patient has been complaining of feelings of weakness, depression, and the sensation of pressure in the stomach, often pain in the entire abdomen, increased thirst, nausea, etc.

At first the color is a dirty yellow, yellowish brown, or smoke gray, and by gradual darkening it becomes that of bronze, and may even become black. The uncovered parts and parts which are subjected to pressure of the clothing are most conspicuously involved; sometimes also the mucous membranes of the lips and mouth.

The discoloration is either spread over larger areas, in which clear-white spots are irregularly scattered, or it may appear in the form of single irregular patches. The hairy parts may also be discolored; the hair itself does not, however, usually share in the process. The skin of the face is, as a rule, the darkest; the nails and the nail beds are seldom pigmented.

The skin is smooth and elastic to the touch, and inclined to sweat, but shows no other changes worthy of mention.

The pigmentation arises, according to Neusser, through the medium of the general and local sympathetic nerves; the impairment or abolition of the function of the suprarenal capsules being the underlying factor.

To the general weakness are added depression of spirits, ill-temper, and impairment of the intelligence. Emaciation, cachexia, weakness of heart action, palpitation, and dyspnea are symptoms of the early stages. Death results, with gradual and increasing prostration, in consequence of heart weakness; sometimes the end comes with high fever, diarrhea, persistent vomiting, delirium, and finally collapse and coma. The duration of the disease varies, the extremes being months and years. Often the end comes suddenly, without the patient having gone through the several stages or symptoms mentioned.

In the preceding remarks processes have been described in which the pigment arises from organic constituents within the patient himself, in consequence of some pathologic process. There are, however, other pigment deposits observed in the skin, composed of certain mineral substances which have been introduced into the system or skin from without. We will refer to the most important representatives of this group—the pigmentations arising from the use of silver nitrate and arsenic.

The discoloration of the skin from arsenic—*arsenical melanosis*, *arsenicismus*, *hyperchromatosis arsenicalis*—occurs after its continued administration or from the fact that the patient's occupation brings him in contact with it (Plate 68).

Arsenic is introduced by the mouth as medicine or is taken unconsciously in drinking-water; or, as already stated, the patient is engaged in some occupation in which arsenic is used. It may also be introduced through the lungs and skin from arsenic-containing carpets, wall-paper, etc.

The discoloration appears upon the skin, the mucous membranes remaining free (the contrary of lead-poisoning).

The pathogenesis of the pigment formation is not yet understood. It has been assumed that the poison, through its affinity for certain substances, breaks up the blood-corpuscles, the blood-coloring matter producing the skin

pigmentation. The pigment is found in the lowest basal cells of the rete and in the cutis. The fact, however, as clinical observation teaches, that the pigment is deposited, or often more markedly, at least, at the sites of former diseased areas of the skin (eczema, psoriasis, etc.), is not readily explained.

The quantity of arsenic which may give rise to pigmentation of the skin differs materially in different individuals. In the case depicted it appeared after the administration of 0.26 (gr. iv) of arsenious acid; in other cases only 0.216 (gr. iij $\frac{1}{4}$) of arsenious acid had been taken; and in one case in Schrötter's clinic 0.125 (gr. j $\frac{7}{8}$) was sufficient.

As regards the time required, it has appeared in some cases after six months' administration of Fowler's solution; in others, not before three years, after doses of five to ten drops three times daily.

The pigmentation appears gradually, and especially on those regions which are normally hyperpigmented. In most cases the skin is noted to have a bronze tint; not infrequently, however, a graphite color.

As soon as the arsenic has been discontinued the skin begins to resume its normal hue, especially if other damaging effects upon it by the drug (to be referred to) have not been observed. The more intense the pigmentation and the older the patient, the more slowly does it disappear.

As a further effect of the administration of arsenic on the skin we have *arsenical hyperkeratosis* (Wilson). In addition to the uniform hyperkeratosis on certain parts, as the hands and feet, corn-like horny formations appear with central depressions, which correspond to the hardened outlets of the sweat glands. Arsenical hyperkeratosis is said to lead sometimes to the formation of epithelial growths.

Argyria.—By the deposition of reduced silver in the skin from the ingestion of silver nitrate the integument becomes discolored. The silver is found outside of the

cells in the finest subdivision. The face is the part most frequently and markedly pigmented; also the conjunctivæ bulbi become gray, and likewise the nail bed. In the beginning the skin is pale gray; after continued administration of the drug it becomes dark blue or cyanotic in color.

As in cases of arsenical pigmentation, the examination of the urine is an important diagnostic help in this disorder; the presence of silver can be readily demonstrated.

NEW GROWTHS (NEOPLASMATA).

NEVI.

Among the benign connective-tissue new growths of the skin, in addition to the already mentioned warts, stand in first rank the nevi. Such are the congenital, circumscribed cutaneous growths, in the majority of cases pigmented, and which substantially have the same anatomic construction as the normal skin. They are to be found in almost all individuals. Barthélemy and Levy, in their examination of two hundred persons as to their existence, found them present in all. Although, except as to their cosmetic aspect, they have but little practical interest, the question of their origin has been much discussed and is still an open one.

Small wart-like nevi, with an uneven surface (**nævus verrucosus**) (Plate 70) are growths from the corium covered with a pigmented epidermis. They are often beset with hairs, or with dilated sebaceous glands, and may have either a broad flat base or may be more or less pedunculated.

The so-called **nævus mollusciformis** or **nævus lipomætodes** is another example, differing in being rarely sessile and occurring as pendulous, pedunculated small tumors on the skin of the neck and eyelids.

Nævus spilus occurs in the form of elevated lesions, the size of a lentil or bean, but may occasionally be distributed over large cutaneous areas in the form of hyper-

trophy of the skin and papillæ, accompanied by black or dark-brown pigmentation, which often extends even into the cutis. Nævus spilus is very frequently covered with stiff hairs. The so-called **nerve nevi** are distributed over the course of one or more spinal nerves. The names **linear nevus, systematized nevus,** and others have been given to those nevi which in their distribution seem to have some connection with the developmental lines of the skin. Many times the ordinary circumscribed nevi may involve a large portion of one region of the body (animal-like nevus, "bath-trouser-like" nevus).

While nevi mostly keep their form and size the same throughout life, they can suddenly, through rapid growth of the cell nests lying in the corium, which are often present at birth (Max Joseph), develop into a malignant tumor (carcinoma and melanosarcoma).

The **etiology** of nevi, as already intimated, is unknown. While Ravogli maintains the epithelial derivation of nevi and claims to have observed direct transformation of the nevus cells, Schutz holds that such were misinterpretations in consequence of faulty sections. According to Fick, the pigment of the nevus cells comes from the melanoblasts, with which the nevus cells are standing in contact. The nevus-cell formation and the pigment-cell formation are independent of each other. Riecke also holds that the pigment of the nevus plays but an incidental or secondary rôle in its development. He considers nevi as off-springs of the embryonal connective-tissue cells, which lose the capacity of producing fibrinous connective and elastic tissues, and which, in later life, may remain in a condition corresponding to an embryonal stadium of the connective-tissue cells. This theory is also, as Frédéric lately laid stress upon, unproved.

Treatment.—In the smaller lesions the application of caustics, such as trichloracetic acid, lactic acid, and nitric acid, or sublimated collodium (5–10 per cent.), is recommended for the removal of flat nevi; if not successful, electrolysis or excision is to be advised.

When the growths are of larger size and removal by surgical means is contra-indicated or objected to, recourse may be had to electrolysis (Voltolini, Hardaway, Fox) or the galvanocautery.

CICATRIX OR SCAR.

Losses of substance of the skin extending into the corium, or at least into the papillary layer, are replaced by cicatricial formation. Scars are likely to occur after burns, suppuration, and caustic applications, and after diseases leading to purulent destruction of tissue, as lupus, scrofulosis, and various dermatitides, or extensive hemorrhages and gangrene of skin. After the necrotic mass has come away the granulation tissue to replace the defect begins to form. The proliferation of the granulation tissue commences in the deeper parts, and is gradually converted into connective tissue, which becomes covered with an imperfect epidermis. The numerous islands of epithelium which can be seen in extensive wounds after burns probably originate from the epidermis of the sebaceous and sweat glands. Fresh cicatrices are rich in cells and contain numerous blood-vessels; the older ones, however, contract, the blood-vessels become occluded, and fibrous connective tissue forms. Cicatricial formation is frequently of great significance, according to its extent and location, as it frequently leads to contraction and fixation of the articulations. When involving the face, the orifice of the mouth is distorted or contracted, ectropion of the eyelids results, and finally, owing to constriction, circulatory disturbances frequently supervene, which lead—especially on the extremities—to secondary edematous stases and overgrowth of the tissue, elephantiasis. Sometimes scars are the starting-point of the development of malignant tumors.

The **scar keloid** is a bluish-red, scar-like projecting, mostly painful growth, which originates in a scar. It frequently starts from a small scar, while, strange to say,

large scars are followed much less frequently by such a formation. This tendency is seen especially in negroes (Kaposi). Quite frequently it starts from the piercing of the ear or in tattooing. Scar keloids sometimes present a resemblance to a nevus, but the history and extending growth can serve to distinguish them from the latter. Histologically, one finds complete disappearance of the papillary body.

True keloid is a flat, elevated, white or bluish-red, firm, tumefied, cicatricial hypertrophy, which frequently sends out claw-like processes. It is covered with a thin, shining epidermis, and consists of accumulated embryonic connective-tissue elements embedded in dense fibrous tissue. Mostly it is in the form of one or several club-shaped tumors in the sternal region, and, in contradistinction to the scar keloid, it is a spontaneous formation developing from the skin without a preceding scar, and in which the papillary body is retained. After extirpation of such tumors new similar formations are generally developed. The etiology of true keloid is wholly unknown.

ELEPHANTIASIS; PACHYDERMIA.

Acquired elephantiasis represents a hyperplasia of the corium and hypertrophy of the papillæ. The enormous size of the affected part sometimes reached is due to marked hypertrophy of the subcutaneous cellular tissue; this condition occurs most frequently on the lower limbs (Plate 71). Higher degrees, with irregular hypertrophy and sclerosis of the subcutaneous connective tissue, and various, even verrucous, vegetations of the papillary layer, are met with; occasionally, thickened tuberosities and firm linear infiltration are at first noted beneath the skin. The integument and subcutaneous tissues are permeated with serum, and in very advanced stages the muscles down to the periosteum and subcutaneous tissue are degenerated and indurated (*elephantiasis arabum*). Eczematous, erysipelatous outbreaks with inflammation

of the connective tissue, associated with phlebitis and lymphangitis, are the direct cause of these deformities. Hardening and obliteration of the veins and lymphatic vessels lead to these consecutive phenomena, which may occur not only on the lower, but also on the upper, extremities, and on the scrotum and labia. Necrosis of the epidermis overlying these sclerotic masses of connective tissue often occurs, and there result large, sinuous ulcers with perpendicular, callous edges, surrounded by cicatricial tissue, papillomatous vegetations, and eczematous skin.

In the case observed by Favarger, pictured by us (Plates 72 and 73), a marked elephantiasis of both lower extremities had developed. In consequence of heart weakness, first an edema of both lower extremities appeared, which, favored by very frequent attacks of erysipelas, led to lymph stasis, and gradually, probably as a result of an individual disposition, induced connective-tissue new growth and elephantiasis.

In rare instances a diffused thickening of the skin of the face is observed (**leontiasis**).

The elephantiasis of the female genitalia, designated **ulcus chronicum vulvæ** or **esthiomene,** is localized most frequently on the labia majora, around the urethra, on the posterior commissure, and the anus. In addition to the elephantiasic swelling of the parts named are mostly to be found ulcerative processes and scar-formation, often also rectal strictures. Many authors have held that elephantiasis vulvæ has an etiologic relationship to syphilis (**gumma urethræ,** Löwenbach), but the syphilitic character of the malady cannot always be proved.

As already intimated, several different causes may be of influence in bringing about an elephantiasis. Congenital elephantiasis may result from amniotic ligation of a limb (Schnitzler). In the Philippines, China, Surinam, Cayenne, Malabar, etc., the Filaria sanguinis hominis plays an etiologic rôle in the endemic elephantiasis arabum.

In a few cases of elephantiasis congenita, Moncorvo

attributed it to the streptococcus of Fehleisen, which he found in mother and child; in consequence of lymphangitic processes in the mother, an intra-uterine infection of the child with streptococci is brought about.

Myxedema.—This disfiguring affection occurs principally in females, and consists of increase in volume of the affected cutaneous parts, which appear swollen, thickened, and hardened. It is met with on the face, on the trunk and extremities, and also on the tongue and velum palati. The hands and fingers also appear more or less deformed, owing to thickening.

The mental and physical faculties of such individuals are also impaired; mental hebetude ensues, the senses of taste and smell are lost, and they are incapable of physical or mental labor. They frequently perish of cardiac and renal disease.

The affection is due to proliferation and deposit of mucin in the skin, in the muscles, and also in the internal organs. The causes are unknown, but it has probably some connection with functional disturbances of the thyroid gland.

Edema cutis, or anasarca, due to circulatory disturbances, is allied to this process. It represents a secondary phenomenon, and not an individual skin disease.

PARTIAL ATROPHY AND THINNING OF THE SKIN.

This condition occurs most usually during middle life in hydrops, anasarca, pregnancy, and rapid accumulation of fat, owing to tension and stretching of the skin; the deeper tissue layers are spread apart and the skin becomes very thin (*striæ gravidarum*). The streaks at first are bluish red; later they turn white and shiny, and resemble cicatrices (*striæ atrophicæ*). For the most part the histologic examination of the striæ shows a separation or fracture of the elastic fibers.

Pressure from a bandage or from an internal tumor causes the skin to become hyperemic for a time; the

macerated epidermis desquamates freely, and finally the skin may atrophy, and after persistent pressure cutaneous necrosis or ulceration and disintegration may result. Partial atrophy develops, especially on those places which are subjected to continued tension, as, for example, over the joints.

In rare instances an **atrophia cutis idiopathica congenita,** with hair loss, depigmentation and anidrosis of the involved parts is observed.

Under the name of **kraurosis vulvæ,** described by Breisky, is understood a continued and persistent progressive senile and presenile atrophic contraction of the vulvæ with rigid narrowing of the vestibule. A hypertrophic inflammatory stadium of unknown origin precedes the atrophic changes.

GENERAL ATROPHY OF THE SKIN.

This is met with most frequently in old age, as a senile atrophy of the skin and appendages, combined with a peculiar degenerative stage, mentioned in the section on the Physiology of the Skin. On the back and breast especially are often found in such subjects warty excrescences of the papillary body, showing superficially abundant granular pigment grains.

There is also a diffuse progressive atrophy of the skin (**atrophia cutis idiopathica progressiva**), and is furthermore induced by many as yet unexplained pathologic processes. The atrophic skin is exceedingly thin and wrinkled, resembling cigarette-paper. It is inelastic, and when pinched into folds returns slowly to its original shape. The veins are dilated, and can be seen as bluish lines shining through the thin, translucent epidermis. The secretion of the sweat glands continues in but few places, as the genitalia, face, and axillæ. The hairs are lost; only a lanugo hair here and there is still visible. The process must be regarded clinically as an atrophy. The progressive form of atrophy of the skin has been demon-

strated histologically to be preceded by a chronic inflammatory process, which takes place principally in the layers of the cutis. The sequelæ are shrinking and atrophy of the papillary layer and of the sebaceous and sudoriparous glands and hair, and increase of connective tissue in the deeper parts of the cutis.

In this group of progressive atrophies belong the **erythromelia** described by Pick, and **acrodermatitis** described by Herxheimer and Hartmann. The malady mostly begins on the ends of the extremities and spreads from here up on to the trunk, often with a certain symmetry.

XERODERMA PIGMENTOSUM (XERODERMA; PARCHMENT SKIN).

Kaposi was the first to describe this malady and to call attention to its malignant character. The disease develops in consequence of congenital predisposition in early childhood, rarely later, and the main characteristics are yellowish-brown pigmented spots, resembling freckles; interspersed among these are small telangiectases and slightly depressed whitish areas, frequently resembling the scars of small-pox. The skin appears atrophic and dried up, resembling parchment, and is tense, and can only be pinched into folds with difficulty. The telangiectases are either punctiform or linear. The dilated vessels and pigmentation, and the whitish cicatrices, impart a spotted color to the skin.

The integument of the face, neck, dorsal surfaces of the hands, the forearms, shoulders, and trunk, more rarely the lower extremities and dorsal surfaces of the feet, are involved.

During the further progress of the disease the small vessels are obliterated, and white, shiny, atrophic little depressions, and later diffuse shrinking of the skin, are to be noticed (senilitas cutis præcox, Kaposi). As the epidermis also atrophies and exfoliates in the form of lamellæ

and becomes fissured, much disfigurement ensues, such as superficial rhagades and ulcers, narrowing of the nasal and oral cavities, and eversion of the lower eyelids.

The rapid spread and continuous atrophic transformation of tissue distinguish this disease from ordinary freckles and pigmented nevi.

Histologically, the skin shows quite analogous changes to those observed in senile degeneration, but to a much more developed degree. The chief characteristic is the striking participation of the cutis in the degenerative process. The vascular changes, consisting of new growth and obliteration, overgrowth of the endothelium, the pigmentary deposit, and projection of the rete downward, and the atrophic processes, are the precursory stages which stamp this as a peculiar disease subsequently developing into carcinomata and sarcomata.

These malignant new growths may occur in the course of a few months in various places, as the face and external parts of the ears. When this takes place the doom of such patients is sealed, as a fatal termination is inevitable. The epithelial carcinomata appear as warty formations; they increase in size, disintegrate, and soon lead to cachexia and death.

Kaposi accepted as the cause of the malady an inherited formative and nutritive anomaly of the papillary layer, and calls attention to its early appearance in childhood and its occurrence in several brothers and sisters of a family. As an exciting or contributory factor in some cases is cited exposure to intense sun rays, inasmuch as the affection is observed frequently with field workers, sailors, and children of the peasant class. The **seaman's skin,** described by Unna, is identical with xeroderma pigmentosum.

Treatment.—Mild, indifferent salves are employed to alleviate the dry skin; new growths should be extirpated in their early stages. If sensitiveness to light exists, proper measures should be taken to keep out the chemical

rays, as with the wearing of red veils, remaining in darkened rooms.

LUPUS ERYTHEMATOSUS.

Since the first description of this malady by Hebra (under the name of "*seborrhea congestiva*") and by Cazenave, one understands lupus erythematosus to be a highly chronic inflammatory affection of the skin, characterized by the appearance of circumscribed patches, unattended with ulceration, but with a tendency to cicatricial formation in the healed parts. According to our knowledge up to the present lupus erythematosus has a distinct individuality, although several, among whom Boeck was the first, have attempted, especially as to the disseminated form of the disease, to place the malady in etiologic relationship to tuberculosis. But neither the clinical nor the histologic findings and observations have as yet furnished any proof that lupus erythematosus is to be grouped with the forms of tuberculosis of the skin, or the so-called tuberculids.

Kaposi, in 1869, was the first to divide lupus erythematosus into the two forms—a chronic **discoid type** and an **acute disseminated type**; a division which, in consequence of the substantial differences of the two forms in their clinical symptoms and their course, has remained justified to the present day.

Chronic lupus erythematosus appears as small elevated spots, bright to dark red in color, mostly of shining aspect, and covered in the central part with a thin, firmly adherent scale. The beginning stage leads to peripheral extension of the patches to the so-called **lupus erythematodes discoides** (Plate 78).

These disks, the size of a dime to that of a dollar or the palm of the hand, usually occur at first on the bridge and tip of the nose, the alæ, and cheeks. The shape of the disks varies according as the peripheral extension is regular or irregular. One of the most usual varieties is the so-called butterfly form, which spreads from the bridge

of the nose to the alæ and even to the cheeks. The center of the fully developed patches is depressed, shiny, and cicatricial, and is either red or traversed by dilated vessels. The margin is redder, elevated, more succulent, and is often covered with scales or crusts; these latter are the result of marked exudation from the dilated vessels, the exudation and epidermis drying upon the surface. The inflammation begins principally in the follicles and sweat glands and spread in the cutis, and extends downward to the subcutaneous cellular tissue as well as upward to the epidermis. The exudation loosens the epidermis, and the latter exfoliates in the shape of small scales, which are adherent at first. Involution takes place in this manner: The newly formed connective tissue shrinks, atrophic scarring results, the affected areas are depressed and contract, and the cutaneous follicles are obliterated; the sebaceous and sweat glands disappear.

Another form of lupus erythematosus is known as **lupus erythematosus disseminatus** (Plate 79). In this variety the efflorescences are more numerous and make their appearance about the same time. Numerous patches or areas are scattered over the entire face and ears. The spots are dark red, slightly elevated, firm and elastic, and the overlying epidermis is fissured, exfoliates, and is studded with dilated follicular openings. When these efflorescences occur over the fingers and forearms the color is apt to be darker and they are firmer than those on the face. In a few instances the hairy scalp and the mucous membrane of the mouth have been found to be involved. In isolated instances of rapidly developing cases, under high fever, appears an intense swelling of the face (**erysipelas perstans faciei**); the condition progresses under continued high temperature rapidly to coma and death.

The malady described by Boeck under the name of lupus erythematosus disseminatus, characterized by disseminated papules, does not appear to be identical with the lupus erythematosus as above described, but to belong in the group of tuberculids; the more especially

as this form by Boeck is also lacking in the localization observed in the variety of lupus erythematosus disseminatus of Kaposi (Jadassohn).

The histologic examination discloses in the chronic form an inflammation of the cutis, consisting of edema, cell infiltration, dilatation of the blood- and lymph vessels, with a pressing apart of the elastic and collagenous fibrous tissue; also hyperplastic changes in the epidermis, secondary scar-like atrophy, atrophy of the sebaceous glands, distention of the sweat glands and their ducts.

The rather sparse histologic findings in the acute disseminated form available show a sharp accentuation of the conditions found in the chronic disease, perivascular infiltration, sometimes with destruction of the epidermis and cutis. It would appear that both forms indicate a granulation process with connective-tissue new growth.

The course of lupus erythematosus in both forms is exceedingly chronic, the affected areas remaining long unchanged, sometimes fifteen to twenty years; in one of Wilson's patients the discoid form had lasted for forty-five years.

Although the prognosis, even under such conditions, cannot be regarded as absolutely unfavorable, as lupus erythematosus may either undergo rapid involution or may terminate in cicatricial formation and slight vascular dilatation, experience teaches that many of the cases eventually die of pneumonia and tuberculosis.

It is possible, without doubt, for a spontaneous healing to ensue in any stage. But even after years (in one of Hebra's cases after twenty-one) relapses may occur, either in the same places or on another part of the skin. The behavior of the rare rapidly fatal forms has already been sufficiently referred to.

In the consideration of the **etiology** of this up to to-day unknown malady, stress has been, since its earlier recognition, laid on tuberculous antecedents or simultaneous symptoms of scrofulosis and tuberculosis. Kaposi stated that the majority of the patients were women, who were suffer-

ing with chlorosis, anemia, dysmenorrhea, catarrh of the apices of the lungs, and beginning tuberculosis. Jadassohn's observations show that 75 per cent. of the cases are women. Tuberculosis of other organs is, it is true, disclosed in the majority of the cases in the history or autopsies, but there is still lacking unquestionable proof of the causal relationship of the two diseases (the tuberculin-injection reaction observations have failed to give any substantial evidence on this point). Nevertheless, a tolerably large number of observers, as Boeck, Herxheimer, Jarisch, Saalfeld, Touton, hold upon hypothetic grounds to the view of its etiologic relationship.

We have seen a case of disseminated lupus of rather acute character spread rapidly, accompanied by pronounced disturbances of the general health, and the patient, a female, died six months later of an acute pulmonary affection.

Treatment.—In mild cases washing with soft soap or tinctura saponis viridis or absolute alcohol (H. v. Hebra) will at times be sufficient to cause the efflorescences to disappear. The application of salicylic acid plaster or gray plaster to the diseased areas is also to be recommended. Schütz recommends painting with:

℞ Liq. potass. arsenit., 4 (fʒj);
Aq. destillatæ, 30 (fʒviiss);
Chloroformi, (gtt. ij).—M.
Sig.—For external use.

In obstinate cases recourse must be had to reducing (deoxidizing) remedies—resorcin, salicylic acid, pyrogallol, etc.—to bring about results. We have had especially good effects with Lassar's method of producing exfoliation, described under Acne (see p. 50). Galvanocautery and thermocautery have also been warmly recommended. Multiple scarification followed by dusting with iodoform gives good results (Veiel). Eugen Holländer prescribes three times daily 0.5 gm. (gr. viiss) of quinia muriate;

ten minutes after taking the drug the affected areas are thickly painted with iodin tincture; after about six days discontinuance of the treatment till the crust formed by the iodin has come off and a pale, healthy skin shows itself. Following this it is usually necessary to repeat the cyclus.

We have had most excellent results from this method; but many times with this plan also the disease soon presents again. Arning freezes the diseased areas with chlorid-of-ethyl spray. The results of the Röntgen-ray treatment are uncertain.

Growths of the connective tissue, in the narrower sense of the word, have a more projecting character than the diseases just described, partaking of the nature of tumors. They are:

FIBROMA MOLLUSCUM SEU PENDULUM (FIBROMA).

Fibromata consist of rounded, usually pendulous, tumors, rarely flat, and provided with a broad base; they feel doughy, lobulated, soft, or somewhat firm to the touch, and are invested with normal skin. They generally occur on the head and rump, but in some cases hundreds of varying size may be scattered over the entire body. (Hashimoto counted in one case as many as 4503 on different parts of the body.) The larger growths prove annoying owing to tension, interference with motion, and occasionally the occurrence of inflammation or even gangrene of the overlying integument. They are regarded as hyperplasias of the connective tissue, taking origin in the deeper layers of the corium or nerve sheaths (neurofibromata), and consist at first of gelatinoid, later on of fibrous connective, tissue. The vessels are contained in the pedicle. The skin adheres to the distal end of the growth, and consequently represents a pouch, in which the tumor is suspended.

According to the tension and distortion which may exist, various changes in the glands and epithelial invest-

ment occasionally result, and owing to consequent inflammation, ulceration, and gangrene the tumor falls off. Spontaneous involution has also been observed. According to Garré, about 12 per cent. of the multiple fibromata undergo sarcomatous degeneration.

Hereditary predisposition is regarded as a causative factor, inasmuch as the tumors are frequently observed during early life. Hebra has pointed out that the patients usually are degenerates in body and mind. This is, however, not true for the majority of cases observed. Exceptionally the appearance of neurofibromata has been observed later in life (Marie and Bernard).

The **hard fibromata** appear usually as single formations, mostly on the trunk, but also on almost any other part; they appear as round up to walnut-sized tumors, which consist of tough, firm, hard connective tissue; they are always of benign character.

Treatment is exclusively surgical.

LIPOMA.

Lipomata, or fatty tumors, are outgrowths of the subcutaneous fatty tissue; they appear mostly in advancing years, and present as lobulated, soft, elastic growths. They appear either as a single tumor of polypoid shape, which may reach considerable dimensions; or more frequently as multiple growths and in smaller size. Sometimes they appear symmetric. The overlying skin is of normal appearance, is much less seldom subject to the changes of tension and pressure as observed in fibromata. According to Cohnheim, lipomata may also arise from persistent embryonal elements; sometimes they are found associated with other congenital disturbances. Lipomata show no disposition to change of form, even when of years' duration; nor does spontaneous retrogression ever take place.

Treatment is surgical.

XANTHOMA; XANTHELASMA; VITILIGOIDEA.

Xanthomata are sharply defined, flat, slightly raised or tuberous small patches, projecting from the skin. The former (**xanthoma planum**) are spots of a yellow or chamois-leather-yellow color; they are of soft consistence and usually occur on the internal or external canthi; the ears, nose, and even the mucous membrane of the mouth may also be the seat of the growths. They appear in women about the climacteric, but also in men of more advanced years, without causing annoyance apart from the disfigurement.

The second variety (**xanthoma tuberosum**) occurs in the form of tumors the size of a pinhead to that of a hazelnut. They are of firmer consistence and of irregular, lobulated construction. The lesions are red at the base and yellowish at the apex. The tumors occur on the extensor surfaces of the joints, the fingers, elbows, knees, on the nape of the neck, and in the sacral and gluteal regions. They have also been found on the mucous membranes and even in the internal organs (endocardium, wall of the aorta, etc.).

Xanthoma represents anatomically a connective-suetis tumor with interspersed specific xanthoma cells. The xanthomatous infiltration is to be found in the spaces of the connective tissue, and presents the appearance of a peculiar fat-like mass. The stratum cylindricum of the epidermis is generally markedly pigmented. According to Max Joseph, the xanthomatous process begins in the neighborhood of the vessels; the latter showing at first a peeling of the adventitia. The older xanthoma cells swell and give the impression of giant cells. Finally the cells burst, and unnucleated xanthoma masses gradually fill the entire lymph spaces. Unna and Pollitzer deny the existence of the xanthoma cells; the former considers them as infarcts of the lymph channels with fat-masses; and the latter holds they are degeneration products of embryonal misplaced muscle fibers. Many authors also

allege substantial histologic differences between the two forms of xanthoma (Leven). The latter author divides xanthoma palpebrarum clinically and histologically from xanthoma tuberosum. This latter he divides according to the clinical appearances into xanthoma tuberosum simplex and xanthoma tuberosum symptomaticum, as an example of the latter, that which arises in the diabetic, and which with lessening or disappearance of the glycosuria undergo involution.

The **etiology** of xanthomatosis is as yet unexplained. Frequently it appears in association with jaundice, disease of the liver, nephritis, and diabetes. Neusser emphasizes the occurrence of both forms of xanthoma in cholelithiasis; Kaposi and Chambard saw many cases of xanthoma tuberosum associated with jaundice from various causes; Colombini the same in pentosuria. Especially to diabetes has been ascribed as predisposing to the development of xanthoma tuberosum (Chambard, Mehring, von Minkowski, Leven, and others). In our case striking involution of xanthoma tubercles occurred twice after the disappearance of diabetes had been brought about by a course at Carlsbad. The disease relapsed simultaneously with the appearance of sugar in the urine, and at both times the small tubercles involuted when sugar ceased to appear in the urine.

Treatment.—Xanthoma planum is most readily removed by surgical procedures [also by electrolysis.—Ed.]. In multiple eruptions of xanthoma the general condition must be carefully looked into; patients must be examined for diseases of the liver, gout, diabetes, glycosuria, and nephritis. The xanthoma tubercles have been repeatedly observed to retrograde under proper general treatment. Brocq recommends the internal use of phosphorated oil and oil of turpentine.

DERMATOMYOMATA.

Myomata are rare skin lesions. They occur around the nipples, on the scrotum, and extensor surface of the arms;

are firm pea-sized tumors, which are movable with the skin. The overlying skin is more pigmented than usual; otherwise it remains unchanged.

The tumors are not, as a rule, painful on pressure, although some have been described as being spontaneously painful. They develop from the smooth muscular fibers or from the enveloping or immediately adjacent connective tissue. They start from the arrectores pilorum. In a few cases numerous vascular coils and nerves have been found along with the hyperplasia of the cells of the muscles, and such cases possibly represent the especially painful little tumors. Multiple dermatomyomata have been described by Huldschinsky and Brölemann, taking their start from the musculus arrector pili.

ANGIOMATA.

Nævus vasculosus is most commonly a congenital dilatation of the capillaries and smaller cutaneous blood-vessels, and is usually on a level with the skin. The color of the vascular nevus is mostly dark red or bluish red, and depends on the predominance of the dilatation of large vessels or small capillaries. Dilatations the size of a split pea are frequently seen scattered irregularly over the trunk; larger nævi vasculosi occur on the face (temporal region) (Plate 77), hairy margin, nape of neck, and even scattered over larger portions of the body surface (Plate 76). The larger vascular nevi occur unilaterally and may increase in breadth. The anxiety of mothers, therefore, to have the small vascular nevi in newborn children removed as soon as possible is not without foundation. While Lesser considers an angioma appearing in advancing years as the precursory stage of a carcinoma, Raff and Rosenbaum reach the conclusion, based upon extensive observation, that the senile angiomata (capillary varices) are exceeding common in old people and have no etiologic relationship with carcinomatous development. *Telangiectases* are acquired blood-vessel new formations, usually

consisting of enlarged capillaries or a pinhead- to pea-sized dilatation, with or without enlarged capillaries extending from it. Vascular dilatations resulting from venous stasis due to interference with the return circulation have been considered in their proper place. Venous dilatations often form plexuses from the size of an egg to that of a fist, which are very troublesome, as they frequently lead to inflammation. They occur on the lower extremities, in the spermatic plexus, and in hemorrhoidal veins, and must be removed by operation.

Lymphangioma.—The capillary lymphatic vessels of the skin are dilated, owing to interference with the flow of lymph, either by infiltration and occlusion of the larger vessels or by swelling of the lymphatic glands in whose domain the lymphatic vessels are situated. Should any of these small lymphatic vessels rupture, the lymphatic fluid oozes forth continuously. Pressure of a bandage may also lead to decided dilatations of the lymphatic vessels.

More extensive dilatations of the lymphatics are observed as nodular formations in a swollen area of the skin, and exhibit not only varicosities and dilatations, but many new vessels form in the corium. We have observed such swellings on the scrotum and penis. Finally, dilatations of the lymphatic vessels, accompanied by swelling and hypertrophy of the skin, often over a whole region of the body, occur, especially on the lower extremities; these are known as *elephantiasis lymphangiectodes*, and, with accompanying blood-vessel hypertrophy, closely resemble ordinary elephantiasis. In rare instances elephantiasis lymphangiectodes is noted to be congenital (Vollmer).

Lymphangioma Tuberosum Multiplex.—Kaposi and others have described numerous, partly round, partly elongate, brown-red nodules lying in and movable with the skin, situated on the trunk and region of the neck. Not having any personal experience with this rare skin disease, we refer the reader to Kaposi's treatise on skin diseases; it is to be considered as belonging to the domain of tumors of the lymph vessels.

RHINOSCLEROMA.

The peculiar disease called rhinoscleroma was described by Hebra and Kaposi in 1870. The affection attacks the nose and spreads very slowly over the skin and cartilages of this organ and neighboring parts. It may further involve the posterior part of the soft palate, the isthmus, larynx, and trachea. The disease spreads only by contiguity from the starting-point. Rhinoscleroma attacks individuals about the period of puberty. The patients are usually not robust. Although it cannot be regarded as a specific hereditary disease, a certain predisposition is generally thought to exist. One of the alæ or the septum is attacked by the disease and the shape of the nose changes gradually without exhibiting decided signs of inflammation. The nose widens and feels rigid and immobile to the touch. Owing to hypertrophy of the inner walls, stenoses and even complete occlusion of the nares occur. After months the whole organ, anteriorly as far as the lips and posteriorly as far as the choanæ, becomes involved. The external picture varies, and depends on the presence of tuberosities projecting over the level of the skin or on the presence of uniform hypertrophy of the skin and cartilages, resembling plaques. The color may be of various shades of red, but is usually brownish or bluish red. Blood-vessels are seen running over the surface, which is smooth or finely wrinkled, and shiny. In the same manner as stenosis of the nasal cavity results, the functions of the lips are also interfered with. We also meet with various distortions and constrictions in the isthmus faucium, which not infrequently remind one of syphilitic sequelæ.

The patient's appearance suffers considerably, and the resulting occlusion of the nose and stenosis of the entrance to the larynx and mouth are a source of great annoyance. The diseased areas are sensitive to pressure. The affection is chronic, extending over years, without necessarily any change in the general health.

Most observers regard the disease as inflammatory, in which the infiltration is partly absorbed and partly converted into connective tissue.

Specific bacilli have always been found in the tissue of rhinoscleroma since Frisch called attention to their presence. Paltauf and Eiselsberg found capsulated bacilli in protoplasmic masses, which correspond to the cells of rhinoscleroma or degenerated nuclei, first described by Mikulicz. The rhinoscleroma microörganisms appear as 2- to 3-μ long bacilli, or as ovoid, nearly round, capsulated cocci, occurring usually as diplococci, which can scarcely be distinguished from pneumonia cocci.

The **prognosis** is unfavorable; it is impossible to stop the process by any treatment. Surgical procedure is indicated when adhesions and hypertrophy have advanced so far as to interfere with the functions of the parts.

TUBERCULOUS DISEASES OF THE SKIN.

In this section we embrace those pathologic changes in the skin due to the tubercle bacillus; they show great variety in appearance, course, structure, and pathogenesis.

The subject of tuberculous diseases of the skin has in late years materially widened, inasmuch as many affections whose etiology was formerly considered obscure have been shown to have an etiologic relationship to tuberculosis. As proof of the tuberculous character of a disease four requisites are generally demanded: 1, Characteristic histologic findings; 2, the positive demonstration of tubercle bacilli in the tissue; 3, the demonstration of the possibility of communication through animal experimentation; 4, the positive tuberculin reaction. While in lupus vulgaris usually all four of the required conditions can be filled, in other forms of cutaneous tuberculosis of the skin, especially as relates to the last two of the requirements, such demonstration is not always so successful. In spite of this, however, the histologic-bacterial findings speak in these instances unquestionably for a tuberculous malady. On

account of the varying degrees and appearances of the different skin conditions in this class and the lack of demonstrable proof of all four of the above conditions, the hypothetic premises of a variable degree of action of the exciting agent are assumed: that not only may the bacilli be responsible but also their toxins, and, further, that it has been pretty well accepted that the various maladies may be due to bacilli of different virulence, as this is likewise believed as regards other microörganisms.

The bacillus may gain entrance to the skin in various ways. External tuberculous material may be either implanted (exogenous inoculation tuberculosis) or the material originates from an already diseased body—*e. g.*, sputum, saliva, feces, and urine (tuberculosis due to auto-inoculation). Certain external predisposing causes, however, are necessary for the tubercle bacillus to establish itself, inasmuch as the skin does not appear to be favorably disposed to tuberculous disease. The tubercle bacillus may find such points of attack where the skin is injured or where cutaneous disease exists—briefly, when wounds of the integument are present. On the other hand, tuberculosis may find its way from a neighboring organ into the skin (tuberculosis due to contiguity)—*e. g.*, from a primarily diseased testicle to the scrotum, or from bone to the overlying soft parts. Finally, the bacillus may gain access to the skin from a diseased organ by metastasis.

Upon the basis partly of the clinical symptoms and partly also upon their course we distinguish six forms of cutaneous tuberculosis:

A. Lupus;
B. Scrofuloderma;
C. The tuberculous ulcer;
D. Tuberculosis verrucosa cutis;
E. Tuberculosis fungosa;
F. Tuberculide (folliclis).

To these forms lichen scrofulosorum as well as lupus erythematosus stand undoubtedly very close; for both of

these affections, already elsewhere described, the tuberculous character is, however, as yet unproved.

Although it would be gratifying if the clinical symptoms of the above-named forms of cutaneous tuberculosis were always distinctive, the fact must be emphasized that several varieties may exist alongside of one another, and that frequently one develops from another. Thus, for instance, tuberculosis verrucosa may change into lupus; lupus may develop from a scrofuloderma which has already cicatrized (Riehl). Along with tuberculous ulcers subcutaneous nodules of scrofuloderma, etc., develop. Taken as a whole, however, this, as with other multiform diseases, usually presents in different individuals a distinct type or variety. This cannot be attributed alone to a hereditary predisposition to tuberculosis, but also to individual idiosyncrasy, which reacts differently to the same excitant.

All these varieties may terminate spontaneously [exceptional.—Ed.]. The cicatricial formation which in such cases, as in all ulcerative processes, denotes a cure, is, according to the duration and intensity of the disease, at one time slight, at another time more marked, and may lead to shrinking and other consecutive changes. Various authors have called attention to a temporary lull in the course of lupus, and have connected it with possible conditions in the organism itself (pregnancy) or with external influences of temperature and weather.

A. LUPUS.—LUPUS VULGARIS.

Lupus is the most frequent form of cutaneous tuberculosis, and occurs principally on the uncovered parts of the body, as the face and hands; and to a less extent on the scalp. It begins in many cases during infancy or early childhood, and is met with more frequently in females.

Regarding the frequency or distribution of lupus vulgaris in the various countries statistics show no differences worth mentioning. Only in Japan a remarkable rarity of the

disease has been noted, and the Japanese physicians explain this as due to the practice of the national habit of daily washing with hot water. [The author could have well added the United States as showing also a remarkable infrequency of the disease as compared with other countries.—Ed.]

Lupus begins clinically with the appearance of pinhead- to hemp-seed-sized nodules, which are yellowish gray or brownish red in color. These feel soft to the touch, and lie in the beginning in the skin, and only after longer duration do they stand out, and become covered with smooth, shining epidermis. At first they are embedded in the skin and project only after they have persisted for some time, and are covered with a smooth, shiny epidermis. The typical nodules at first are also flat and isolated; the various clinical pictures of the disease are due to the changes which take place—to the lesions becoming contiguous and confluent, etc.

The disease soon begins to spread in areas; the isolated foci are usually sharply defined at the periphery and are surrounded by inflammatory infiltrated cutaneous tissue; the round-cell accumulation and infiltration follow the vessels. This massed cellular infiltration involves all the cutaneous parts. The elastic fibers, hair follicles, sebaceous and sudoriparous glands are either destroyed or only their débris remains. The changes in the epidermis are connected with the processes in the cutis; once we saw rapid death of the epithelium take place; but usually the inflammation and irritation lead to hypertrophy of the epithelium, especially of the epithelial cones extending toward the cutis. The surface of the lupus foci is either smooth or covered with scales; or hyperkeratosis is noted, giving rise to superficial verrucosities.

We usually meet with sclerosis of the inflammatory infiltrate around the lupus tissue, which leads to absorption accompanied by cicatricial formation (**lupus sclerosus**). Less frequently, and only on account of special causes (spread of inflammation, secondary infection), do

breaking-down and ulceration of the lupus tissue result. Dry caseation is rare in lupus.

Owing to these anatomic changes, to which we have briefly alluded, and especially to the extension—already mentioned—of the lupus growths, we differentiate clinically various forms.

The disseminated form, **lupus miliaris,** is found usually on the face, and especially on the nose, cheeks, and forehead. To this form belong those cases previously described, mostly as **lupus disseminatus follicularis** of Tilbury Fox, **acne telangiectodes** of Kaposi, appearing as papules; they were thought to have a relationship to acne, but had nothing to do with this latter, inasmuch as under this last name we now understand an inflammation of the sebaceous glands. In these cases of lupus miliaris there is no inflammatory redness, but a brownish-red discoloration, with no surrounding inflammatory halo. These papules represent granulation tumors or growths, whose tuberculous character, and their relationship to lupus, have been proven repeatedly on experiments with guinea-pigs by Jadassohn, Besnier, and others. The papules are distinguished by their remarkable persistence; on their apex are often seen milia (epithelial cells), in consequence of which they were named **colloid milium.** Owing to their pustular-like appearance they have, indeed, at first glance, a resemblance to acne.

When shining lupus tubercles are arranged in creeping or spreading rows, which in the middle or traversed portion are ill-defined, white cicatricial scars, it gives rise to the variety known as **lupus serpiginosus** (Plate 81).

When several or more lupus nodules coalesce or are heaped or crowded together so that the individual tubercles composing it can no longer be distinguished, there result solitary pea- to apple-sized nodes (**lupus tumidus**) (Plate 86). This form is to be found mostly in the face of children, and has a very mild course.

Papillomatous warty lupus forms (**lupus verrucosus, lupus papillaris hypertrophicus**) (Plate 89) arise

from hypertrophy of the horny layer and acanthosis; upon removal of the hypertrophic vegetations the lupus tubercles are disclosed.

Through confluence of some ulcerated tubercles, whose epidermis is thinned or torn, arise **lupus exulcerans** (Plate 82).

The lupus ulcers are usually covered with dark-colored crusts, the ulcerating surface underneath, on a level with the skin, appears red and moist, bleeds readily, and resembles granulating wounds.

The mucous membranes of the nose and oral cavity may be the seat of lupus nodules for a long time without giving the patient especial annoyance. They are met with on the gums, palate, tongue, and larynx, as brown-red, usually ulcerating and readily-bleeding nodules, the size of a pinhead to that of a split pea. When they coalesce and form large plaques the surface is irregular and covered with gray, proliferating epithelium; or if breaking down and disintegrating, form flat or fissured deep ulcers.

As already mentioned, lupus extends from the mucous membrane upon the external skin, and *vice versâ*. Defects of the palate, due to ulceration and shrinking, and also depressed contractions of the tongue—the latter are frequently associated with firm nodular swelling in the neighborhood—are of not unusual occurrence. We have often found polypoid vegetations in the nasal cavity along with ulceration and crust formation, completely closing the affected half of the nose. These are distinguished from translucent mucoid polypi by their granulating surface and by their tendency to bleed; mucoid polypi are covered with a smooth mucous membrane. Perforation of the septum, cicatricial contraction, and distortion are the sequelæ which frequently follow after the disease has existed for years.

The exterior of the nose, and especially the alæ, are frequently the points first attacked by lupus.

The disease spreads gradually from the tip to the root

of the nose. Papillary elevations at the margin of the ulcers, which are continually disintegrating, become covered with brown crusts and gradually lead to destruction of the entire cartilaginous and, exceptionally, of the osseous structure. Lupus also extends to the cheeks and often to the margin of the lower jaw and to the neck; the submaxillary glands are not infrequently diseased at the same time and consequently suppurate. Lupus tumidus is frequently met with on the lobes of the ears.

Lupus of the eyelids leads to ectropion and consecutive diseases of the bulbus. It is occasionally primary—although rare—on the conjunctiva of the bulbus and extends to the cornea. On the trunk, especially on the nates, we often meet with the papillary, verrucous forms; and with the serpiginous varieties on the extremities. Owing to cicatricial contraction, the articulations become fixed and the parts are deformed and become useless. Deformities of the hands, especially unsightly hypertrophies, are attributable to disease of the lymphatic vessels (Plates 83, 84, and 85).

In rare instances lupus of the scrotum and penis is observed (Wallart).

The primary lupus papule presents histologically a tubercle which consists, in the central part, of epithelioid and giant cells, and on the periphery of intensively colored leukocytes. They are, as a rule, epithelial tubercles. In general, the tubercle bacilli are very scanty in lupus tissue; mostly several are to be found in the giant cells. The tubercle bacillus can gain access to the skin either by way of the circulation or by means of tuberculous gland processes, or through infection from without.

Lupus pursues an exceedingly chronic course. Beginning usually between the ages of ten and twenty years, it extends very slowly, retrogressing on one side, and spreading serpiginously at the periphery; undergoes involution—*i. e.*, cicatrizes—often completely to recur again. Owing to mechanical damage or irritation or intercurrent affections,

erysipelas, etc., inflammation, disintegration, and ulceration result, which frequently lead to very great destruction of the face, nose, the soft and hard palates, etc. Spontaneous permanent healing is only observed in lupus tumidus in early life.

Erysipelas recurs frequently in lupus subjects, leaving behind edema and connective-tissue growth, in consequence of which the case can, in its further course, develop on the extremities to tumor-like thickenings (**lupus elephantiasticus**).

The spread of the tuberculous process along the lymphatic interstices and vessels, owing to the attending inflammation, leads to elephantiasic transformation, which may involve the soft parts and even the bones.

Syphilitic lesions occurring in lupus infiltration or in a resulting cicatrix may occasionally complicate the disease. The expression "lupus syphiliticus" appears to us, however, unnecessary, inasmuch as it is apt to lead to confusion. Under lupus were originally included by classical authors all ulcerative processes of the skin with central healing and peripheral extension; they later differentiated lupus vulgaris, lupus erythematosus, and "lupus syphiliticus"—a serpiginous spreading, ulcerative syphilid.

Syphilitic ulcers may, *vice versâ*, owing to infection with tuberculous material, be converted into tuberculous ulcerations. In the differential diagnosis between syphilis and lupus, the characteristic feature of the syphilid must be kept in view, as the darker color, the want of peculiar tubercles and scales, the specky-gray yellowish-coated ulcers, the sharp definition, and other signs of syphilis.

Finally, we will briefly refer to the coexistence of carcinoma and tuberculosis. Carcinoma appears more frequently in a lupus cicatrix than in fresh lupus tissue. It starts from the rete or from the glandular organs of the skin, and does not originate, as many authors have thought, from transformation of lupus tissue into carcinoma.

In a case recently published by Bernhardt, a marked

case of lupus of the face in a boy retrogressed under the influence of a variola attack. The retrogression of the lupus tissue was demonstrated in sections taken both before and after the attack of variola. Philippson calls attention to the fact that under lupus there are generally two fundamental processes understood—the primary and the secondary lupus. The secondary lupus begins in childhood and continues throughout life; the primary lupus develops in adults and is really a tuberculous granuloma.

B. SCROFULODERMA (TUBERCULOSIS CUTIS COLLIQUATIVA.)

The primary lesion and clinical feature of this disease is the soft nodule. This is characterized by colliquation and formation of a fluctuating tumor. All the pathologic processes in scrofuloderma have their starting-point in the subcutaneous lymphatic glands and channels; and in some instances even in diseased bone; exceptionally they may originate primarily in the skin. Inflammation and new formation of nodules take place beneath the still-movable skin. Later the nodular infiltration softens, the overlying skin is firmly attached and finally broken through, and an indolent, undermined ulcer results. When the process extends, new tubercles, fistulæ, ulcerations, and cicatrices form. Occasionally dispersed tubercles (*gommes scrofuleuses* of the French) are found on parts of the body where we are not accustomed to meet with lymphatic glands. We have observed numerous abnormally situated lymphatic glands in syphilitic individuals, and agree with Jadassohn that subcutaneous tuberculous nodules occurring in such localities should be regarded more often as abnormally situated lymphatic glands.

Such typical cutaneous and subcutaneous tubercles also occur in the course of large lymphatic vessels, and are subsequent to the skin affection (Plate 85), or occur independently of such a condition.

Histologically the scrofulodermata present the characteristic tuberculous tissue with giant cells and epithelioid cells, with caseation and abundant permeation of leukocytes. The tuberculous inflammation is characterized by being more sharply defined than lupus and by the greater abundance of pus corpuscles containing fragmentary granules. The bacilli are few in number; experimental inoculation, however, succeeds better than that made with lupus tissue; and the animals experimented upon perish more rapidly of general tuberculosis. This increased virulence corresponds to the clinical facts, that individuals with scrofuloderma generally present severe general symptoms of tuberculosis and scrofulosis.

C. THE TUBERCULOUS ULCER (TUBERCULOSIS ULCEROSA CUTIS).

This form of local tuberculosis, also known as **miliary tuberculosis of the skin,** is usually associated with grave general tuberculosis, and is due to auto-inoculation or to extension from the mucous membranes. It occurs in the cavity of the mouth, on the lips, nostrils, anus, and genitalia. The miliary tubercles (formation of lymphoid cells predominates), the size of a pinhead to that of a hemp-seed, show a great tendency to softening accompanied by destruction of the diseased tissue of the skin. A superficial ulcer with a torpid base results, whose margins are serrated, eaten away, and undermined, and with outlying new lesions at the border. At the periphery depressions may occasionally be seen after the miliary tubercles have disappeared, or small whitish-yellow nodules are present. The ulcers, especially on the mucous membranes, show a tendency to papillomatous vegetations. This form can also be exceptionally contracted through inoculation from without; Neumann observed miliary tuberculosis of the skin in children who were infected by the tuberculous sputum of the operator in ritual circumcision.

In this form of cutaneous tuberculosis the bacilli are mostly present in abundance; the prognosis, dependent upon the severe general symptoms, is grave.

D. TUBERCULOSIS VERRUCOSA CUTIS.

This form of cutaneous tuberculosis, first described by Riehl and Paltauf, is characterized by warty, papillary outgrowths on the surface and by the absence of ulcers and a dearth of lupus nodules; pustules, however, often develop (Plate 93). It occurs on the fingers or dorsal surface of the hand, and is found in butchers, attendants in morgues, and in physicians—in brief, in those having to do with manipulation of tuberculous material, and is, consequently, the result of exogenous inoculation. Concerning the question much discussed at present of the communicability of bovine tuberculosis to human beings, exact observations of such cases is of positive significance; two such observations made recently by Joseph and Trautmann appear to confirm the possibility of such communicability. Postmortem tubercles, scrofuloderma, or tuberculous ulcers may also result from infection of this kind.

The **postmortem tubercle** is only a variety of tuberculosis verrucosa cutis, and is distinguished from the latter by its less extent, as well as through the tendency to regional lymph-gland swelling. It begins mostly on the fingers as a small pustule, which gradually develops into a papillomatous growth; and in its further course, in consequence of a mixed infection with pus-producing organisms, can show redness, inflammation, and suppuration. Usually, after years' duration, healing with a central cicatrix results.

Tuberculosis verrucosa cutis is a localized process. The grayish-white, warty papillomata may appear singly or in groups, and exhibit a tendency to heal in the center and to spread at the periphery. Fully-developed tubercles are found in the most superficial layers of the cutis, and contain bacilli, with coexisting small-cell, diffuse, infiltra-

tion. The pustules mentioned above are minute miliary abscesses in the small-cell infiltration, associated with collection of pus beneath the epidermis. Cocci have been found in the purulent matter of the pustules, which the authors already mentioned regard as the pyogenic factors. The epidermal involvement, the proliferation of the stratum Malpighii and corium, and extension of the rete, which is traversed by leukocytes, are the result—as is the case in many other diseases—of inflammatory processes in the superficial cutis, in which, as has been referred to, the deeper layers of the epidermis participate, with proliferation and cornification of the upper layers. The malady is observed in greater numbers in those in mountain districts.

E. TUBERCULOSIS FUNGOSA (FUNGUS CUTIS).

Riehl has described a tuberculous infiltration beginning deep in the bone and periosteum and progressing upward toward the soft parts, which leads to formation of fistulous tracts and to soft superficial growths, giving rise to mushroom-like tumors, which disintegrate *de novo* and form ulcers. We have described such a variety on the lower extremity (Plate 87). In such a case it is quite proper to drop the term lupus, inasmuch as in this instance, as in tuberculosis verrucosa, lupus nodules do not occur, the disease being characterized solely by infiltration and subsequent disintegration, but not by colliquation, as is the case in scrofuloderma.

According to Riehl, bacilli are more numerous in this manifestation than in scrofuloderma or lupus. The affection differs from scrofuloderma by its firmer consistence and the less tendency to softening.

F. TUBERCULIDE (FOLLICLIS).

This malady, described under the different names of **lupus erythematodes disseminatus** (Boeck),

acnitis (Barthèlemy), **acne varioliformis** (Pick), **dermatitis nodularis necrotisans** (Török), and others, is to be considered, in the light of the already rich observation material, as a distinct disease. The primary efflorescence of folliclis appears as a pea-sized, pale-red, roundish inflammatory papule, which scales slightly and shows centrally a small depression. The papule represents a follicular or, more frequently, a perifollicular inflammatory process. Slowly there begins in the central portion a purulent liquefaction, which heals with scar formation. In consequence of coalescence of such papules arise irregularly formed pea- to finger-nail sized aggregations of tolerably firm consistence (Plate 80). The efflorescences are to be found most frequently on the extensor surfaces of the extremities, on the forearms and hands, but also on the lower leg and foot; much less frequently on the trunk. The affection is usually without subjective symptoms.

Scarcely any other disease has given rise to so warm a discussion concerning its pathogeny as the one of which we are speaking. After Boeck had accepted the eruption as lupus erythematosus disseminatus, and held to the origin of the same through the action of the toxins of the tubercle bacillus upon the vasomotor centers, Darier declared the lesions due to the lessened virulence of weakened bacilli, and gave them the name of tuberculides. Hallopeau endeavored to bring together the various published observations on tuberculides into a system, and divided the tuberculous manifestations of the skin, excepting lupus, into four groups: 1. Those that are produced by the tubercle bacillus itself; 2. Those in which the bacillus is modified; 3. Those arising from the toxins; and 4. In which tuberculosis is only a favorable soil for, in other respects, non-tuberculous cutaneous disease. He further stated that bacillar forms are only to be found in certain regions; those due to toxins are disseminated or exanthematic. This system could not gain general acceptance, since on the one hand very different processes

were brought under the category of tuberculides, and, on the other hand, the histologic investigations did not show the characteristic tuberculous inflammatory appearances with termination in necrosis and cicatricial atrophy. Further, in the great majority of cases, tubercle bacilli could not be demonstrated in the tissues. Besides, generally the tuberculin reaction was likewise uncertain. Most authors have, therefore, up to the present time (Jarisch, Jadassohn, Kreibich, and others) maintained a reserve on this question, and are awaiting further investigation and observations.

Only in the most recent periods, thanks to the investigations by Hartung and Alexander, the tuberculous nature of folliclis becomes more and more probable. Especially are the last investigation results by Alexander of great significance concerning this question. Alexander has looked upon the extremely chronic folliclis, to a certain extent, as a projection of a visceral tuberculosis upon the skin. The papule arises in consequence of an embolic process. From any tuberculous center in the interior of the body the tubercle bacilli gain entrance into the circulation and provoke at first a tuberculous end- or peri-arteritis of the small arteries of the subcutaneous fat tissue. From here the tubercle bacilli find their way in the tissue continually, and give rise to tubercle with caseation, necrosis, and vessel changes (complete endarteritis obliterans). Perhaps the scanty bacterial findings and the so-seldom positive inoculation results can be explained by the suggestion of Darier—the acceptance of a tubercle bacillus of weakened virulence.

To the tuberculides have been added the already described lichen scrofulosorum, acne cachecticorum, and erythema induratum.

Acne cachecticorum belongs to the group of acneform tuberculides, and appears as millet-seed to bean-sized semiglobular or conical infiltrations of livid or brownish color around about the follicle. The inflammation originates in the hair follicle, and not in the sebaceous gland,

and for this reason has nothing to do with acne. The lesions are mostly on the trunk, and break down in a short time to ulcers of irregular borders, and heal with a correspondingly irregular-shaped scar. The affection is an exceedingly chronic one, and it is to be found more commonly in the scrofulous and tuberculous, or in others otherwise of impaired nutrition. Histologically, it presents a granulation tissue with giant cells. According to Gautrier **angiokeratoma** belongs also to the tuberculides.

Erythema induratum (Bazin) appears generally on the outer side of the ankle, on the leg and thigh, less frequently on the upper extremities, in the form of pea- to walnut-sized, bluish-red nodules. As with folliclis, in its further course the nodules lying in the cutis show on the apex a thinning and softening of the epidermis; from the fistulous opening thus resulting there is discharged a serous or sero-purulent liquid. Finally, this heals with a circumscribed depressed scar. From coalescence of several or more lesions plate-like infiltration can arise. If there is developed an underlying edema, the skin can appear as if fixed to the subjacent tissues. The malady has an eminently chronic course.

The histologic examination of a nodule appears in the majority of cases to speak for the tuberculous nature of the affection. Hartung and Alexander were able to demonstrate the presence of giant cells in the infiltrated connective tissue around about the vessels. Mantegazza found in the fat tissue tubercle-like masses and thrombosis of the vessels.

The malady is most frequent in children and in young women, and is repeatedly found associated with other scrofulous and tuberculous symptoms. The tuberculin reaction, up to the present, has been negative; the attempts of inoculation in animals has likewise been unsuccessful. Brunsgaard has described an **erythrodermia exfoliativa universalis tuberculosa.**

Treatment of Cutaneous Tuberculosis.—Internal

treatment must be directed to improving the general condition; any direct influence on the skin affection from the remedies recommended is not to be expected. Success can only result from local treatment carefully planned. For the purpose of producing destruction of the diseased foci and areas the following methods are used: Volkmann's spoon, thorough scarification of the affected patches (Balmanno-Squire, Vidal), cauterization with Paquelin's cautery, galvanocautery, thermocautery; excision followed by transplantation—a procedure which in expert hands leads to good results (Lang).

For the purpose of producing destruction by chemical means the *caustic pastes* are employed, as the Vienna paste (quicklime, 4 parts; dried caustic potash, 5 parts), zinc-chlorid pencils (obtained by fusing zinc chlorid and potassium nitrate, or zinc chlorid and potassium chlorid, with a cover of tinfoil), Canquoin's paste (zinc chlorid and rye flour, equal parts), Landolfi's paste (zinc chlorid, 3 parts; bromin chlorid, 5 parts; chlorid of antimony, 1 part). These pastes act on the healthy skin as well as on the diseased skin.

Cosme's paste (arsen. alb., 1 (gr. xv); cinnabar. factitiæ, 3 (gr. xlv); ung. emollient., 24 (℥vj)), acts by election—*i. e.*, it destroys the lupus nodules, but leaves the neighboring healthy skin intact. Elective action can, of course, be also obtained with the silver-nitrate stick, and with cauterization with carbolic and lactic acids and pyrogallol.

We have to note very satisfactory results with a 20 to 25 per cent. ointment of pyrogallol. The pain which the application generally produces is not great, and may be diminished by adding orthoform. After several days or longer the formation of the eschar in the lupus infiltrations is complete; separation and cicatrization are allowed to terminate under an indifferent (boric acid) ointment.

According to the Unna-Scharf method, sharpened pieces of wood (toothpicks, shoemaker's pegs, etc.), which have been lying for a few days in the following solution, are introduced into the lupus foci:

℞ Hydrarg. chlorid. corros., 1 (gr. xv);
Acidi salicylici, 10 (ʒiiss);
Ether. sulph., 25 (f ʒvj gr. xv);
Ol. olivæ, ad 100 (f ʒiij ʒj).

All the wooden stumps projecting over the level of the skin are then cut off with scissors and the surface thus treated is covered with any kind of gutta-percha plaster; the best is Unna's gutta-percha plaster of mercury and carbolic acid. After removal of the plaster the surface is seen to be covered with thin pus. The pieces of wood are removed, the surface is cleansed with an alcoholic solution of corrosive sublimate or ether, and the following powder is introduced into the little depressions made by the pieces of wood:

℞ Hydrarg. chlorid. corros., 0.10 (gr. iss);
Magnes. carbon., 10 (ʒiiss);
Acid. salicyl., 5 (ʒj gr. xv);
Cocain. muriat., 0.50 (gr. viiss).

The surface is then again covered with a plaster.

Schütz, under an anesthetic, removes all soft tissue with the sharp spoon, and very carefully scarifies the floor of the wound and about three-fourths to one centimeter of the surrounding healthy border. The entire wound is then repeatedly painted with a cold saturated alcoholic solution of zinc chlorid, to which a little pure hydrochloric acid has been added to make it keep and remain clear. Very severe pain follows this procedure; the area operated upon and the surrounding tissue swell moderately. Compresses of boric-acid solution cause the symptoms to disappear gradually, and in one to two days the wound is clean. An ointment of pyrogallol and vaselin (1 : 4) is then applied; this should be changed three times daily. On the fifth day the ointment is replaced by compresses of boric-acid solution. After the eschar has separated, the parts are again treated with the

pyrogallol ointment, and after a suitable interval, during which compresses of boric-acid solution are again applied, the pyrogallol ointment is used for the third time. Cicatrization takes place under empl. hydrargyri, iodoform bandage, or boric-acid ointment.

Elsenberg has recommended parachlorphenol as a caustic. The other remedies which have been advised, such as injections of thiosinamin (H. v. Hebra), cantharidin (Liebreich), tuberculin (Koch), tuberculocidin (Klebs), have not stood the test of unbiased criticism.

While formerly the treatment of the various forms of cutaneous tuberculosis with, as just outlined, the mechanical, chemically destructive remedies, and surgical removal of the diseased tissue (with supplementary grafting) predominated, and, in spite of all, often failed, we are now, since a comparatively recent period, in possession of methods which are capable, with almost absolute certainty, of curing these grave diseases: the treatment with the Röntgen rays and the light treatment according to the method of Finsen. As to the details of these methods, and the special indications, we must refer the reader to the text-books on radiotherapy. It suffices here to say that the foregoing measures—those previously solely used —still have their application as helpful aids; that some (more especially where it concerns smaller areas) employ the method of excision in order to avoid the tedious radiotherapy. However, the results of these new acquisitions to our therapeutic resources are so remarkably favorable that one can most warmly commend their employment, especially in tuberculous diseases of the skin.

LEPRA.

Leprosy is a chronic infectious disease, due to a specific bacillus, and consists of the formation of granulation-tissue growths of varying character and extent. It is one of the longest-known diseases, and was at different periods in the individual countries of changing intensity and

extent. A perceptible increase in Europe was observed in the second half of the nineteenth century; since which time dates our more exact knowledge of the nature of the malady.

In Europe it is most common in Norway, the Swedish, Finnish, and Russian coasts on the East Sea; in Asia, in India, China, Africa, Egypt, Abyssinia, Morocco; and in America in California and Mexico, in Australia, and the Sandwich Islands. Its greatest mortality seems to have been reached in the Sandwich Islands. While in all parts of the world are large districts where the disease is endemic, sporadic, introduced cases come under observation in all large cities.

Two chief forms are usually described: *lepra tuberosa* and *lepra anæsthetica seu nervosa*. As the essential cause is the same in both, it can be readily understood that mixed forms are frequently encountered. There are in both certain sites of predilection on the general surface, although leprous nodules are constantly found in the liver, spleen, lymphatic glands, and scrotum in both forms. Inasmuch as local anesthesias are also found in occasional cases of lepra tuberosa, the expression or term **nerve leprosy** is to be preferred to that of lepra anæsthetica. According to von Bergmann, the chief difference of the two forms lies in the fact that lepra tuberosa shows predominantly the character of hyperplasia, producing massive infiltration, up to colossal, growing nodes; and that the lepra nervorum shows the character of atrophy.

Lepra tuberosa, or **tubercular leprosy** (Plates 94 and 96), attacks chiefly the integument and the mucous membranes of the nose, palate, roof of the mouth, larynx, and pharynx.

On the skin the first changes show themselves in the form of infiltration; the skin in one or more places, over areas of several centimeters, becomes elevated and assumes a brownish-red or dull-red color. In the region of the infiltration the sensibility disappears partly or completely, and on hairy parts the hair of the affected area falls out.

After a longer or shorter period (up to several years) there develop upon these patches nodular and tubercular growths; they appear as papular lesions, brown to copper-brown in color, and gradually increase in size. In the beginning scattered or discrete, they may later form by confluence diffuse masses with a rough, uneven surface. The size of the lesions or patches may vary between that of a pea and an extensive tumor-like mass. They are hard in consistence, and the skin sensibility is reduced or abolished. The favorite site for the tuberculous lesions is the face, especially the forehead, eyebrows, nose, and lips; likewise the upper and lower extremities, especially the extensor aspects. In consequence of the occurrence of shapeless tumors on the lobes of the ears and in the face, the facial expression can become a horrible one (**facies leonina**) (Plate 95). In the beginning stages the face has merely a bloated appearance and is darkly pigmented. The pigmentation of the leprous areas increases often with the duration of the disease, and can finally assume a brownish- to blackish-color tone.

After variable duration the tubercles undergo changes, either becoming fibrous with atrophy, or softening and breaking down. Ulcerations covered with grayish coating and with callous borders are the result of this disintegration. Direct suppuration of the nodules is somewhat rare. The ulcers extend deeply to sinew and bone, the latter being laid bare and necrosing; at times also the joints are opened up in this manner.

On the mucous membranes the lesions show themselves either as small papules or tubercles, or as round, flat infiltrations, which become ulcerated and may heal with cicatricial shrivelling. The results are often conspicuous disturbances of the affected part—disappearance of the cartilaginous nasal septum, the soft palate, and the epiglottis; stenosis of the larynx is one of the most common occurrences (vox rauca leprosorum). Also on the conjunctiva bulbi characteristic nodes often develop, especially on the corneal border. Glück emphasizes the frequency

of the lepromata on the genital organs (more than 95 per cent.). In 75 per cent. the testicles were implicated; in 67 per cent. the epididymis. Glück and Wodynski describe in six cases an oöphoritis chronica leprosa. Oppenheim observed a diffuse leprous atrophy of the skin.

The disease has a remarkably regular and progressive course, inasmuch as new lesions are always presenting themselves. The new outbreaks arise, as with the initial eruptions, under febrile action; erythematous reddening of the affected parts presenting, which is soon followed by the formation of tubercles and nodules. At the site of the older lesions, usually at the time of the fresh outbreaks, changes are noted to take place, miliary abscesses or blebs arising, either of which may end in ulceration.

According to von Bergmann, the number and size of the individual infiltration furnish no standard for the prognosis, inasmuch as patients with very large lepromata can remain relatively well for years. Generally the appearance of the individual nodes is unattended with any marked subjective symptoms. Only in occasional instances they arise with high fever and erysipelatous reddening of the attacked parts. In the large majority of cases in the nodular form of the disease the sensibility of the skin is retained. Only seldom are observed, for example in the lower forearms, trophic disturbances of the skin with hyperesthesia or anesthesia; in these cases one finds a direct change of the nodular form into the nervous form. On the other hand, the reverse is extremely seldom met with: a case beginning with anesthetic spots and changing into the typical nodular form.

Lepra Anæsthetica seu Nervosa.—Anesthetic leprosy is characterized by sensibility and trophic disturbances of the skin and muscles, the new tissue formation, which produces the nodose growths of the tubercular form, remaining in the background or entirely wanting.

The disease begins as a leprous polyneuritis. Its substratum is the leprous deposit, with but slight granulation-tissue formation (leproide) in the peripheral nerves. In

the early stage rounded spots appear, often confluent, and for the most part symmetric, of a bright, later dark-red color, which in time changes to a brown or dark brown: The spots grow by peripheral extension to palm size, and usually show a slightly infiltrated edge and an atrophic center. The more recent the eruption the wider the border of infiltration. With increasing atrophy the color becomes paler and paler, changing to a yellowish brown, the pigment finally disappearing, so that the atrophic areas are then lighter in color than the surrounding skin. The increase in the affected area takes place by the gradual creeping outward of the infiltration, while the inner portion atrophies. Through this manner of spreading and through confluence of neighboring patches map-like areas are produced. The attacked parts are completely anesthetic.

The sensibility and atrophic symptoms are the predominant characteristics of this type of leprosy. Soon follow deep-seated disturbances of sensibility, first thermo-anesthesia, later complete anesthesia of the skin, and finally anesthesia of the deeper parts, muscles, and bones.

Among the atrophic disturbances the first are atrophies of the muscles, with preference for the thenars (Aran-Duchenne type), the interosseals, and the extensor muscles of the hands. On the lower extremities the first muscle to be attacked is usually the extensor of the toes. Further, degenerative processes invade certain nerves, especially the facial, mostly unilaterally only.

In addition to those already described, the atrophic disturbances of the skin are ulcer formations—pressure ulcers—which are observed most frequently in the form of perforating ulcer of the foot, and sometimes producing a resemblance to Madura foot; such a form was observed by A. Plehn. Further, there appear in the palm deep fissures and rhagades, which may extend to the fingers and to the dorsum of the hand.

One of the most frequent lesions of the skin is bleb formation, the so-called pemphigus leprosus. The blebs

vary in size from a pinhead or pea to a grape or larger, are filled with clear liquid, break, and leave livid excoriated spots, which by neglect or improper treatment may give rise to ulcers. The appearance of the bleb eruption is usually accompanied by general symptoms. Some investigators have stated that they were able to find lepra bacilli in the blebs, so that the dystrophic nature of the blebs is still doubtful. Histologically, one finds an elevation of the epidermis by a clear exudate.

The deeper parts also show trophic disturbances; especially are the bones of the finger phalanges so disposed. These become necrotic, the phalanx swells, softens, and breaks down into a fistule, through which the bone is cast off. The result of this recurrent process is a distortion of the hand, to which the name of *lepra mutilans* is given. The trophic disturbances on the extremities frequently appear asymmetrically.

In consequence of the predominance of the involvement of the nervous system in lepra anæsthetica the attempt has frequently been made to trace an etiologic relationship of leprosy to certain nervous diseases. Zambaco Pascha connects nervous leprosy with syringomyelia, looking upon the cases of syringomyelia of the type Morvan as weakened forms of leprosy. Zambaco accepts that leprosy of today, in consequence of continued hereditary attenuation, is not found in its original virulent form, but weakened in "formes frustes"; for example, in the form of syringomyelia, or that inherited leprosy at least predisposes to the acquisition of syringomyelia. In fact, in many cases lepra bacilli were found in the spinal cord, in the brain, in the spinal ganglia, and the sympathetic ganglia. Of significance on this question appear to be the cases reported by Gerber and Matzenauer of syringomyelia, in which the examination of an excised portion of the skin disclosed typical lepra bacilli. At the autopsy perivascular gliose, especially in the posterior cords, was found.

The histologic examination of leprous tissue shows a rich cell inflammatory infiltration with characteristic large

cell-like formations, which were named by Virchow "lepra cells" and by Neisser as "globi." It is true that their cell nature is much questioned and the possibility that they may represent changed lymph vessels is not excluded. The cell infiltration permeates the cutis, surrounds the hair follicles and the sweat glands, and invests the blood-vessels and nerves. According to Unna, the elastic fibers in the neighborhood of the infiltration have entirely disappeared. Especially on the nerves are growths of leprous tissue to be found, by which the nerve fibers are pressed apart and finally atrophy. In older lepromata a distinct increase of the pigment is noted. Klingmüller emphasizes that in the tuberous form, besides the greater masses of bacilli, cells are especially abundant.

Etiology.—Long before Armauer Hansen succeeded in finding the lepra bacillus, which was later studied more closely by Neisser, the contagious character of the disease was alleged; this conviction being emphasized by the strong isolation and disinfection rules for leprous patients, by their confinement in lazarettos, and by the establishment of lepra cemeteries. Only Danielsen, Boeck, and Hutchinson held to the belief that the disease was dependent upon faulty nutrition, bad social circumstances, and especially to the eating of spoiled fish. Since the International Leprosy Conference in 1897 the bacillar nature of the malady is generally accepted. Moreover, Arning succeeded in communicating it to a man by inoculation.

The lepra bacillus is 4 to 6 mm. long and about 0.4 mm. wide, pointed at the end or with a knob-like thickening. Some of the bacilli are mostly granular, perhaps on account of a change due to age (Babes). Frequently the bacillus has an investing mucous coating, which is probably formed of its secretion product. A pure culture of the bacillus, up to the present, has not been successful beyond question; likewise experiments as to its communication to animals have not succeeded. The bacilli in the leprous tissue are in greater proportion extracellular (Pernet), find their way into the organism by way of the lymph channels.

In some typical leprosy cases the bacteriologic investigations may be negative, as shown and quoted by Kaposi as increasing the difficulty in the diagnosis of some cases. It is worthy of special note that at the time of acute exacerbations the lepra bacillus can be demonstrated in the blood, where it at other times is constantly absent.

Regarding the site of the primary leprous infection one is only able in the rarest instances to state this with positive certainty, especially as the history of the cases is indefinite on this point. Sticker believes that the primary lesion in all cases is to be found in the nasal mucous membrane, mostly in the form of an ulcer of the cartilaginous part of the septum. This ulcer is the place from which bacilli in large numbers are given off by the patient. The frequency of leprous rhinitis is beyond question, the proof, however, that in all cases the nasal mucous membrane is the site of the initial effect is not proven.

According to the experiments of Arning as to the great endurance of the lepra bacillus it would appear that the danger of infection is not a small one. Recently Gravagna found on a piece of money, which a leper was carrying in his pocket, lepra bacilli.

The transmission of leprosy seems also possible. Zambaco Pascha reports miscarriages and abortions in leprous mothers, as well as cases of leprosy in children within the first few weeks of life. Babes was able to demonstrate the presence of bacilli both in the spermatic fluid and in the ovary cells. He found in about 50 per cent. of leprous men azoöspermia, a fact which agrees with the already-mentioned observation by Glück regarding the frequency of leprous involvement of the testicles.

The **course** of the disease is eminently chronic, the duration extending between five and eighteen years, the anesthetic type being the more prolonged in its course. Some cases can remain stationary for years. Dom Santon has placed these in a special group and called them **lepra lazarina.** A cure is unknown; all cases end fatally. [Several alleged cures, or at least apparent cures, have

been reported from time to time.—Ed.] There develops a progressive cachexia, due to the persistent ulceration of the skin and to the severe trophic disturbances, and also to visceral leprous complications (liver, spleen, kidneys).

Especially the kidneys show constantly severe parenchymatous changes, without necessarily being the seat of the leprous deposits. Visceral leprosy induces severe derangements of the stomach and intestinal functions, so that the patient may succumb to the increasing cachexia so caused or to some fatal intercurrent affection. Especially is tuberculosis one of the most frequent complications which carry off the patient or hasten the fatal end. Schäffer has shown the occurrence of a mixed infection of leprosy and tuberculosis in the lungs histologically. The occurrence of such a mixed infection in other visceral organs is very probable.

Treatment.—The greatest weight is to be placed upon prophylactic measures. In cases in which the disease is already established dietetic and hygienic measures play a very important part in its management, without being sufficient to stay materially the progress of the disease. The remedies proposed for the treatment of leprosy, even including the Carrasquilla serum, have a problematical worth. Unna claims that by the administration of ichthyol and the local application of ichthyol and pyrogallol to have cured two cases. Also the internal use of sodium salicylate and iodid preparations has been praised by many. The two preparations which have earned the greatest confidence are gurjun balsam and chaulmoogra oil.

The gurjun balsam is administered in doses of five minims to a teaspoonful, in slowly increasing quantity; it is also applied externally with an equal part of lanolin, and rubbed in. Chaulmoogra oil is given in dosage as high as 150 drops daily. Bergmann cautions against the use of mercury commended by several observers.

MADURA FOOT (MYCETOMA PEDIS).

Madura foot has been observed predominantly in tropical countries, most frequently in India, but also in Africa; less frequently in America and Europe. The malady attacks chiefly the feet, which are changed into deformed masses. The epidermis of the attacked extremity is beset with nodules, becomes undermined with ulcerative processes and perforated with numerous fistules, from which issue a yellowish or blackish granular substance, consisting of massed-together fungus. According to the color of the "grains" two varieties are described, a yellow and a black, of which the yellow is the more frequent. The fistules in their further course of the malady may extend down deeply and produce softening and caseation of the bones of the foot. The malady pursues its course without subjective symptoms up to the point of resulting difficulty in walking, the foot becoming egg-shaped, the toes lifted upward, and directed away from each other. Spontaneous retrogression never takes place, only a regional healing with closure of some of the fistules having been observed. Mostly only one foot is involved in the destructive process, seldom the upper extremities, the abdomen (Maitland), or the neck (Smith).

The histologic examinations show in the diseased part granulation tissue, which partly breaks down, becoming purulent, and partly leads to the formation of fibrous connective tissue. In advanced cases the muscles and bones also are changed into a soft spongy connective tissue. The tendons are the last to be attacked. In the black variety the connective-tissue hypertrophy is predominant (Oppenheim). The examination of the yellow grains shows thick matted mycelia, resembling that of actinomycosis, the latter, however, having different staining qualities (Unna). Oppenheim found also in the black variety segmented mycelia of different sizes and shapes, which when stained with methylene-blue resembled closely the sclerotium of the mother grain, and named the fungus

ascomyces Maduræ. The yellow variety was cultivated by Vincent on potatoes, distinguished from the actinomyces, and named *streptothrix Maduræ.* A positive animal experiment for either kind is not yet available.

ALEPPO BOIL.

The Aleppo boil is an infectious malady, chiefly observed in Persia and India, beginning between the second and seventh year, and which is characterized by the formation of furuncle-like nodes in the face, on the hands, and feet. These nodules are either present singly (male bouton, button, or boil), in which case a crateriform ulcer forms, healing with granulation-tissue formation; or in numbers (female bouton), in which a central extension of the process is observed. In most of the cases the multiple nodules also heal with scar-formation. The duration of the malady does not generally extend beyond ten months.

Riehl found in the histologic examination an inflammatory granulation tissue with predominant round-cell infiltration, and the presence of epithelioid and giant cells.

The cause of the malady is up to the present unknown.

MALIGNANT GROWTHS OF THE SKIN.

The general integument is often the seat of malignant new growths, arising spontaneously or through metastasis, the cutaneous manifestation being the first evidence of the disease. Most of these growths belong essentially to the domain of surgery, and are fully treated in works upon that subject. It is, however, often the province of the dermatologist to see these formations in their earlier stages.

The most frequent malignant tumors are the sarcomata and their allied growths, and certain forms of carcinomata.

Under **sarcoid growths** or tumors Kaposi and others, following his ideas, have placed a group of new growths

together, which are characterized by tumor-formations similar to the sarcomata, in which, however, the infiltrated skin, in contradistinction to the sarcomata, is partly capable of regeneration or involution. In this group belong granuloma fungoïdes (mycosis fungoïdes), leukemia and pseudoleukemia of the skin, sarcoma idiopathicum hæmorrhagicum (Kaposi), and the sarcomatosis cutis (Spiegler).

GRANULOMA FUNGOÏDES.

Granuloma fungoïdes, or *mycosis fungoïdes* of Alibert, is a rare chronic skin disease, distinguished by a progressive course and by the formation of infiltrated and tumor-like growths which develop rapidly, but which may also undergo complete involution. Most cases of this disease can exhibit four stages: (1) The stage of premycotic dermatitis; (2) that of infiltration; (3) the stage of tumor-formation or new growths; and (4) finally that of cachexia. Other divisions have been repeatedly made, as that most recently, for example, by Sonnenberg, of three stages: (1) That of the evanescent erythema; (2) the lichenoid or papular stage; and (3) the tumor-formation period.

The disease begins with prodromal erythematous and eczematoid, intensely itchy plaques on the trunks, on the flexors of the extremities, and on the face, especially on the forehead. The epiderm in these places exfoliates or is covered with thick crusts. [This stage may last from several months to several years.—Ed.]

Owing to the intense itching, the patient is troubled with loss of sleep. Gradually individual lesions or patches completely disappear, others heal in the central part and spread at the periphery, and there gradually develops what Kœbner has designated the stage of infiltration—second stage. In addition to the infiltrated patches or areas, lentil- to bean-sized red protuberances appear, which gradually develop into half-rounded tumors of the size of a small apple or mandarin orange, and the third stage is entered. The color is pale brown to dark red,

the surface notched or serrated, the center slightly depressed. At first hard, it gradually becomes softer. These tumors also may melt away in the course of several days or a few weeks, leaving nothing but pigmentation. More frequently, however, they become necrotic and give place to ulcers which bleed readily. The patient's general condition, apparently little disturbed in the earlier stages, now begins to fail perceptibly; they become marasmic, and the large majority gradually succumb to the disease.

The lymphatic glands are not involved in the process. The length of time in which the four stages may last can be from five to ten years. [Some of those observed by Americans and others have gone far beyond this.—Ed.]

In a smaller number of cases the affection enters immediately upon the tumor stage, beginning, in fact, with this stage (*granuloma fungoïdes d'emblée* of the French), and leads mostly, with rapid suppuration, in a short time to death. Two such cases have been recently described by Riecke. Paltauf observed a form showing a combination of granuloma fungoïdes with leukemia or pseudoleukemia, in which the skin changes peculiar to granuloma fungoides were found in association with increase of leukocytes in the blood, with lymphatic gland tumors, and swelling of the liver and spleen.

Histologic investigations of the tumors of granuloma fungoïdes teach that the process consists of cell growth about the vessels, at the bases of the papillæ in the connective tissue, and about the glands and hair follicles. The cell growth appears mostly as an infiltration crowding out the cutis and the papillary body. The irregular collections of round cells are massed in a framework of fibrillar connective tissue; and Paltauf intimates that this stroma for the most part consists of bundles of cutis fibers pressed asunder. The epidermis in the beginning seems thickened; later, however, it is thin and free from proliferation processes.

Unna calls special attention to the fact that parasites can easily localize themselves in the loose, soft tissue, and

may easily lead to necrotic changes and general septic infection.

The various findings of bacteria and cocci in the growths are to be looked upon as belonging to septic processes and accidental, and not necessarily having any pathogenic relationship to the disease.

The histologic investigations show also that granuloma fungoïdes belongs neither to the sarcomatous nor to the granulation tumors. Paltauf holds it for a disease of the whole organism, produced by a variety of vegetative disturbances, as leukemia, rachitis, æromegaly. There is an abnormal proliferation of cells, whereby a sarcoma-like tissue is formed, but which is capable of retrogressive and involution changes. For the individuality of the disease as a clinical type even Kaposi has fallen in line.

Treatment.—While heretofore this disease was rebellious to our therapy (not mentioning the isolated cures under arsenic treatment), recently repeated communications have appeared reporting the involution of the tumors under treatment by Röntgen rays. This method is, therefore, to be tried first, although it is true also with this method that relapses occur, which must likewise be subjected to the same treatment.

A favorable influence in the premycotic stage, from the Röntgen-ray treatment, has likewise been repeatedly observed.

LEUKEMIA AND PSEUDOLEUKEMIA.

According to the opinion of most authors (Pinkus), between leukemic and pseudoleukemic cutaneous manifestations there exist only gradual differences. The most characteristic feature of these diseases is less in their clinical symptoms than in the sequence of the same, and in the histologic findings. As Paltauf emphasized, in the diagnosis weight is to be placed upon the primary appearance in the blood of lymphocythemia, which is wanting in granuloma fungoïdes, and which only presents in lymphodermia perniciosa when mycotic changes in the skin had

already been presented. The skin changes are thus, in the diseases under consideration, to be viewed as secondary.

The disease appears in the majority of cases as leukemic tumor formations, which are localized in the face, over the eyebrows, on the nose, and chin. Such growths in many cases reach conspicuous size, and form orange-sized bags, which can conceal the eyes. Less frequently appear diffuse infiltrations in the subcutaneous fat tissue, over which the skin becomes eczematoid; the epidermis is deeply furrowed, scaly or oozing (Riehl).

The malady always has an unfavorable course. Along with an increase of the general pallor, some of the tumors ulcerate. Lymphatic-gland swelling develops, as well as splenic enlargement, and after months of suffering the fatal end ensues. At the autopsy leukemic nodes are found in the pleura, lungs, and in the other internal organs, as likewise in the skin and glands. Especially is the spleen often irregularly enlarged.

Examination of the blood shows leukocytosis, diminution of the number of red blood-corpuscles and of the hemoglobin. Yet, as stated, this lymphocythemia is also demonstrable in other sarcoid tumors, and is therefore only of diagnostic value when opportunity is given to ascertain this before the outbreak of the cutaneous symptoms, which is only seldom possible.

Histologically, the tumors present an infiltration of the cutis and subcutis, which gradually, up to a narrow thin layer of the upper cutis, takes the place of the original tissues. The cells of the infiltration are mononuclear leukocytes. In the neighborhood of the vessels there is increase of leukocytes, also in such places in the skin where no clinical changes are shown. Especially this latter speaks for the primary occurrence of the leukocytosis. In the case of purpura pictured in Plates 13 and 14, which under rapidly developing collapse ended fatally, the autopsy showed swelling of the lymph glands, leukemic spleen, and liver swellings; blood taken from the cadaver showed marked leukocytosis.

Similar, if less characteristic, appear the deposits in the skin in *pseudoleukemia*. In this disease also eczematoid or urticarial manifestations usually go hand in hand or precede the node formation in the subcutis. In the course of pseudoleukemia, tumors in the face and prurigo-like papules have been described. The subjective symptoms, as well as the further course, are similar to those of leukemia, which together with the blood-investigation permit a recognition of the disease.

The *lymphodermia perniciosa* of Kaposi is to be grouped along with granuloma fungoïdes and the leukemic changes in the skin. In this rare form is associated with the symptoms of granuloma fungoïdes marked increase of the leukocytes in the blood. At first there develops scaly or oozing eczema on some places of the face, trunk, and extremities, upon which doughy infiltrations and nodule formation with later ulceration follow. The extension of the tumors in the face, over the brow, ears, and lips gives the patient the appearance of facies leonina. In its further course lymphatic-gland swellings and a severe lymphocythemia ensue, followed by fatal termination. Paltauf ranks the affection as a variety of granuloma fungoïdes, inasmuch as he failed to find anything in the blood characteristic of leukemia.

The treatment is based substantially upon the underlying malady (heroic arsenic treatment is often of favorable influence). When the tumors have become excessively large, surgical removal can be resorted to. External treatment is purely symptomatic.

SARCOMA IDIOPATHICUM HÆMORRHAGICUM (KAPOSI).

This disease is at first localized on the hands and feet, and from here gradually extends onto the limbs. Shot- to bean-sized, reddish-brown, later bluish, firm, elastic, rounded, projecting nodules appear; these can in some places occur in groups, from dime to palm in size. On

the flexor and extensor surfaces of the extremities are found shapeless, cushion-like elevations, which feel hard and are painful. The individual nodes undergo involution, leaving a dark pigmented scar; the grouped nodules leave a similarly pigmented scar-group, which is surrounded by a hard, brownish-red wall. Only occasionally do some nodules undergo softening and necrosis. The course lasts three to eight years, during which time there is a continuance of the outbreaks of new growths from the peripheral toward the central parts. In later stages bean- to nut-sized nodes may appear on the eyelids, on the nose and nasal mucous membrane, on the cheeks and lips, which are of a dark-blue color and spongy to the touch, and undergo superficial softening and necrosis, disclosing a bloody tissue. Bernhardt very recently observed such nodes also on the glans penis and scrotum. Occasionally lymphatic-gland swelling may be present, but this symptom is not a part of the disease, but occurs sympathetically, as, for example, with necrosis or gangrene of the foot. Almost invariably the malady runs an unfavorable course.

Histologically, the growths indicate a fusocellular angiosarcoma. The pigmentation is the result of frequent capillary hemorrhages, and does not depend upon any peculiar melanosis (Kaposi). Schwimmer believes that the tumors take their origin in the vessel walls, in support of which can be cited the high fragility of the vessel walls and the (in consequence) resulting hemorrhages. Kreibich and Sellei reached the same conclusion.

Treatment.—In this disease also retrogression of the growths has been observed to follow the Röntgen-ray treatment. An energetic arsenic treatment is the most hopeful in bringing improvement, but it is mostly only temporary.

ENDOTHELIOMA CUTIS.

These rare, very disfiguring tumors, which were particularly described by Spiegler, Ancel, Riehl, and others, are

most commonly seen on the scalp, less frequently on the other parts of the upper half of the body (face, neck, breast). They consist of multiple nodular tumors, which in regard to size and color show resemblance to potatoes. The skin is, in their further course, distended and shining, and finally shows exfoliation and crust formation. Between closely contiguous tumors also the skin shows crusts and scales or a purulent secretion.

In histologic examinations one finds cell columns with central polygonal and peripheral cylinder cells. From the capillaries enclosed in the cell columns originates, according to Spiegler, the endothelial new growth. Riehl is of the opinion that the tumors take their origin in the endothelium of the lymph vessels.

In some cases a hereditary appearance of the malady seems possible.

TRICHOEPITHELIOMA PAPULATUM MULTIPLEX (JARISCH).

This affection, described by Jarisch, is characterized by the appearance, mostly at the time of puberty, of pinhead- to pea-sized, firm, shining papules covered with normal skin, which, as a rule, remain stationary, but also can become transformed into flat skin carcinoma of the type of ulcus rodens; they appear on the face, and especially the forehead, eyebrows, and nose, less frequently on the breast and back.

The histologic examinations indicate that the growths consist of cystic, dilated epithelial columns, which contain no hair stumps, and which have taken their origin from the epithelium of the hair follicle.

SARCOMATIS CUTIS (SPIEGLER).

This malady has also been included among the sarcoid growths, for the reason that it, too, is characterized by the appearance of circumscribed growths simultaneously on several regions, and which may undergo involution and the skin assume its normal condition.

Pea- to nut-sized semiglobular or plate-like, firm tumors develop in the cutis propria, over which, in their further growth, the skin becomes thin and shows venous telangiectases. The growths are not sharply defined, and many times appear to be plate-like infiltrations with depressed center. The tumors are mostly multiple on one region and remain a long time stationary, without giving rise to subjective symptoms. Some of the tumors can undergo involution during the course of a febrile affection or under arsenic administration (Kaposi). Frequently, however, the tumor formations involve other regions, and with metastases in the internal organs a fatal ending ensues.

According to Spiegler the tumors consist histologically of round cells which thickly permeate the tissues.

SARCOMA.

Primary sarcoma is a rarer malady, and appears usually as a spindle-celled sarcoma. From secondary extension on to the skin or metastatic growths in the same the sarcoma can be of a quite different histologic character in the skin. Cutaneous sarcomata can, in contradistinction to the sarcomata of other tissues, grow much more slowly, and often remain for a long time limited to a circumscribed area of the skin; suddenly, corresponding to their malignant character, they may extend rapidly into the deeper tissue and ulcerate superficially. Contrary to the sarcoid growths, a spontaneous involution of individual nodes does not occur, and the new nodules formed in the neighborhood of the original tumors are often joined to them with a sarcomatous flat infiltration.

The skin becomes attached to the underlying part, the surface is stretched, shiny, and thinned.

Histologically, the spindle-celled sarcomata can only be distinguished with difficulty from the cell-rich fibromata. The **melanosarcomata** are alveolar-formed angiosarcoma with pigment deposit in and between the cells.

Ribbert holds the opinion that melanosarcoma arises from atypic growth of the chromatophores. These can, as known, also increase in the other tumors, as fibroma and carcinoma.

The melanosarcoma, originating in a soft nevus, is characterized by its particularly malignant course. Simple angiosarcomata of the skin, in which the tumor formation had originated in the perithelium, and composed of epithelioid, radiatingly arranged cells, were described recently by Wooley and White.

EPITHELIOMA (RODENT ULCER; CANCER; SKIN CANCER.)

The general integument may be primarily the seat of epitheliomatous growths, or it may be involved secondarily from tumors beneath the skin; or skin epithelioma may finally occur as a metastasis from one or more of the internal organs.

The most frequent primitive form on the skin is the epidermic cancer. In the beginning it appears as a flat hard papule or tubercle, or as a diffused, uneven, irregular growth, or as a subcutaneous nodule involving the skin. In many cases ulceration is wanting, and often there are thick hemorrhagic crusts. With the extension of the tubercle formation peripherally and with the ulceration of the central part are associated scarred-over spots in the central portion; we often find, therefore, this central, scarred-over or healed part an ulcerating zone, and outside of this the groups of tubercles and a fresh, extending, infiltrating carcinomatous wall.

The flat cutaneous carcinoma appears in two clinically and histologically different forms, as epithelioma and as ulcus rodens, the latter being by far the more frequent.

The chief characteristic of this form of epithelial cancer is the so-called pearl rolls or bodies, the cancroidal bodies, which appear as a conglomeration of variously shaped epithelioid cells in the form of waxy, glistening or pale-

red hard tubercles, which, if seated on the surface, may be readily pressed out. It is essentially a cornification process of the epithelium. The cancer cells contain in this form large vesicle-like nuclei, taking color badly, and of abundant protoplasm. The lower lip is a favorite region, less frequently the trunk and extremities; it can likewise develop on the base of a lupus scar. It is seen almost wholly in very old individuals, and may take, with early metastases, a very malignant course.

Sometimes there results complete exfoliation with cicatricial formation in the center, a new progressive, hard, waxy-looking edge with contained cancroidal bodies forming on the borders. Should the scar and the border contain pigment, it represents the so-called chimney-sweepers' cancer.

Contrary to this, the more frequent form of flat cutaneous epithelioma, the ulcus rodens, runs an extremely slow course. In the carcinomatous tissue cornification is not seen, but necrosis and softening are present. The cells of the morbid tissue contain nuclei readily stained, and less unfurrowed protoplasm. The cancer cells have a spindle form. When the scar and border of the epithelial carcinoma contain pigment, it has also usually gone under the name of "chimney-sweepers' cancer."

For ten to twenty years such a process upon the skin may go on, apparently at times stationary; sooner or later induration, ulceration, contractions, and consequent changes in the skin take place, but without the general organism being disturbed. Only in rare instances is observed a nodular carcinoma, which is characterized by its rapid extension into the deeper tissues, tendons, muscles, and bone. The growths are firmer and harder; show in general, however, the histologic characteristics of ulcus rodens.

The papillary cutaneous carcinoma usually runs a malignant course. It leads to the formation of superficial horny or necrotic softened warty vegetations. A carcinoma can take its origin in a wart which had existed for

years, the change suddenly developing. The histologic conditions of papillary cutaneous carcinoma are not uniform; it can appear as in epidermal carcinoma, or as ulcus rodens, or as cylindroma.

Another form of cancer observed in the skin is *carcinoma lenticulare*, which frequently starts from mammary cancer, with redness and hardening; spreads and gives rise to an infiltration of the skin, so that the thorax is covered with newly formed masses, as if enveloped in a coat of mail (*cancer en cuirasse*) (Plate 98).

The most frequent sites of epithelioma are the eyelids, nose, lips, and less frequently the forehead and cheeks. Of importance are the epitheliomata of the eyelids, which gradually destroy the latter, invade the conjunctiva, and finally the bulbus (Plate 97).

In the quite frequent carcinoma of the under lip the use of the smoking-pipe has been looked upon as of etiologic moment. It is so rare on the upper lip that in earlier periods this localization had been denied. The diagnostic difficulties between carcinoma of the tongue and ulcerating gumma of this organ are sometimes very great.

From the nose and lips the epitheliomatous growth may extend to the mucous membrane of these parts. The disease may also occur primarily as an independent affection on the mucous membranes of the mouth, nose, and rectum. The frequent thickenings observed on the mucous membrane of the cheeks, and especially the tongue, are after years' duration often the starting-point of epithelioma. On the penis, especially about the urethra, epithelioma develops and invades the corpus cavernosum, forming small or large ulcers (Plates 100 and 101). The lymphatic vessels of the penis and the inguinal glands become involved; at first hard painless tumors form, which may break down and become purulent. Epithelioma of the external genitalia and vagina of women behaves the same way, and may frequently be mistaken for syphilis (Plate 99). Primary carcinoma of Bartholini's glands has also been observed.

As to its localization in the two sexes, observations show that epithelial carcinoma in man is predominently upon the tongue, lip, and rectum; in women, the genitalia and mammary glands.

Epithelioma occurs generally in advanced years. It may appear at the site of slow, granulating ulcers or scars after syphilis and lupus; or have its seat, as already mentioned, in warts and mucous-membrane thickenings. Traumatic injuries often seem to be the impetus which starts the carcinomatous process. Interesting is the fact, to which attention has recently been called, that carcinoma is extremely uncommon in houses of correction and prisons. This observation concerning persons who were shut off from the outer world has been cited as in favor of the parasitic origin of the malady. It may exist, as already indicated, ten to twenty years without endangering life, till finally, more especially in the papillomatous form, more rapid breaking down and glandular involvement ensue and the patient dies from marasmus. We do not consider this the place to go into the numerous theories regarding the pathogenesis of carcinoma.

Paget's Disease.—This disease, first described by Paget (1874), is seen chiefly in women between the ages of forty and sixty, and begins on the breast with a picture of an eczema of the mammilla and the areola. The skin is erythematous, eroded, and oozing, superficially smooth or covered with yellowish-brown crusts. The affection is sharply bounded against the surrounding healthy skin, and shows in its further course a parchment-like induration. This eczematoid condition of the skin can last years with very slight subjective symptoms; occasionally burning and itching continue. Gradually the affection extends, the regional lymph glands of the axilla become infiltrated, the growth invades the breast glands, in consequence of which the nipple becomes retracted. The process never remains permanently in the eczematoid stage, but in every instance finally develops into a malignant end-stadium. In rare instances the disease is also

seen on the male breast, on the penis, on the face, or in the axilla.

The pathogenesis of this disease, with its striking clinical symptoms and typical course, has, ever since it was first observed, been the subject of much discussion. Darier believed the affection belonged among the psorospermoses, inasmuch as he found similar rounded formations in this disease. Soon afterward, however, these questionable coccidia-like formations were shown, especially by Unna and Török, to be degenerated cells and cell inclusions. In the advanced stage of the disease the carcinomatous character of the malady is universally acknowledged; it is still somewhat discussed, however, as to whether it begins primarily with an eczema which merely forms a favorable basis or soil for malignant development, or whether it is from the very beginning carcinomatous (Gussenbauer). According to the histologic investigations by Karg, Benjamins, Ehrhardt, and Matzenauer, the primary carcinomatous nature of the disease appears probable. In many cases, even in the eczematoid stage, there is observed a subepithelial-cell infiltration, which exhibits an "exquisite plasmon" (Unna), and which is never seen in eczema. Further, one finds, even in the early stage, in the epithelial layer some pegs and threads which grow into the depth and finally form into "nests." The recent finding of yeast-fungus elements (blastomycosis) by Fabry and Trautmann needs confirmation.

Treatment.—Surgical methods are of first importance. Only when surgical treatment cannot be carried out is recourse to be had to other plans. As such, we name the destruction of the growth with caustics (lactic acid, acetic acid, nitric acid, Vienna paste, zinc chlorid, arsenic pastes), thermocautery, and erasion of the mass with the curet. The pyoktanin treatment, as likewise the Adamkiewicz's cancroin treatment, has been abandoned. In ulcus rodens, resorcin, pyrogallic acid, in powder or salve form (15 to 30 per cent.), have been recommended. Las-

sar recommends subcutaneous arsenic injections. According to the latest experiences, the Röntgen-ray treatment and treatment by radium should be tried.

PARASITIC DISEASES OF THE SKIN.

The parasites of the skin are of both vegetable and animal nature. The diseases induced by their presence have naturally a contagious character; such diseases are, however, distinct from infectious diseases, which are also called forth by parasites (microörganisms), but which, in addition to attacking the skin, involve other organs.

THE VEGETABLE PARASITES OF THE SKIN.

The vegetable parasites of the skin belong collectively in the group of pathogenic mould fungi (hyphomycetes). The diseases produced by these parasites are termed dermatohyphomycoses or dermatomycoses.

Each of the several diseases is produced by a special fungus; nevertheless one and the same fungus, as Bodin has shown, can provoke somewhat variable or different clinical symptoms.

TINEA FAVOSA (FAVUS).

Favus (Plate 102) is due to invasion of the skin by a vegetable parasite, the achorion Schönleinii. This fungus consists of numerous wide and branching mycelial threads and spores, is found usually on the hairy scalp, and forms disk-like yellowish crusts, which show in the center a depression. When favus involves the entire hairy scalp, not infrequently some disks are to be seen on the eyelids, on the extremities, or on the penis; it sometimes, indeed, in rare instances, is seen over the entire body. The fungus is seated in the follicles and even in the hair-root sheath, and gradually causes the hair to fall out. The diseased hairs can either be pulled out easily or they break off. The hair papillæ may be destroyed, on the one hand,

by the mechanical pressure of the favus masses, or, on the other hand, by the penetration of the fungus between the hair follicle and hair, which provokes a chronic inflammation of the papillæ with a secondary atrophy. In addition to these processes dependent upon the fungus, other pathogenic microörganisms may find entrance and cause purulent processes which may lead to crust formation. The color of the disks or crusts is sulphur or straw yellow. After the crust is removed or falls off there is left a smooth atrophic depression. The follicles are destroyed and the affected areas are more or less bald. Through confluence large masses of crusts are formed. From the primarily affected spot the favus spreads peripherally with the formation of new scutula or disks. The fungus gives rise to a characteristic mousy odor. This, together with the atrophy or scar formation and the direct microscopic demonstration of the achorion (Plate 115, *e*), are the most important helps toward the diagnosis. It suffices to rub up a fragment of a detached scutulum with water upon an object glass, the characteristic mycelial threads and dark spores in crowded groups being readily recognizable.

This chronic disease, which usually appears early in life and persists through adolescence and manhood, may disappear spontaneously, all the follicles having been destroyed. In such cases the scalp is completely bald, with the exception of scattered single hairs or tufts of hair; the skin is thinned, smooth, and atrophic.

The disease is also met with on other parts of the body, although comparatively seldom. The fungus has, in fact, been found, in a case of universal favus, even on the mucous membranes, the patient having died of gastro-enteritis (Kundrat). The nails of the hands may also be the seat of this vegetable parasite, with the consequent changes; they become opaque, crumble, or break easily, and are found permeated with the fungus (onychomycosis favosa). Sometimes the yellowish scutulum can be seen through the overlying nail.

Treatment.—Treatment of the disease on the scalp begins with cropping short the hair of the whole region. After this the accumulated fungous masses are removed. This is most readily accomplished by softening with oil or fats, with or without the addition of carbolic acid or naphthol; and subsequently by thoroughly shampooing. When this has been effected the diseased areas should be depilated, and this should not be limited to the spots, but should extend one or two centimeters beyond the borders. By gentle traction only the diseased hairs are brought away. Lotions of antiseptic solutions and bandages spread with antiparasitic salves may be applied, having in view the destruction of the fungus.

The number of such applications for this disease is very large. We name the tar preparations, salicylic sulphur salves, alcoholic solutions of corrosive sublimate, resorcin, naphthol, creolin, pyrogallic acid, and chrysarobin:

℞ Chrysarobin,
Ichthyol, āā 5 (gr. lxxv);
Acidi salicylici, 3 (gr. xlv);
Vaselini, 100 (℥iij).—M.
Ft. unguentum (Unna).

Besnier advises the following salve, to be applied at night:

℞ Bals. peruviani,
Acidi salicylici,
Resorcini, āā 50 (℥iss);
Sulphur. præcip., 15 (℥ss);
Lanolini,
Vaselini,
Adipis lanæ, āā 30 (℥j).—M.
Ft. unguentum.

In the morning the scalp is thoroughly washed with luke-

warm water and soap (tar naphthol soap), dried, and then the following solution painted on:

℞ Spirit. vini gallici, 100 (℥iij);
Acidi acetici, 0.25–1 (♏iv–♏xv);
Acidi borici, 2 (gr. xxx);
Chloroformi, 2 (♏xxx).—M.
Sig.—External use.

Pick considers the best method of treatment to consist of daily washing with boric-acid soap, and subsequently applying a 5 to 10 per cent. alcoholic solution of boric acid; in severe cases powdering with boric-acid powder, over which is placed moist lint, and then enveloping the parts with gauze.

Pirogoff orders the affected parts shaved, and every twenty-four hours the following salve to be applied, spread as a plaster:

℞ Potass. carbonat., 8 (ʒij);
Sulphur. sublimat., 30 (℥j);
Tinct. iodini,
Picis liq., āā 100 (℥iij);
Adipis benzoinat., 200 (℥vj).—M.
Ft. unguentum.

Before each application of the salve the scalp is to be washed with soap and water.

Zinsser orders the scalp washed with soap and water, and shaved; the scalp is then covered with compresses wet with a solution of 3 per cent. carbolic acid or of 0.25 per cent. corrosive sublimate, over which is placed a Leiter coil, through which water of the temperature of 52° to 58° C. is kept circulating. During the night the coil is not employed.

In carrying out any of the plans mentioned above for the treatment of this obstinate disease, persistence must be enjoined for many months. Culture tests of the depilated

hairs must be made the basis of further treatment or its discontinuance.

The treatment of favus on non-hairy surfaces is much easier and more satisfactory. The crusts are removed, and one of the antimycotic applications already mentioned applied to the affected area.

The treatment of favus of the nails consists in bathing the parts in antiseptic solutions, and then applying compresses wet with the solution. Before making the application the nail should be thoroughly scraped with the sharp spoon or gently cut away.

A satisfactory depilation can be effected by means of the Röntgen rays. The hairs fall out, the spots upon which the scutula have been seated exfoliate and give place to superficial erosion or loss of tissue which, inside of eight to ten days, have skimmed over. Very soon the normal hairs begin to grow again. Jadassohn, after complete depilation, applies a 5 to 10 per cent. pyrogallol salve. L. Freund, after the reaction has subsided, rubs the bald places with the following salve:

℞ Acid. carbolici glycerino soluti., 2.50 (gr. xl);
Lanolini, 50 (℥iss).—M.

TINEA TRICHOPHYTINA (TRICHOPHYTOSIS; RINGWORM; HERPES TONSURANS (OF THE GERMANS)).

Trichophytosis.—Under this name we include a group of very different clinical pictures together, which are produced by the trichophyton discovered by Gruby. This fungus can be demonstrated in the contents of the vesicles, crusts, and scales after clearing with a 20 per cent. potash solution. It shows an extremely polymorphous character, inasmuch as on different parts of the body it may exhibit long-branched mycelial threads, as also round spores; sometimes the mycelial threads, sometimes the spores predominating in the microscopic field. In cultures on agar there are formed white fragile

masses. Inoculation with pure culture is possible. If one scarifies a point of the skin and rubs in fungous cultures, in a short time vesicle or papule formation shows itself. The trichophyton produces upon the skin either scaling or vesiculation, disease of the nails and hairs; it can further, from mixed infection, lead to phlegmonous inflammations. The fungus grows in the upper layers of the epidermis and provokes marked changes and more diverse clinical pictures than the achorion Schönleinii, from which it is distinguished by its form and arrangement of the mycelia and the behavior of the spores. [It is now established that there are two distinct forms of fungus responsible for ringworm—the small-spored fungus (microsporon Audonini) and the large-spored fungus (trichophyton). Of the latter there are several varieties.—Ed.]

Tinea Circinata (Tinea Trichophytina Corporis).

In average cases of tinea circinata—ringworm of non-hairy parts—one or several pinhead- to pea-sized slightly hyperemic spots appear, which soon show slight branny scaliness; the central part begins to clear up, while the patch enlarges by spreading peripherally. After several days or a week they usually attain the size of a silver quarter. The border is noted to be slightly red and scaly, and may even tend to papular and vesicular formation, or in exceptional cases small pustules may develop. The central part clears up, the skin being there pale red or pale brownish, free from scaliness or with trifling exfoliation. The outer part of the circle is usually somewhat more scaly, but this is rarely pronounced. The disease may remain stationary, or the patches may extend somewhat; or new spots may show themselves. As commonly met with, there are rarely more than three to ten areas. The older patches gradually disappear with slight scaliness. This frequently takes place after one or two weeks; usually as the result of the application of some

home remedy of an antiseptic character, or it may spontaneously disappear. In some cases the areas are persistent and demand more energetic applications, which will be referred to later.

[Under the name "herpes tonsurans disseminatus" the author describes a manifestation which is considered in this country to be independent of the ringworm fungus, and to represent the disease known as *pityriasis maculata et circinata.* At all events, it represents in its clinical manifestations the disease here referred to, and the atlas plate (Plate 103), which in the original is put down as illustrative of "herpes maculosus et squamosus," has accordingly been changed to that of *pityriasis maculata et circinata.* It is now believed, however, that occasional extensive ringworm cases like this are now encountered; it is probable that it is not uncommon in Austria while rare with us, just the reverse of pityriasis maculata et circinata. The author recognizes this in the present edition, and gives a short account which is supplementary to the ringworm forms. His description, somewhat abbreviated, will be given in his words and with his title.—ED.] "Herpes tonsurans disseminatus presents itself over extended surfaces (abdomen, back, breast) in rapidly successive, small pale-red spots with irregular borders, which present in the center a small scale. Near by, and especially on the lower parts, new spots develop in a few days. The older scales in the center extend irregularly toward the peripheral parts, so that the center may have entirely recovered and the scaliness be found chiefly on the outer portions. Sometimes before this general outbreak an old circumscribed patch may be found. The patches often attain the size of coins. Owing to the peripheral spread and the central involution they are often annular, the central part is finally without scaliness and merely pigmented, the peripheral part still scaly, reddened, and covered with flat adherent scales. In the scales the fungus and spores are usually readily demonstrable. In the histologic examination of the macular

efflorescences there is disclosed a serous and cell exudation, a saturation of the epidermis with consequent parakeratosis. The vessels are dilated. The picture is one of superficial erythema provoked by the presence of the fungus."

In more inflammatory cases transudation of a small amount of serous fluid under the epidermis takes place, vesicles arise, which dry to superficial crusts (tinea circinata vesiculosa; herpes tonsurans vesiculosus of the Germans) (Plate 105). If this type continues to spread with such vesicular formation, it results in the production of larger reddened plaques with peripherally arranged surface, vesicles, and pustules. From drying of the burst or broken vesicles and pustules impetigo-like crusts form (Plate 106). This form is mostly limited to parts of the surface having tender epidermis. We have seen it with people having to do with animals, several times on the inner surface of the arms. Plate 104 shows such a case on the breast. The dried-up pustules of this form leave a slight pigmentation.

Eczema marginatum is a name originally given to a disease involving usually the crurogenital region, which was subsequently found to be due to the ringworm fungus. It arises on sweating, superficially macerated regions, which furnish a good soil for the vegetation of the parasite. The skin becomes infiltrated, reddened, and scaly, and shows peripherally a sharply defined, elevated edge beset with vesicles and crusts. The nature of the region involved prevents the involution which takes place in patches of the disease when seated elsewhere; instead, the skin thickens, and is either reddened or pigmented. Through confluence of several such areas the disease may involve the whole genital region, thighs, scrotum, and extend upward beyond the pubes; it is irregular in outline, and gradually spreads outward. This disease, owing to heat, moisture, and friction of the parts, is very troublesome, itchy, and painful; especially in soldiers after long marches.

In a similar manner to that just described the regions of

the axillæ, the anal fold, and the under part of large loose-hanging breasts in women may be the seat of the disease.

In ringworm, as in favus, the nails may also be involved, together with the disease on other parts or independently (onychomycosis trichophytina). The fungus presses into the nail substance, and it may in this way become opaque in spots or the entire nail may become milky and fragile. Less frequently the nails may be more severely involved—increased in size, bent, and distorted (onychogryposis trichophytina). It is extremely persistent, much more so than ringworm of non-hairy parts, and may even be more so than the disease upon the scalp.

In the islands of the South Sea an endemic trichophytosis has been described by Manson and Nienwenhuis, under the name of **tinea imbricata,** which consists of vesicle and scale formation spreading over the entire body.

Tinea Tonsurans (Tinea Trichophytina Capitis).

Tinea tonsurans, or ringworm of the scalp, presents at first a somewhat similar appearance to a patch of the disease on other parts. These characters are, however, soon lost. The fungus penetrates the hair substance, between the cells of the cortical substance; the hairs become lusterless, break easily, and some fall out. The broken ends show brush-like extremities. Some break off just at the margin of the follicle and appear as black specks in the duct opening. The follicular outlets in the earlier stages are somewhat more prominent, like goose-flesh, from the crowding of cells and fungus. One or several patches may be present, and may attain the size of coins or larger; if two or three are close together, they may fuse and an irregularly shaped area result.

The patches vary in size, and are usually covered with slight scaliness and occasionally with crusting. The fungus tends to press into the hair follicles, and there may develop follicular and perifollicular irritation, with

suppuration and marked exudation; in some cases with considerable circumscribed swelling (tinea kerion). The disease shows no disposition toward spontaneous recovery, though it may remain stationary. [It rarely persists beyond the age of fifteen years, and is only exceptionally met with in the adult.—Ed.]

After clearing the hair with potassa solution the mycelia and spores can readily be seen.

Tinea sycosis, parasitic sycosis, or barbers' itch, is a disease of the bearded parts of the face due to the ringworm fungus. The process may remain a superficial one, resembling somewhat ringworm of the scalp; but more commonly it develops into the classical type of the disease, consisting of considerable lumpiness and nodulation, with more or less hair loss and suppuration.

The trichophyton is conveyed from man to man; frequently, however, from domestic animals to man, as, for example, from cats and dogs to children, from horses and cattle to those whose occupation brings them in contact with such. Shaving also offers a good opportunity for conveyance of the disease.

PITYRIASIS ROSEA (PITYRIASIS MACULATA ET CIRCINATA).

This disease, clinically identical with herpes tonsurans maculosus universalis (generalized tinea circinata or body ringworm), of Hebra, is also thought to be due to a fungus closely related to the trichophyton, although demonstration of the fungus is still lacking. The malady appears as a somewhat extensively distributed eruption over the entire body, but chiefly and usually the trunk and upper parts of the limbs; and consists of characteristic salmon-red, rounded or elliptical macules, exceptionally combined with pinhead-sized vesicles [this must be extremely rare —Ed.], new macules continuing to appear for several days or longer. The macules begin to scale centrally while they spread peripherally. Itching may be present. Occasionally the face, but scarcely ever the hairy scalp,

becomes involved also. Sometimes it appears simultaneously on all parts of the trunk and nearby adjacent parts. After a few months spontaneous healing results, sometimes in less time.

The histologic examination of the macules discloses an inflammatory process in the cutis, dilatation of the vessels. In the cutis and epidermis there is leukocytosic exudation; the epithelium is saturated, finally resulting in the formation of a nucleated horny layer.

Treatment of Ringworm and Allied Affections.—In the treatment of ringworm of non-hairy parts all remedies capable of bringing about active exfoliation of the epidermis are useful. The most important of this group is sapo viridis, which is to be applied to the affected areas as a salve, repeatedly rubbed in and permitted to remain till mild exfoliation is set up. A combination with naphthol is commended by many dermatologists; but, according to our experience, it does not seem to be more efficient than the soap alone. Applications of tar, chrysarobin (as salve or 5 per cent. chrysarobin solution in liquor gutta perchæ), corrosive sublimate (1 to 2 per cent. strength), and iodin tincture are also valuable.

In treatment of the disease upon the scalp, after removal of the crusts or scales in the ordinary manner (see Favus) the hairs of the affected areas are to be extracted, and then one of the antimycotic remedies applied. In general, in addition to those already named, the same remedies employed in the treatment of favus of the scalp may also be used in this disease. Kaposi recommends:

℞ Ol. rusci, 15 (f ʒss);
Sulphur. præcip., 10 (ʒiiss);
Tinct. saponis viridis, 25 (f ʒvj);
Spirit. lavandulæ, 0.50 (ʒiss);
Bals. peruviani, 1.5 (gr. xx);
Naphtholi, 0.5 (gr. viij).—M.
Sig.—External use.

In ringworm of the bearded region it is also necessary that careful depilation should be practised. The remedies to be employed here, as salves, are chrysarobin (with caution), anthrarobin (10–20 per cent.), resorcin, precipitated sulphur; corrosive sublimate (in solution), gray plaster, iodin tincture, and acetic acid:

℞ Acidi acetici, 10 (ʒiiss);
Sulphur. præcip., 2.5 (gr. xxxv).—M.
Ft. pasta (Kaposi).

In trichophytosis of the hairy scalp, as well as in tinea sychosis, the Röntgen-ray treatment has been employed, and the results, especially in the latter disease, have been very favorable. [Sabouraud has lately employed this method with excellent results in ringworm of the scalp. —Ed.]

The treatment of ringworm involving the nails is the same as that employed in favus of the parts.

TINEA VERSICOLOR.

Tinea versicolor, pityriasis versicolor, chromophytosis, or, as popularly believed, "liver spots," is due to invasion of the epidermic tissue by a vegetable parasite, the microsporon furfur (Eichstedt). This fungus is readily recognized under the microscope by the bunching of large masses of spores with mycelial threads between (Plate 65, Fig. *f*). The fungus invades the outer skin; the hairs and nails are not involved. It is to be found especially in the uppermost layers of the epidermis. With the exception of the face, hands, and feet, the eruption may be found upon any part of the body. As a rule, its chief seat is on the trunk, and especially the upper part, particularly on the anterior aspect. It is practically never seen elsewhere except in connection with the disease on this region. The lower trunk, the axillæ, flexors of the arms, the crural fold, and the poplitea are sometimes involved.

[In several instances the lower part of the face has also been invaded, extending from the neck.—Ed.]

The eruption consists of variously sized, yellowish, brownish, or fawn-colored spots, not elevated, or at least not perceptibly so. They may become confluent and form large irregular areas; even the whole upper trunk may be uniformly covered. There is usually slight branny scaliness, visible upon close examination. The disease begins with one or several spots, and then gradually spreads and increases. It is usually slow in its progress, and lasts for years, practically showing little if any tendency to spontaneous disappearance. In sensitive skins, especially in women, the eruption may have a pale-red tint. It gives rise to no discomfort, except slight itching when the patient is heated, although exceptionally itching may be quite a factor.

The transference of the fungus has been proved; but it apparently requires a peculiar susceptibility of the individual. It is found frequently in phthisical patients, and such persons, as well as others affected, are frequently subject to recurrences. After long continuance the disease may finally disappear in advanced years.

Treatment.—Soap-and-water baths; applications of tar, chrysarobin, naphthol, iodin tincture. Wolff recommends alkaline baths, and after the baths the rubbing in of an ointment containing corrosive sublimate, one-fourth to one grain to the ounce.

ERYTHRASMA.

Erythrasma occurs from invasion of the cutaneous tissue by the microsporon minutissimum (Burchhardt, v. Bärensprung). This fungus permeates the epidermis, and consists of numerous fine threads and conidia; Dr. Reale (Clinic of de Amicis) has succeeded in making cultures. The disease is seen especially where two surfaces come in contact, as on the inner surfaces of the thighs, in the axillæ, etc.; and is characterized by slightly scaly, palm-

sized, brownish spots. The skin in the involved regions is often macerated, presenting intertrigo. The affection runs a very chronic course.

Sometimes the skin in these parts becomes macerated, intertrigo developing, and as a consequence the brownish color is changed into a reddish. The affection is much more common with men than with women. Contrary to the fact in tinea versicolor, the scales in this disease cannot be so readily scraped or scratched off. Riehl has exceptionally seen the malady on the mons veneris, the belly, and back. The affection is chronic.

The **treatment** is substantially the same as in tinea versicolor.

Piedra.—The cause of piedra is the trichosporon giganteum, found by Unna; it is a mycelial fungus which is characterized by the remarkable size of its spores. The malady, which is endemic in England and Colombia, is found exclusively on hairy parts, and shows on the hair shaft numerous white nodules.

Trichomycosis Palmellina (Pick).—This malady arises, according to Pick, from the glutinous masses of a coccus, which penetrates the hair follicle and completely envelops the hair, without, however, giving rise to atrophy. Clinically the hairs of the axillary region or the genitalia are covered with gluey red masses. At the same time hyperidrosis exists. Sometimes red-sweat secretion (chromidrosis) was observed. The affection is to be only found in sandy or red-haired blondes.

A fungus quite similar to the above two (**trichomycosis capillitii**) has been described and cultivated by Winternitz.

ACTINOMYCOSIS (PLATE 119).

The cause of this malady is the ray fungus, actinomyces. In the microscopic examination of the discharge one finds

numerous bright-yellow grains, about the size of grains of sand, which are composed of the fungus. When one presses this grain it breaks up into individual sectors, which themselves are divided dichromatously. The actinomyces found in men and animals are identical. It is observed in cattle, horses, and swine. Persons having much to do with these animals are, according to observations, more frequently attacked than others, although a direct conveyance of the disease is up to the present unproved. Most frequently the infection takes its start in a decayed tooth or on the tongue. The fungus can, perhaps, find entrance along with vegetable substances into the alimentary tract, and in this manner, or also by the respiratory tract, give rise to infection. Very often the primary abscess of the jaw or the tongue remains localized there; mostly, however, it spreads onto the neck and to the rest of the organism. There appear on various parts of the surface chronic inflammatory processes, phlegmonous abscesses, and fistulæ, in the pus of which the characteristic fungus can be readily demonstrated. The actinomycotic lesions are mostly surrounded with callous formations. The process extends downward in the tissue as a granulation-tissue growth, and can extend to the bones. These inflammatory processes are often painful and may be associated with fever. The duration of the malady depends upon its site. For the most part it is extremely chronic, and long-continued suppuration and fever result in the patient becoming marasmic. In the severest cases it finally results in chronic pyemia and amyloid degeneration.

Treatment.—If early recognized, the disease may be limited by energetic cauterization or by surgical measures (thermocautery). Potassium iodid has been recommended for internal administration.

BLASTOMYCOSIS.

In late years, especially by American authors, has been observed a peculiar affection of the skin, due, it is thought,

to the yeast fungus. The first communication on this subject was by Gilchrist and Rixford. It presents predominantly upon the face and neck as lentil-sized nodular growths, which secrete a thick, viscid fluid. In the microscopic examinations of this secretion yeast fungus is found in abundance. In autopsies of such cases the yeast cells can also be demonstrated in the visceral organs. Buschke has succeeded in inoculation experiments with cultures of this organism in producing similar nodules. At the same time it is to be said that many authors deny that the yeast fungus is pathogenic in man, and look upon their presence as accidental or secondary. When the nodules are in numbers and coalesce tumors result, which bear resemblance to those of granuloma fungoïdes. Löwenbach and Oppenheim had the opportunity to observe this affection in a field worker, and emphasize the curative value of potassium iodid in bringing about improvement.

THE ANIMAL PARASITES OF THE SKIN.

The animal parasites of the human skin may be conveniently divided into two classes:

1. Those which live in the skin or subcutaneous tissue (dermatozoa); and 2, Those which are only found and remain on the skin for the purpose of nourishment (epizoa) and give rise to conditions of irritation.

SCABIES.

In the first class of greatest importance is the *acarus seu sarcoptes hominis* (Plate 114, *g* and *h*), the cause of scabies or itch, an affection of the skin attended with intense itching. The impregnated female mite penetrates the upper layers of the epidermis and makes a burrow in which she deposits her eggs (Plate 114, *f*). After the larvæ have been hatched out they begin to burrow also, and the irritation thus provoked gives rise to irritation of the skin, increased by the uncontrollable scratching, and

to various inflammatory lesions of the skin. The cork-screw-like burrow between the corneous layer and the rete shows the head or extending end and the tail or traversed end (Plate 114, c). At the head end the mite itself can usually be detected, with a magnifying glass, as a white point. It is seated in a minute quantity of fluid, which forms a vesicle and which is secreted by the mite. One is able [if possessed of considerable dexterity and good sight—Ed.] to pick out the mite with a fine needle.

Scabies exhibits usually a typical distribution, and this consists of the surfaces between the fingers, the flexor surfaces of the hands, the elbow joint, the anterior axillary fold, the penis, the nipple and areola in women, the gluteal region, and the inner sides of the feet. In addition to the burrows, which may be exceedingly scanty, are to be found pinhead-sized papules, with their surface scratched and covered with a minute blood-crust. As a result of reactive inflammation and mixed infection pustules arise (scabies pustulosa, Plates 111 and 112). Inflammatory nodules develop, especially on the penis and also on the gluteal region. In long-continued cases, eczema from scratching and irritation and pigmentation are seen. In severe cases the entire body is covered with nodules and pustules, and, besides these, calloused thickenings of the epidermis.

Scabies is mostly conveyed by intimate contact, as in beds. Nurses, in the pursuit of their occupation, are, according to general observations, rarely infected.

Treatment.—Thorough application of one of the salves to be mentioned, with special care for those parts of the body which are most favored by the acarus, as between the fingers, hands, elbows, axillæ, shoulder region, breast nipples, the waist region, lower abdomen, genitalia (especially in men), nates, knee region, and ankles. After the rubbing the patient is enveloped in a woollen cover or puts on woollen underwear. As a rule, this rubbing is repeated morning and evening for two days, and on the fourth day a bath is to be taken. The patient's bed is to

be carefully looked after and disinfected. For inunctions the following are recommended:

℞ Naphtholi, 15 (ʒiiiss);
Cretæ alb., 10 (ʒiiss);
Saponis viridis, 50 (ʒxiiss);
Adipis benzoinat., 100 (℥iij).—M.
Ft. unguentum (Kaposi).

Wilkinson's ointment, as modified by Hebra:

℞ Sulphur. sublimat.,
Ol. fagi, āā 40 (℥i ʒij);
Saponis viridis,
Adipis benzoinat., āā 80 (℥iiss);
Cretæ alb., 5 (gr. lxxv).—M.
Ft. unguentum.

Or the salve recommended by Weinberg:

℞ Sulphur. sublimat.,
Styracis liq.,
Cretæ alb., āā 20 (ʒv);
Saponis viridis,
Adipis benzoinat., āā 40 (ʒx).—M.
Ft. unguentum.

Or Paltauf's styrax mixture (styracis, 4 parts; ol. olivæ, 1 part).

Or Peruvian balsam, about 9 grams (ʒij) for each inunction.

Or

℞ Potass. carbonat., 25 (ʒvj);
Sulphur. præcip., 75 (ʒxviij);
Ol. lavandulæ,
Ol. caryophylli, āā 1 (gr. xv);
Adipis benzoinat., q. s.
Ft. unguentum.

Hardy's method for rapid cure is as follows: The patient is thoroughly and vigorously rubbed with sapo viridis over the entire surface, after which he takes a lukewarm bath. After the bath he is rubbed with Hardy's modification of Helmrich's ointment:

℞ Sulphur. sublimat.,	20 (ʒv);
Potassii carbonat.,	10 (ʒiiss);
Adipis benzoinat.,	80 (ʒiiss).—M.

The salve is permitted to remain on for twenty-four hours, and then the patient again takes a bath. Epicarin, as a salve of 10 per cent. strength, has also been commended.

The irritation brought about by the use of these active remedial applications, as well as that which has resulted from the scabietic irritation itself, is to be treated according to the rules governing the treatment of eczema.

The hair-follicle mite, the *acarus folliculorum* (*demodex folliculorum*) (Plate 114, Fig. *i*), is a harmless parasite, which is observed frequently in acne cases in the glandular ducts and sebaceous glands, but provokes no irritation worthy of mention.

Cysticercus Cellulosæ Cutis.—The larvæ of tænia solium, the *Cysticercus cellulosæ*, live in pigs, deer, dogs; and also in man, acquired by swallowing the embryos. It is to be found most frequently in the eye and brain, but also in other organs, as well as in the subcutaneous tissue, giving rise to an oval nodule. In the connective tissue the growth reaches about the size of a pea, and causes no discomfort. Owing to its seat in internal organs, however, the disease is dangerous. The cysticercus seldom dies spontaneously; in such event the nodule slowly undergoes calcification. Hundreds of such tumors can be found in the subcutaneous connective tissue.

Quite similar hazelnut-sized tumors can be caused by the **echinococcus,** the larvæ of the **tænia echinococcus,** less frequently on the thigh, on the nose, and the tongue.

The filaria is met with predominantly in southern Asia; it is of thread-like form and resembles a catgut.

A tropical parasite, the *filaria medinensis*, the guinea-worm, is to be found in the subcutaneous tissue, especially in the neighborhood of the ankle joint, etc. The larvæ probably gain access through drinking-water. The painful cutaneous symptoms are accompanied by fever. There arises often a painful tumor or ulcer, in which the worm is to be found; the disease may, however, disappear without these occurrences under the skin.

Pulex penetrans, the sand flea, comes from South America. It bores into the skin, especially the lower leg and toes, where inflammatory lesions with pus formation, and even lymphangitis and necrosis, may be caused.

The **harvest bug** (**leptus autumnalis**), as well as the **bird louse** (**dermanyssus avium**), and the **barley mite** (**acarus hordei**) may also provoke hive-like lesions of the skin.

The tick, *ixodes ricinus*, bores with its head into the skin, and gives rise to purulent processes.

CREEPING DISEASE.

By this name Crocker has designated a peculiar skin affection which occurs most frequently in children, or upon exposed situations in adults. In Vienna, Professor Neumann, and subsequently Dr. Ehrmann and Dr. Rille, and Russian and other English physicians, have also observed it. It appears as an itching or burning spot, from which a fine red elevated line extends through the skin in any direction. This line is either straight, zigzag, or bowed, quite irregular, and lengthens from day to day. The fresh progressive line is bright red, about 1 mm. wide, and slightly elevated; the older lines are flat and pale brown. The progress is not constant, but limits itself to a few hours daily, especially in the night.

It is believed that an animal parasite which bores similarly to a mole is the cause. Efforts to secure the same

have up to the present time been fruitless. Crocker believes it is a form of filaria. Rille has found the malady most frequently in children who sit and creep around on the floor.

Therapeutically it is advised that the progressive end of the line be excised; according to experience, it is necessary that considerable surrounding tissue be included.

In eczema of the head and in foot ulcers in those who pass the night sleeping in the open the larvæ of flies can find attachment and produce mine or burrow-like excavations (**myiasis externa**).

PEDICULOSIS.

To the second class of animal parasites belong the pediculi or lice: the pediculus capitis (Plate 114, *b*), pediculus vestimenti seu corporis (Plate 114, *c*), and pediculus pubis (Plate 114, *d*). The bite of the louse is attended with intense itching, which causes scratching and, as a further consequence, possibly eczema, as we have already intimated.

Pediculosis Capitis seu Capillitii.—In head lousiness, in consequence of the exudation and eczematous irritation produced on the surface, tangling and matting of the hair, and even plica may result. The scalp of such a person has a mouldy smell, and only after removal of the hair, which requires much care and trouble, can the scalp with its enveloping crusts be seen. Lice, nits (ova), attached to the hairs, are to be found, and even maggots may be present, and complete the picture in cases of gross neglect. [Fortunately such extreme cases are rarely, if ever, seen in this country.—Ed.]

Pediculosis Corporis seu Vestimenti (Plate 114, *c*). —The **clothes** or **body louse,** which is considerably larger than the head louse, provokes stripe-like scratch marks on the skin, and in neglected cases may bring about eczema, furuncles, and abscesses. The clothes louse is to be found especially in the neck region and around the

waist, in the folds or seams of the clothing. In consequence of the continued scratching, in addition to the eczema and pigmentation, there can also result, in places where the papillæ have been damaged by the finger-nails, even scars.

Pediculosis Pubis.—The pediculus pubis, or crab louse, is to be found on all hair regions except the scalp, although its common habitat is the pubic region. The eggs, or nits, as with those on the scalp, are found glued to the hair shaft (Plate 114, *a*). By careful inspection the lice may be discovered close to the skin at the root of the hair.

In addition to the artificial eczema produced by the irritation and scratching, we not infrequently notice on the trunk and also on the thigh bluish rounded spots (maculæ cæruleæ) (Plate 113), which, according to Mallet, are said to arise from injection of secretion from the salivary glands near the middle part of the breast; these marks disclose the migration of the crab louse over the skin. Duguet could, by injecting crushed-up crab lice, produce analogous discolored spots. In men with markedly hairy thighs the crab louse can remain in this region a long time, and give rise to frequent recurrences.

The bed bug (*cimex lectularius*) lives in the crevices of furniture, especially beds, and during the night feeds upon man. Its bite gives rise to papules or wheals. Similar lesions are provoked by the *pulex irritans*, common flea, although the central hemorrhage is more distinct. The female lays its eggs in the clefts of floors and furniture and in dusty places. Such eggs have even been found on the body of dirty individuals.

In this class also belongs the several kinds of gnats (*culicidæ*) and flies (*stomoxyidæ*) which suck blood and provoke wheals and other symptoms of irritation.

Also many *Œstridæ* (*myiasis dermatosa æstrosa*, O. Nagel) are to be found, chiefly in tropical countries, on the skin of man, and cause boil formation.

Rasch saw an obstinate case of pruritus in a nervous woman which was provoked by **chicken lice** (**menopon pallidum**). This parasite can sometimes be found on the skin of persons who have to do with chickens without (excepting a feeling of burning of the skin) giving rise to any disturbance.

PLATE 1.

Pompholyx.

S. J., aged 25 years, a laborer, was admitted Jan. 16, 1897. The patient had sought hospital-treatment for the relief of swelling and tenderness of the feet. Sweating of the feet had existed in a mild degree since early childhood. He had previously been an inmate of the hospital in 1894, with articular rheumatism; and at that time the soles of the feet were already the seat of numerous disseminated and confluent plaques of loose epidermic scales and some small vesicles; the nails were thickened and brittle.

Status Præsens.—The malleolar regions are swollen and tender upon pressure. The soles are covered with sweat and are studded with pinhead-sized red papules, persistent under pressure; similar lesions are seen at the edges of the soles, less abundantly on the dorsum of the feet and lower instep. In many places these lesions have changed into vesicles; and in other places, especially the plantar region, these vesicles have become confluent and form large blebs with milky contents. The skin of the entire plantar surface, the borders, and dorsum of the feet, is red, as if inflamed.

Jan. 25.—The vesicles, for the most part, have become confluent and form larger lesions, so that both plantar regions are covered with lentil- to bean-sized milky blebs. The borders of the soles show numerous minute hard epidermic granules, which are seated in the glandular outlets and which can be readily pressed out. Under the uplifted epidermic flakes there is apparently slight depression covered with new epidermis having distinctly visible gland-ducts. In some blebs the secretion has become white, thick, and cheesy. The epidermis between the plaques and more active spots is beset with numerous minute, hard, deep-lying granules having a yellowish aspect. The epidermis of the soles is swollen, sodden-looking, and whitish, and in places reddened as if the result of maceration. The palms are moist.

Examination of the cheesy contents of the blebs mentioned showed epithelium, epidermic flakes, and débris.

The patient was, after a month's treatment with a macerating salve, discharged; the parts had become covered with new epidermis.

[In the German edition the author describes this plate under the heading "hyperidrosis of the feet with vesicle- and bleb-formation." It pictures to the English and American mind, however, what is usually considered pompholyx; although this latter is rarely limited to the feet, as in this instance. In the text, however, the author refers to this plate when describing pompholyx. The salve referred to is doubtless the unguentum diachyli, employed as in hyperdrosis (*q. v.*).—Ed.]

PLATE 2.

Milium.

I. J., aged 18 years, servant-girl, came under notice July 23, 1897.

Status Præsens.—On the face are to be seen grayish and yellowish-white, hard, irregularly scattered, pinhead-sized elevations. By puncturing the overlying epiderm the contents, consisting of firm white bodies, may be readily scratched or pressed out.

PLATE 3.

Adenoma Sebaceum. Comedo. Acne.

F. G., aged 22 years, workman, admitted Feb. 18, 1896, states that when 17 years old the inflammatory acne-nodules first appeared; at this time he also noticed the appearance of black points, and the nodular tumors, lentil to pea in size. The disease had now lasted five years.

Status Præsens.—The man is well developed, pale, with moderate amount of flabby panniculus adiposus. The extensor surfaces of the extremities show lichen pilaris. On the forehead, alæ of the nose, especially in the nasolabial folds, on the cheeks, more particularly toward the scantily-bearded portion, numerous comedones are to be seen; scars from former suppurating follicles, acne-nodules, and adenoma in the region of the chin. In the clavicular region are sparsely-scattered comedones—in great numbers, however, over the sternum; also adenomata, and scars varying in size from a pea to a dime, resulting from similar previous growths which had suppurated.

The back is thickly beset with acne-lesions, brown pigment-spots, and comedones.

PLATE 4.

Acne.

M. A., aged 17 years, somewhat pale, had suffered for several years from continued outbreaks of papules and pustules on the face, neck, shoulders, and back, having their seat in the sebaceous glands and ducts. The lesions vary in size from a pinhead to a lentil, the larger lesions showing in the central part purulent contents.

PLATE 5.

Erythema Multiforme (Erythematous and Erythemato-papular).

G. J., aged 32 years, a waiter, was admitted Apr. 20, 1896. Two days previously an eruption appeared on the face and on the hands and feet.

Status Præsens.—Patient is strongly built. An eruption consisting of bluish-red, slightly-elevated spots, with a bright-red areola, becoming pale upon pressure, is to be seen, symmetrically arranged, on the dorsal surface of both hands, the extensor aspects of both forearms, and likewise upon the lower extremities and the large toes; also the same characteristic eruption upon the forehead. These efflorescences are for the most part circular in shape, here and there several running together and forming dollar-sized areas. The palms, the soles, the mouth, and throat are free.

Following the internal administration of oil of mint and oil of eucalyptus the eruption gradually flattened without any fresh exacerbation, and disappeared with very slight desquamation. The patient was discharged cured eight days after admission.

PLATES 6 and 7.

Erythema Multiforme (Vesicular and Bullous).

S. A., aged 16 years, locksmith's apprentice, admitted Mar. 18, 1897, noticed three days previously, on awakening in the morning, an eruption consisting of small translucent vesicles seated upon a red base. The first lesions were observed on the axillary folds and the flexor surface of both forearms. Itching was quite marked. The individual vesicles grew larger, and new lesions appeared, in the course of a few days, on the trunks and extremities. During this time the patient had feelings of heat and chilliness.

Status Præsens.—Patient small, slender, with very little fat-tissue. No elevation of temperature; pulse 80, and regular. The urine contained traces of albumin and nucleoalbumin.

Efflorescences are to be seen on the face, especially about the chin, on the neck, profusely on the anterior thorax, on the abdomen, back, and upper and lower extremities. They vary in size from a pinhead to a silver quarter; are pale red, rounded, and somewhat elevated like wheals. They become somewhat paler on pressure, here and there leaving a yellowish tinge. In certain regions, as the anterior thorax, the clavicular region, and the outer side of the forearms, they have become confluent, forming large irregularly shaped groups and areas. In the center of many of the efflorescences there is a blood-crust. Near by these efflorescences, scattered over the entire surface, are countless millet-seed- to bean-sized vesicles with clear contents, and for the most part well distended. Where the vesicles are broken the reddish base is observed to be covered with dried yellowish secretion. In the neighborhood of the left collar-bone is an accumulation of thick hemorrhagic crusts. On the back are two or three blebs with hemorrhagic contents. In this region also are numerous scratch-marks. There are a few blebs on the dorsal surface of the feet. The volæ manus, the soles, lower part of both legs, and the joints are free. The mouth and throat are likewise exempt.

Mar. 19.—General condition good and no fever.

Mar. 22.—Numerous blebs filled with pus; some hemorrhagic. No new lesions.

Mar. 23.—Erythematous spots have disappeared; superficial abrasions mark the sites of burst or broken blebs.

Mar. 25.—Temperature 37.7° C. Many of the abrasions are skinning over.

Mar. 29.—Some fresh blebs on forearms and face. Temperature 38.3° C.

Mar. 31.—The abraded areas have skinned over. Highest temperature 37.8° C.

Apr. 1.—The skinned-over abrasions are still somewhat elevated. Fresh scattered and closely-crowded lentil-sized blebs with clear contents have appeared on forehead and cheeks. Temperature normal.

Apr. 4.—The blebs on forehead and face have become purulent.

Apr. 5.—Evening temperature 39.4° C.

Apr. 20.—The skinning-over process is almost complete; the epidermis on the places of former blebs is still quite red, but there is now no elevation.

Apr. 26.—Pale reddish-brown pigmentations mark the sites of the lesions.

Apr. 28.—Discharged cured.

Tab. 7.

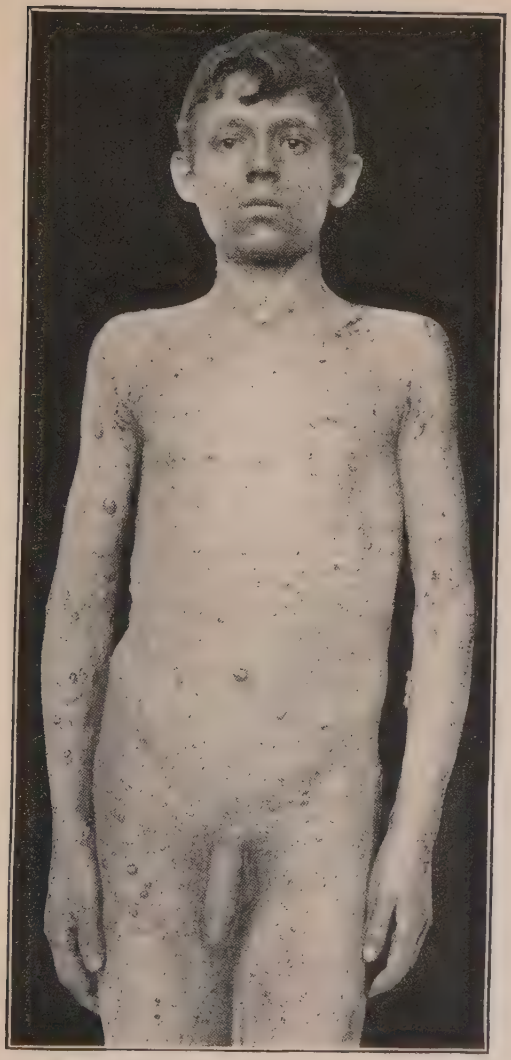

PLATE 8.

Erythema Exsudativum (with Bullous and Hemorhagic Lesions).

M. M., maid, aged 22 years, admitted April 22, 1891.

For three weeks she had had on the dorsal surface of both hands an eruption accompanied with a sensation of heat and burning. For a longer time she had not been feeling well, quite frequently having diarrhea; and for a few months menstruation had been absent.

Status Præsens.—The skin of the back of both hands is moderately swollen, the swelling extending on to the extensor surface of some of the fingers. The epidermis is somewhat furrowed and wrinkled, of a brownish color, and with here and there irregular ecchymoses. On the dorsal aspect of the thumb and on the dorsal surface of the hand above the middle and third fingers there are flaccid blebs; in some places the epidermis is entirely gone, disclosing superficial ecchymotic abrasions. The contents of the blebs are serous, somewhat clouded. In other parts of these surfaces the epidermis is broken, loose, and having resemblance to a superficial burn.

The right angle of the mouth is fissured, and also shows partly healed herpatic lesions. On the left breast, on the dorsal surface of the left foot, and on the right thigh are to be seen irregularly scattered erythematous efflorescences. There is some intertrigo, vaginal catarrh, and fissures about the anus.

Treatment.—Starch dusting-powder, unguentum simplex, and unguentum diachyli. On May 16 the patient was discharged, cured.

PLATE 9.

Erythema Multiforme (Papular and Nodose).

G. I., aged 11 years, admitted Apr. 20, 1896; discharged May 3, 1896. For two weeks he had noticed the appearance, without known cause, of an eruption on both arms and legs. He had previously been quite healthy.

Status Præsens.—The papules are to be seen on the extensor surfaces of the upper extremities and upon both anterior and posterior aspects of the lower extremities. The trunk is free. The eruption consists of millet-seed-sized papules, extending into the cutis and somewhat elevated above the skin-level; on their summits is, for the most part, either a minute blood-crust or -scale. In some places, and more especially in the popliteal spaces and over the patellæ, are observed dime- to shilling-sized bluish-red nodes (erythema nodosum).

Treatment.—Sodium citrate.

In the course of the disease there was slight hemorrhage into the disappearing papules, which, however, was rapidly absorbed. The nodose lesions gradually disappeared, undergoing the usual color-changes.

PLATE 10.

Purpura.

M. M., aged 33 years, coachman, admitted Apr. 23, 1897, stated that for the last eight days he had felt exhausted and sick, and had observed spots in the skin. Similar spots he had noticed several times previously; but as they had disappeared without discomfort or medical aid he had never considered them of any moment. He sought the hospital this time owing to the feeling of general weakness and depression.

Status Præsens.—Patient is large, well built, but pale. The gums are livid and furrowed, and bleed easily; conjunctivæ jaundice-colored. The heart-tones are somewhat dull; pulse 84, and soft; spleen not enlarged. There is neither sugar nor albumin to be found in the urine. Over both ankles and on the dorsal aspect of both hands there was slight edema. On the lower extremities, about the hair-follicles, are pinhead- to lentil-sized recent and old hemorrhages, here and there showing a tendency to be closely set together and in rows. In addition to these lesions are to be noticed rounded and more or less diffused violaceous spots on the lower legs, in the central part of which the follicular hemorrhages are more crowded. In these latter places the skin has a succulent feel. Scattered hemorrhages are also noticed on the trunk.

Apr. 30.—Urine shows considerable urobilin. In sediment, hyaline cylinders and a few blood-corpuscles.

May 1.—On the inner side of the upper part of both thighs, especially the right one, fresh follicular hemorrhages of a reddish-brown color, and bluish, livid spots have appeared; the latter are so extensive as to become confluent.

May 5.—The brownish-red hemorrhages and the livid spots begin to change to a yellowish tinge. The patient suffers pain in the legs.

June 1.—The calf-muscles feel hard, and the patient when attempting to walk has considerable pain in these parts. The gums are still swollen, the inner side showing numerous minute hemorrhages.

June 20.—There is considerable pain in knees and hips. Evening temperature rises to 39.5° C.

July 1.—The hemorrhagic spots on trunk and thighs have, for the most part, been absorbed. The calves are softer to the feel.

Aug. 19.—The diarrhea, which had existed for some time, alternates with constipation. Urine-examination shows considerable indican and skatoxyl. There is a somewhat painful swelling, soft in character, about the knees; the overlying skin unchanged.

From now on no new lesions in the skin were observed. The patient still suffered, however, from effusion about the knee-joints, marked debility, and inability to walk any distance.

PLATE 11.

Purpura.

S. M., aged 16 years, working-girl.

Status Præsens.—Patient small and spare; pallor of skin and mucous membranes, and slight enlargement of the heart toward the right. No pulse-irregularity. Menstruation is not yet established. Hemoglobin, Fleischl, 55 per cent.

For four days, beginning on 17th, the patient had noticed hemorrhages in the lower extremities. She worked in a laundry, standing during the whole day.

On the lower extremities, from the middle of the thighs and extending down over the entire lower legs, are lentil- to pea-sized, scattered and confluent cutaneous hemorrhages, some of which already show a change to a brownish tint.

24th.—Eight days after the beginning of the outbreak the general health seems good; the efflorescences yellowish and some becoming skin-color.

PLATE 12.

Purpura Rheumatica (Fulminans).

J. M., aged 38 years, clockmaker, admitted Sept. 12, 1897.

History.—Nine years previously patient had a pleuritis. For the past four years has had attacks of pain in the large toes, lasting four to six weeks. Has been addicted to drink. His present disease began on Aug. 28 of this year, with stinging in the heels and the appearance of small red macules on the lower extremities. The pain and the spots disappeared in the course of several days. There soon followed pain in the knees; later in the elbows, hands, and finger-joints, accompanied with swelling of the painful parts. At this time the patient noticed the appearance of dark-brown macules on both forearms; these spots increased rapidly in size, exhibited superficial vesicle-formation, and gave rise to marked tenderness and pain. Patient was debilitated, feverish, and without appetite.

Status Præsens.—The man is large and strongly built, with well-developed panniculus adiposus. Lungs, heart, and abdominal organs apparently normal.

The face is decidedly reddened; the left cheek is somewhat infiltrated; on the latter some lentil- to bean-sized spots, violet to blackish in color, without elevation or tenderness on pressure. On the left ala nasi is a reddish-brown hemorrhage. The entire outer border of the right ear is hemorrhagic, of a blue-black color, and very painful. The mucous membrane of the mouth and throat is normal. The right upper extremity is swollen and both at shoulder and elbow held in flexed position. On the outer side of the arm is a dime- to quarter-dollar-sized patch of dark-violet skin; the overlying epidermis is elevated as in a blister, and the whole area is surrounded by a red areola. Besides this, several painful, partly pale-red and partly dark-red spots are to be seen near by. On the inner side of the arm is a palm-sized dark-violet area similar to the large spot just described. Toward the axilla is a spot which already has begun to change to a yellowish color.

The joints of the left arm and forearm are also swollen and tender, and present similar, but smaller spots. Both knee-joints are swollen and tender and the skin reddened. Over the ankle-joint are several spots, which had already become

brownish. The other joints of the leg and foot are not swollen. The inguinal glands are unaffected.

Urinary examination disclosed specific gravity 1020, some albumin, but nothing else abnormal. An examination of the blood showed a slight leukocytosis.

Treatment.—Sodium salicylate 4 grams (60 grains) pro die.

Sept. 14.—Numerous elevated red spots, with pale-red areola and markedly itchy, are to be seen on the outer side of the right and anterior aspect of the left thigh. Temperature up to 38.1° C.

Sept. 17.—Numerous lentil- to pea-sized, elevated, hemorrhagic, itchy papules have appeared on the thorax. Temperature 39.2° C.

Sept. 20.—Hemorrhage has taken place into the left ear-muscle; the left foot is edematous. Passing large quantity of urine.

Sept. 22.—The joints are again much swollen. Fresh outbreak of hemorrhages on thorax, abdomen, and thighs. Temperature 38.7° C.

Sept. 27.—The flexor muscles of the right forearm, close to the elbow-joint, markedly inflated and painful. Fresh hemorrhages in the left loin. On the hemorrhagic patches on the upper extremities superficial ulcers have appeared.

Oct. 3.—The hemorrhagic spots are being slowly absorbed. The swelling and tenderness of the joints are fast disappearing. Temperature normal. The ulcers on the arm are granulating. Zinc-oxid salve ordered.

Oct. 19.—Albumin no longer in urine. The ulcers on the left arm completely healed; on the right are still two small ulcerations covered with abundant granulations.

Oct. 28.—The affected areas are seen to be slightly pigmented. Patient was discharged cured.

PLATES 13 and 14.

Purpura (with Papular and Bullous Lesions; Leukemia).

C. P., aged 67 years, was admitted Mar. 19, 1903. For the preceding fourteen days the patient had felt unwell, and had frequent severe headaches. About eight days ago his wife noticed the appearance of efflorescences on the left side of his head; these were of a red color. In the next few days the eruption had spread over the entire head, face, trunk, and extremities—at first more or less discrete, but later becoming crowded. A physician who had been called in had prescribed a white salve.[1] The general condition of the patient grew worse from day to day: frequent chilliness, thirst, feeling of languor, and continuous headache. The color of the eruption became darker and darker, and the eyelids began to swell. The patient on entering the dispensary collapsed, and was placed in the hospital department.

Status Præsens.—Patient is of middle size, and well-nourished; the visible mucous membranes pale and cyanotic. Respiration normal, pulse thready, and temperature 97° F. (36.1° C.). Mentality undisturbed; but there were severe headache and marked debility.

The face of the patient, especially the right side, is considerably bloated and of a livid blue-red color; the edema of the eyelids is so great that they can scarcely be opened. On the forehead, at the border of the hair, at the root of the nose, at both inner angles of the eyelids, in the nasolabial furrow, and on the under lip and chin, are to be seen variously-sized, thick, yellowish and bloody-brown crusts. On the left side of the forehead is a well-distended bleb, 6 cm. in diameter, and containing serous fluid, while similar, but smaller, blebs are to be seen scattered over other parts of the face. The skin immediately surrounding the lesions is, for the most part, reddened and infiltrated, and elevated slightly above the normal skin; the base of these lesions, as shown where the bleb walls have been broken or displaced is of a shining bright-red color. In addition to these bullous lesions are to be found numerous livid-red lentil-sized papular efflorescences; in some of which the central part shows incipient small vesicles with clear contents.

[1] The remains of the salve are to be seen in the accompanying black-and-white illustration, inasmuch as it could not be removed.

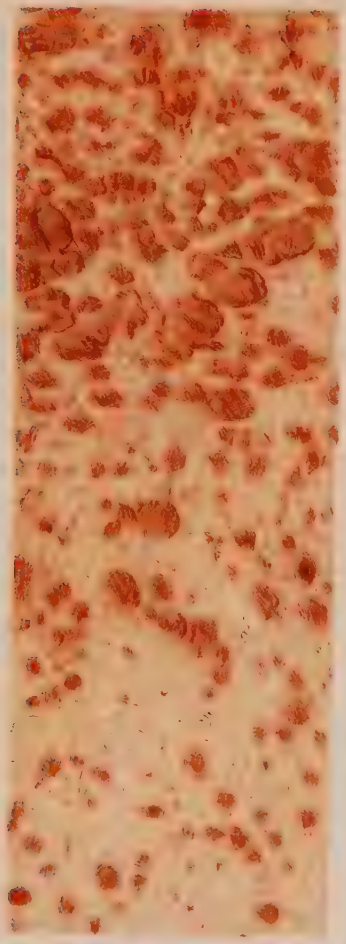

The skin of the trunk and extremities is the seat of similar lesions. In the neighborhood of both shoulder blades, of the clavicle, the outer side of the thighs, and extensor aspects of the elbows, and in the groins, through the confluence and displacement of the uplifted epiderm, the reddened corium is laid bare; on the sides and middle part of the thorax are still to be seen intact blebs of varying sizes, numerous and crowded together; while on other parts the papular efflorescences predominate. These various lesions are seen in all stages. Along with small bright-red fleabite-like points are also to be seen millet-seed to pea-sized, tolerably flat papules, whose livid color increases with their growth. The larger of these carry on their middle point a small vesicle, and this gradually develops into a bleb. In spite of all medical efforts the patient sank rapidly, death occurring sixteen hours after coming under observation.

Autopsy-findings.—Leukemia lymphatica (hyperplasia glandularum lymphaticarum, intumescentia leucæmica lienis et hepatis, medulla ossium rubra). Hæmorrhagiæ pleuræ et pulmonum; hæmorrhagiæ et necroses cutis bullosæ.

Blood-findings (Cadaver Blood).—Proportion of white to red corpuscles 1 : 14; 5.6 per cent. (small) lymphocytes; 3.1 per cent. large, single nucleated leukocytes; 1.3 per cent. polynuclear leukocytes.

[This rare case, somewhat resembling the malady or variety of purpura, usually known as Schönlein's disease, would seem to be an example of some obscure grave systemic infection with mixed cutaneous manifestation of erythema multiforme and purpura as a part of its symptomatology.—Ed.]

PLATE 15.

Erythema Scarlatiniforme.

F. K., aged 39 years; a private patient.

In 1884 the patient, after taking some powders which were ordered by a physician for a persistent headache, was the subject of a spreading erythema which invaded the entire body. This was followed by an epidermal exfoliation, the skin coming away in large pieces; the soles of the feet, as shown in the accompanying illustration, coming away in one piece. The malady ran its course in six weeks. In the years 1885 and 1886 he had two attacks, each of four to five weeks' duration and with the same behavior as the first outbreak, although the exfoliation was not quite so extensive, but the soles, as before, came away *en masse*.

On November 1, 1902, the patient consulted his family physician concerning a bloody expectoration. In the examination no cause for this expectoration was discovered, and the physician prescribed some compound tincture of cinchona. Three days later the patient was again attacked with a rapidly spreading scarlet-fever-like eruption, accompanied with fever and gastro-intestinal disturbance. The skin of the body subsequently exfoliated in small lamellæ, while that of the palms and soles, which had remained pale, exfoliated in large sheets. Under symptomatic treatment the patient gradually made full recovery, no trace of the disease being left.

[In all probability, as the author states, this was an example of dermatitis medicamentosa, of the scarlatiniforme type, a variety that is occasionally observed following the ingestion of cinchona or its preparations.—Ed.]

PLATES 16 and 17.

Dermatitis Exfoliativa.

A. T., aged 32 years, a domestic.

The patient was attacked when aged 12 years, for the first time, with an eruption exactly similar to that of the present outbreak. The eruption began on the scalp and gradually involved the entire surface. It was accompanied with high fever. The skin exfoliated in large sheets, together with the hair and nails. When aged 20 years the patient had another attack, and when aged 25 years a third outbreak. The present one, the fourth, began seven months ago. Red macules made their appearance, from which, according to the statement of the patient, the skin exfoliated, and healing resulted. Four months ago a swelling of the legs, which remained six weeks, was noted. Since then the patient has become weaker and weaker, and for the past four weeks has had considerable fever. During the entire seven months the skin process—of red patches and subsequent exfoliation, and healing—has continued uninterruptedly; fourteen days ago the eruption spread over the entire surface; for the past two days there has been marked scale-formation and exfoliation.

Status Præsens.—Patient is of middle size, slender, and emaciated. An examination of the internal organs gives nothing special. Morning temperature, 98.8° F. (37.1° C.); evening temperature, 100.4° F. (38° C.). The urine shows 0.1 per cent. albumin, abundant pepton, indoxyl and skatoxyl.

On the face and neck the skin is normal and of a pale-yellowish color. From here, extending downward, the entire surface is somewhat reddened, slightly thickened, and distended and lardaceous to the touch. Here and there over the surface named are irregular patches and plaques of exfoliation, giving the surface a map-like appearance. The scales are of about the size of a shilling, consisting of epidermal flakes, which have an asbestos-like appearance, but are not so hard or dried-out as to break; they are more of an elastic and flexible character. The scaliness appears about the same on both flexor and extensor aspects of the limbs, and is, for the most part, in distinct areas, although there are also to be seen smaller scaly spots. The scalp is likewise markedly scaly; at this time falling of the hair was very slight.

The mucous membrane of the cheeks and the lips is free; the tongue shows numerous clefts and furrows. On both sides of it, as well as on the dorsum, are white plaques which appear slightly elevated; it cannot be determined whether these have resulted from bullæ or are of the nature of a simple coating. The nails of the fingers and toes are much furrowed and atrophic, but none are lost.

Under slight diarrhea and evening temperature elevation up to 101.6° F. (38.7° C.), fresh outbreaks continued to appear. Vesicles and slightly oozing areas also developed. In the groins and also above the elbow joints the lymphatic glands could be readily felt, but the enlargement has an indolent and tolerably hard character. Three weeks after patient had entered the hospital death resulted from an intercurrent pericarditis and endocarditis.

Autopsy-findings.—Pericarditis serofibrinosa recens. Tuberculosis chronica et subacuta lobi superioris pulmonis utriusque. Endocarditis recens valv. mitral. et aortæ. Amyloidosis hepat. lienis renumque. Medulla ossium rubra.—Dermatitis exfoliativa.

PLATE 18.

Exanthema Bullosum Neuropathicum.

[Corresponding to the dermatitis vesiculosa neurotraumatica of Duhring, and to anomalous and recurrent herpes zoster of others.—Ed.]

L. B., aged 18 years, seamstress, was admitted May 10, 1892. The patient in earlier life had had measles; and a year before admission had begun to menstruate, at which time she was chloro-anemic. She does her work with the right hand.

Thirteen weeks previously the patient noticed the appearance of an eruption between the second and third fingers. After she had opened these blisters with a needle and touched the parts with caustic, there gradually developed over the entire back of the hand and over the fingers blebs with watery contents, spreading from the part first involved. The patient quite often experienced radiating and violent pain along the course of the radial nerve and also on the upper arm. She states that, before the outbreak of fresh blebs, she feels a burning pain in the hand. She had already used lead-water applications, prescribed by a physician.

Status Præsens.—*May 12.*—Patient is of slight figure, well nourished; the mucous membranes are pale, inner organs normal; weight, 42.25 kg.

The muscular strength of the left arm and hand is greater, there is no difference in the sensibility and reflex excitability of the nerves of the two arms.

On the back of the hand, beginning with the fingers and extending one-third-way up the forearm is to be seen a somewhat irregularly distributed bullous eruption. It is most abundant and almost confluent on the back of the hand, and after that about the epiphyses of the joints. The least affected parts are the ulna side of the hand and the fourth and fifth fingers. At this time the most recent blebs, with crystal-clear contents, were to be seen on the thumb, forefinger and middle finger. In addition to these are to be seen on these fingers pigmented spots of a reddish-brown appearance, which appear to be not wholly developed lesions, but to have been incompletely developed dried vesicles. On the first phalanx of all three fingers are single, dried-up brown efflorescences, representing desiccated blebs. The outer side of the third finger, toward the fourth, is free from lesions; but between the first and second fingers—and

especially on the radial side of the second and of the thumb—are single well-developed blebs. The palm and the flexor surfaces of the fingers, with the exception of a bleb over the metacarpophalangeal joint of the third finger, are free. On the dorsal surfaces of the fourth and fifth fingers are a few efflorescences, representing dried-up blebs.

The back of the hand and a portion of the forearm show the most efflorescences, which present three stages: spots covered with new epidermis and with brownish halo—the site of healed lesions—brown, dried-up epidermis, partly with hemorrhagic, brownish-red basis; and blebs, some with cloudy contents and flaccid wall, and others with clear contents and well distended. Between the efflorescences the skin is normal.

The circumference of the right arm in the middle portion is 19.5 cm,, that of the left 20 cm.; that of the forearms about alike. The temperature sensibility is alike on both arms. Investigation of both arms as to faradic excitability, when applied to the nerves, shows considerable lessening of the same on the right arm, and this is noted to be the fact as high up as the plexus. The investigation of the nerves with the galvanic current shows a normal condition. Tapping and pressure upon the nerves are without pain.

Blood-investigation gave the following: The number of red corpuscles, 4,062,000; the number of white corpuscles, 5000; hemoglobin, 80 per cent.; eosinophile cells, 2 per cent.; polynuclear leukocytes, 54 per cent.; lymphocytes, 34 per cent. In stained preparations the red corpuscles show good staining, and nothing abnormal in shape. The findings indicate secondary anemia. The eosinophile cells are not increased. The proportion of the lymphocytes to the white blood-cells is in favor of the former (instead of 20–24 per cent., here it is 34 per cent.).

After three days, on *May 15*, three new blebs appeared on the right middle finger, one on the second phalanx near the joint, one between the second and third phalanges, and one on the third phalanx, the latter two on the radial aspect. The patient stated she anticipated the outbreak of these new lesions by the fact that three days previously their sites were the seat of a burning feeling. Another bleb appeared on the ulnar side over the fifth metacarpal bone. The blebs on the vola of the third finger, as likewise those on the second finger, collapsed.

May 17.—The efflorescences, including the fresher ones, are drying up, and are covered with a brownish-red, uninjured epidermis. The patient was given ferrum dialysatum with tincture amara, and externally applications of Burrows' solution.

May 18.—The bleds had all dried up, and for the most part the crusts had fallen off, leaving behind brown pigmentation. Upon request the patient was discharged, practically free.

On *June 11* of same year, two weeks after discharge, the patient reappeared and stated that for the five preceding days she had tearing pains in the right extremity. Two fresh blebs, with but slight exudation, pea-sized, were seen on the hand; and in the middle of the right metacarpal bone of the second finger was a pea-sized abraded spot. All three were located in the same direction, toward the extensor side of the right forefinger. Later on, *July 9*, another distinct bleb eruption had developed.

Therapie.—Lead-water applications and zinc ointment. Recovery.

PLATE 19.

Herpes Zoster (Sacrolumbalis, Hæmorrhagicus et Gangrænosus).

S. W., aged 66 years, female, admitted Feb. 29, 1896, stated that for two months she had suffered from bronchial catarrh. For the past fourteen days she had pain in the back and thigh. A few days ago an eruption appeared on the buttock of the right side, accompanied with burning pain, and rapidly became more and more extensive.

Status Præsens.—On the right buttock several groups of herpetic efflorescences, with hemorrhagic contents and with hemorrhagic areola, are to be seen. Some groups have become gangrenous and changed into shallow ulcers with hemorrhagic base. Over the region of the sacrum are recent vesicles with serous, and partly milky, contents. Six days after admission, and the twentieth day after the beginning of pain, the lesions, began to dry up and the tenderness and pain were much less marked. Later all symptoms gradually disappeared, and full recovery ensued.

PLATE 20.

Herpes Zoster (Supraorbital and Palpebral).

L. S., aged 16 years, mechanic, came of a good, sound family and was himself always healthy.

In Mar., 1896, the patient had a similar eruption on the same region for a period of eight days; since then he has had no sickness; never had headache or other nervous symptoms. Five days ago the patient felt unwell, had a chill, and toward afternoon felt obliged to lie down. On the following day the left upper eyelid was red and swollen, and on the next morning he noticed some vesicles upon the nose and eyelid toward the inner angle. Yesterday, four days after the first symptoms presented themselves, vesicles also appeared on the eyebrow: and this morning early the two recent groups which cover the outer side of the lid. There is a feeling of distention and burning in the affected lid.

Status Præsens.—The eruption is to be seen on and around the inner side of the lid and on the nose, and consists of vesicles with reddish base and areola, and beginning to dry. The entire upper lid is swollen and edematous, inflamed, and red. On the brow is to be seen a group of greenish-yellow vesicles, tending to become confluent. In the middle of the lid and also toward the outer side are two groups of recent, yellowish-white vesicles, partly confluent. Toward the edge of the lid and upon the border are pinhead-sized scattered vesicles.

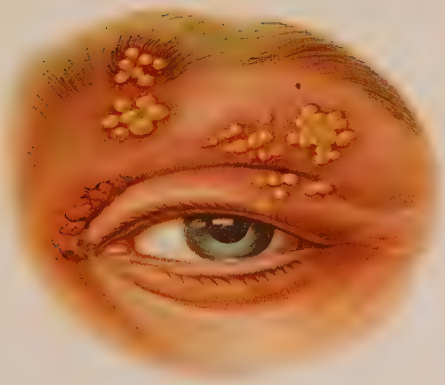

PLATE 21.

Herpes Zoster Cervicalis.

H. J., a maid, aged 19 years, came under observation Dec. 15, 1901. Had always been healthy. She stated that one week previously she was attacked, for the first time, with headache. The piercing pains in the first two days were at times much lessened, but on the third day they remained constant and were confined to the left side. The rest of the head was not involved. On the same day she noticed the outbreak of an eruption of blisters. The general condition of the patient was not disturbed, but the appetite had lessened somewhat.

When first examined, groups of vesicles, on a reddened basis, were found on the left cheek, and back of the ear; at the angle of the jaw, on the chin and neck were several similar groups. Zoster cervicalis extended beyond the line of the first branches of the trigeminal nerve (vertex-ear-chin line) toward the front.

Under applications of rice powder the blebs rapidly dried up, and the patient was dismissed, cured, on Dec. 27.

PLATES 22, 23, and 24.

Impetigo Herpetiformis.

The patient had gone through six pregnancies without mishap; she was received into the hospital—at the seventh month of pregnancy with the seventh child—on Mar. 26, 1898. A month previously she had been under treatment for a phlegmon of the right hand.

At the time of admission into the hospital she had high fever, restlessness, and showed otherwise marked systemic disturbance and the following integumentary condition:

Upon a reddened, but slightly elevated, basis were seen pinhead-sized vesicles with grayish-colored contents; these were arranged in circles, ellipses, and stripes, or bands. The central circle would dry and in the periphery similar lesions appear. Here and there these groups coalesce; others remain abortive, so that in the middle of perfectly sound cutaneous areas could be seen single isolated miliary pustules. In the further development such a group presented a reddened, crusted, or scaly area at the central part, while, in the periphery, within the surrounding halo, new pustules continued to appear. When these latter were wanting, the dried central patch presented some resemblance to a psoriasis efflorescence. The largest group was found on the abdomen. It began slightly below the ensiform cartilage, extended in a wide bandlike manner toward the back, up to the middle intercostal groove, and downward to the genitocrural furrow. This area consisted substantially of grayish-green, firmly adherent scales, in the periphery of the surrounding halo, here and there, some miliary pustules were found.

The pustular eruption became more and more sparse, the change into a scaly condition being more general. There was marked systemic involvement. On Mar. 27 the patient aborted; the fetus showed nothing abnormal.

In the further progress of the malady the fever—of an intermittent type—continued; attacks of chilliness were noted, and numerous new pustules continued to appear. The involution of these began with the formation of crusts and scales without an intermediate stadium of oozing, without papillary hypertrophy, so that in fact the entire eruption bore some resem-

blance to an atypical psoriasis. In the further course these crusts and scales were gradually cast off.

The fever resolved into less continuous, and the skin became normal, except as to the presence of a pale-brown pigmentation. It is worthy of note that during the entire course of the febrile action a marked leukocytosis could be demonstrated; further involvement of the kidneys was also shown by the presence of albumin and casts. Later, during her stay in the hospital, the patient was attacked with a severe affection of the intestinal tract, and died June 13.

Autopsy disclosed enteritis acuta diphtheritica coli totius et ilei (dysenteria acuta), nephritis chronica, anæmia, maciditas uteri.

Patient was exhibited before the Royal Medical Society on Apr. 22, 1898.

PLATE 25.

Pemphigus Vulgaris Diutinus.

R. S., aged 69 years, a teacher. The patient stated that for more than eight weeks blebs had been coming out here and there over his body, their appearance being preceded by itching. The patient's general condition is not much disturbed, but he complains of sleeplessness.

Status Præsens.—Without any tendency to particular arrangement or distribution, the whole cutaneous surface is the seat of numerous pea- to bean-sized distended blebs with wine-yellow contents. These are partly developed upon apparently normal skin, while others have developed on a erythematous basis, having been preceded by an erythematous stadium which has left a red areola and a hard basis. The blebs remain only a short time unchanged, soon the contents begin to become clouded and the bleb wall less distended; the purulent contents gravitate to the dependent part of the bleb, and finally the bleb wall breaks or is torn, and there is disclosed a sharply circumbscribed, red oozing base, the outer part being still covered here and there with fragments of the broken bleb wall. These fragmentary remains and the secretion soon dry, to form a thin crust, under which regeneration of the epidermis takes place. Where earlier blebs were, one sees red or bluish-red spots, which sometimes scale slightly, gradually become pigmented, and finally can completely disappear. Here and there, especially where the efflorescences have been rubbed or scratched, the blebs show hemorrhagic contents, and present, after their rupture, an inflammatory, bloody, deeper base; these may develop into small ulcers, which heal with scarring. The mucous membranes are free. The general condition of the patient is relatively good, only with the more extensive outbreaks are noted itching, sleeplessness, and fever.

In the continuous water bath the patient made a full recovery, and after two months' treatment left the hospital, cured.

PLATES 26 and 27.

Pemphigus Vegetans.

H. O., aged 68 years, female, was admitted Feb. 28, 1894. The patient was in the hospital four years previously for a pemphigoid eruption. The present attack began three weeks ago.

Status Præsens.—The nutrition of the patient is poor; the hands and feet slightly edematous. The entire surface is the seat of a bleb-eruption; some of the older lesions covered with crusts. Immediately surrounding the anal outlet are some papillary growths. The skin of the neck, back, axillæ, and genital region is considerably pigmented, without recognizable cause.

Course.—Up to August of the next year (1895) the patient was upon two occasions permitted to leave the hospital, inasmuch as she was free from blebs and felt much better as to general health. Since Aug., 1895, however, she has been constantly in the hospital. During this whole period it suffices to state that the entire body was the seat of recurrent outbreaks, of which the following description is a picture: The yellowish-brown pigment of the earliest period had, on the neck, upper shoulders, lower abdominal region, and axillæ, changed to a dark-brown or blackish tint. The skin of the hands and inner thighs felt leathery and was more or less rugous. In the axillæ are flat warty and papillomatous thickenings of the skin; these areas had formerly been moist, deeply furrowed, and papillomatous, and coated with a cheesy covering. In the genitocrural folds, on the labia, and surrounding the anus are red papillomatous growths, seated upon broad bases and discharging a cheesy secretion. On the dorsal surfaces of the hands are fresh pemphigus-blebs and abraded areas, the seat of recent lesions. The skin is furrowed and leathery, and the border of the blebs red and swollen. On the face and lips are smaller broken blebs. On other parts of the body may be seen small blebs, associated with troublesome itching. The patient is considerably emaciated and depressed in general health. Since the beginning of the present year the condition has measurably improved; the bleb-outbreaks have lessened both in extent and severity, and the subjective sensations are not troublesome.

Treatment.—Great care was taken as to cleanliness; the papillomatous excrescences were treated with drying-powders and lotions. Internally, in addition to tonics and nutritious food, arsenic was given about two months and "Brown-Séquard" for three-quarters of a year. At present writing nothing is being administered.

PLATES 28 and 29.

Gangræna Raynaud.

A. J., aged 51 years, servant, had been, she stated, always healthy. A year ago her present trouble began, first showing itself on the ends of the fingers of the left hand, soon after involving those of the right hand also. There were at first severe persistent pain and a marked cold feeling in the parts. The fingers became swollen, were at times distinctly bluish red, at other times quite pale; three months ago they began to suppurate. For the past month ulcers, which were likewise preceded and accompanied by severe pain, had appeared on both feet.

Status Præsens.—Patient is small, frail looking, and badly nourished. Lung examination disclosed nothing abnormal; heart sounds slightly accentuated; liver and spleen not enlarged; albumin in the urine, but no sugar. Radial blood-vessel hard on both sides; pulse isochronic. There is a hyperesthesia of the face, and of the upper, and especially of the lower, extremities. Cold and heat sensation normal; reflexes normal, and pupils react.

The thumb of the left hand is thickened, inflamed, reddened, and painful; on the flexor surface of the distal phalanx there is a dime-sized ulcer, which is sharply defined on the outer aspect, irregularly so on the inner side, and covered with a black, dry, bad-smelling crust. On the radial side of the same finger is a pea-sized, sharply circumscribed, actively suppurating ulcer. The thumbnail is clouded. The nail of the forefinger has been, through underlying suppuration, raised, is blackened and distorted; the entire nail of the middle finger has been cast off. The end phalanx of the ring finger is involved in its entire circumference, and the dorsal surface, extending up above the joint, is involved and covered with a black and offensive-smelling crust, seated upon a sharply circumscribed suppurating ulcer. Above the second phalangeal joint of this finger there is a lentil-sized purulent bleb with reddened and infiltrated border. On the extensor surface of the small finger is to be seen a dime-sized necrotic ulcer, which has penetrated into the joint. The nail of this finger is also bent. The right hand, on symmetric sites, shows the same condition as those observed on the left.

The lower extremities show swelling about the ankles and dorsal surfaces of the feet, and the skin is thinned and tense. Below the external malleolus of the right ankle is a shilling-sized ulcer with sharp border and necrotic covering; over the metatarsophalangeal joints of the second and third toes there are similar ulcers. Several scars, some white and some pigmented, mark the sites of former, healed, ulcers.

Under applications of mild salves, and enveloping the extremities with wadding the ulcers healed; the gangrenous and necrotic parts were cast off, and the patient found herself comparatively comfortable. On the advent of cold weather the patient again complained of persistent pains, and here and there small blebs developed, which broke down into ulcers. A persistent typical stadium of local asphyxia or syncope was at this time not observed. The patient died suddenly with symptoms of edema of the lungs.

Autopsy-findings.—Hypertrophia ventriculi sin. cordis; angustitas aortæ et arteriarum; mutilatio digitorum quorundam e gangr. sanata; hyperplasia lienis; nephritis chronica.

PLATE 30.

Dermatitis (Cantharides).

S. M., aged 35 years, drug-clerk, healthy, had from morning till mid-afternoon worked with cantharides, sifting it, and perspired freely during this time. Toward evening he felt burning sensations; blebs appeared, which enlarged considerably during the night.

Status Præsens.—On the forearms and on the neck are irregular, well-distended blebs with serous contents, and having reddish areola. The rest of the body is free.

PLATE 31.

Combustio.

L. E., a cook, aged 33 years, was received into the hospital June 2, 1902. With suicidal intention she had sprinkled her clothing with alcohol, and set it on fire. As a result the entire body, with the exception of the lower part of the legs, was the seat of extensive burns of the first, second, and third grades, from which she died, in the continuous water bath, after some hours.

Autopsy-findings.—Combustio cutis corporis totius, degeneratio parenchymatosa myocardii et hepatis, tumor lienis hyperplasticus, thymus persistens, nephritis subacuta.

Tab. 31.

PLATE 32.

Bromid Acne.

M. Th., aged 25 years, a peasant woman, was received on June 3, 1903. According to the patient's statement she had taken, on account of hysteria, sodium bromid for the past four weeks, taking 60 gr. daily; lately she had noticed the present eruption.

Status Præsens.—On the forehead, both cheeks, particularly, however, on both legs, are numerous red to reddish-brown hard papules, from a millet-seed to a pea in size. The lesions are for the most part in crowded groups, their inflammatory bases coalescing, so that elevated plaques have resulted, which are also beset with small pustules; in some the epidermal covering is lifted up with purulent matter into blebs. Upon discontinuance of the drug the pustules gradually dried up, and the eruption healed, leaving behind pigmented spots.

PLATE 33.

Ecthymata per Totam Cutem Dispersa.

A. K., aged 28 years, came under observation on June 4, 1903. Eight weeks before coming into the hospital the patient had noticed the appearance of intensely itchy, but slightly painful, pustules on the right leg. Gradually similar lesions appeared on other parts of the body, without any associated general disturbance.

Status Præsens.—Patient is of middle size, well-nourished. Urine normal. Over the entire body are found irregularly scattered, discrete, lentil- to shilling-sized efflorescences, with bright-red and infiltrated base, and in the center of the summit an upheaval of the epidermis, containing pus. Numerous cocci were demonstrable in these pustules. The older and larger of these lesions are dried up and covered with a bloody purulent crust, under which can be found an excoriated bleeding base. The oldest of the lesions have already cast off the crusts and only show healing, moderately infiltrated, thin-scaling spots.

PLATE 34.

Furunculosis [Ecthyma?—Ed.].

T. J., aged 36 years, hostler, was admitted Apr. 1, 1897. The skin-affection had existed eight days. The first efflorescences appeared in the region of the coccyx and then spread toward the sacral region and the lower extremities. In the past three days the patient had had several chills.

Status Præsens.—The patient is large, strongly built, and well nourished. The buttocks and the outer side of the left thigh, and to a much less extent on the remaining parts of the lower extremities, except the extensor surfaces, are seen dime- to dollar-sized red crusted lesions. The crusts are of a brownish-yellow color, somewhat heaped up, and are firmly adherent to the underlying superficial ulceration. The base is inflammatory and infiltrated, and the areola pronounced and also inflamed and infiltrated. The process is somewhat deep, having almost a furuncular nature. Cultures made from the secretion show staphylococci and streptococci.

Under antiseptic applications a cure resulted in sixteen days.

[Many of these lesions, as here depicted, correspond to the lesions usually described under the name of ecthyma. By some observers they would also be looked upon as a markedly inflammatory type of impetigo contagiosa. Boils frequently begin as impetigo, later sometimes developing into ecthyma and then becoming deep-seated and furuncular.—Ed.]

PLATE 35.

Psoriasis (Punctata et Guttata).

G. J., aged 17 years, locksmith, was admitted Mar. 23, 1886.

The patient had his first attack of more or less generalized psoriasis two years previously, which, with the exception of a few spots on the knees, had entirely disappeared after the use of salves. The present eruption was noticed fourteen days before admission, first on his arms.

Status Præsens.—The patient is strongly built, well nourished, and is apparently in good general health. On the trunk, extremities, and face are numerous psoriatic efflorescences, varying in size from a mere point to a lentil, having the characteristic scaliness. On the extensor surfaces of the knees are larger lesions, apparently of longer duration.

The painting was made two weeks after the beginning of the present outbreak. A week later the lesions were more numerous, with a tendency to form confluent patches, and covered with silvery scales. The borders of the patches were bright red.

PLATE 36.

Psoriasis (Diffusa).

H. C., aged 41 years, shoemaker's helper, admitted Aug. 22, 1896, stated that four years previously he had been treated for the same disease. For the past five months he noticed a reappearance of the eruption. He had himself made applications of petroleum, but with no result, and had then sought the hospital.

Status Præsens.—The entire surface of the patient is covered with psoriatic patches. In some places they have become confluent, forming large red infiltrated areas, covered with scales. This is more especially the case on both lower legs, on the outer sides of both thighs, in the lumbar region, and on the extensor surfaces of both forearms. On the scalp the eruption is extensive and confluent. On the trunk, on the chin, and on the forehead are scattered lesions, pinhead- to pea-sized. All patches are moderately elevated with narrow red border, and covered with fine white scales.

Treatment.—Chrysarobin salve. After ten days' use, owing to a conjunctivitis, this was temporarily discontinued. After the conjunctival inflammation was relieved treatment with the salve was again begun, and the case finally cured.

PLATES 37 and 38.

Psoriasis Nummularis [Eczema Seborrhoicum ?—Ed.].

S. J., aged 64 years, vine-grower, was admitted Feb. 5, 1896. He stated as follows: That he was always healthy; in 1868, without any apparent cause he rapidly lost his hair. Is a moderate drinker. His present disease was first noticed about a half year before admission, and first on the trunk and hands. After moderate itching some blisters appeared, which dried to crusts. For a long time he had been in the habit of removing these crusts with oil, but they always reappeared. Later the eruption appeared on scalp and face.

Status Præsens.—Patient is strongly built, but not well nourished. The scalp is covered with brownish-white crusts, which when loosened can be made to come off as an ill-defined cast. The hairless underlying skin is thin and hyperemic.

On the face, about the eyelids, are eczematous, weeping patches. Chronic conjunctival catarrh, moderate ectropium of the lower lids, and increased tear-flow are noticeable. On the breast and upper belly-region and on the extremities the eruption is extensive, consisting of scattered half-dollar-sized, palm-sized, and larger areas. The scattered spots show in the central portion considerable scaliness, more or less heaped up, and have a hyperemic border. Vesicular formation cannot be seen on any part.

The paintings show two of the more recent patches on the breast (Plate 37), and on the scalp (Plate 38) after partly freeing it from crusts.

[By many these plates and description would be considered to belong to cases partaking of the nature of both eczema and psoriasis (psoriatic eczema), and by others as eczema seborrhoicum—Ed.]

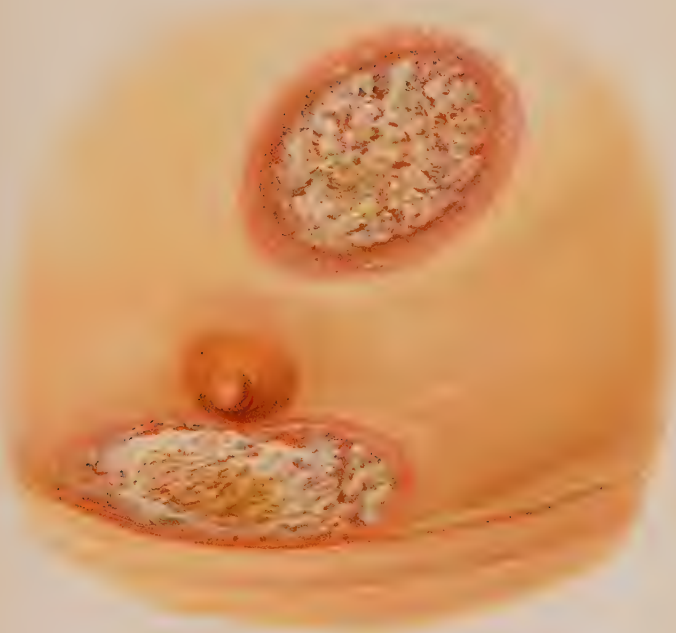

PLATE 39.

Psoriasis.

F. V., aged 18 years, received in hospital on June 11, 1903.

The patient stated that about six months previously he had first noticed upon the scalp scales and crusts. The eruption subsequently gradually extended to the forehead and face; and six weeks ago he observed similar lesions upon the elbows and upon the right lower leg.

Status Præsens.—The patient is badly nourished and anemic. The entire scalp is the seat of lentil- to shilling-sized scaly patches, for the most part rounded, and in places coalescing; in other places they are well and distinctly defined from each other. They are made up of thick, grayish-yellow, dry friable, crusts and scales which cover a moderately infiltrated reddened base. In attempting to remove the scales, which could be readily done by lifting them up from their edges inward, the underlying skin is seen to be reddened, excoriated, and bleeds easily. The hair has not to any extent been affected and remains firmly seated in the skin.

Especially in the neighborhood of the vertex and the anterior and anterolateral portions of the scalp the patches tend to become confluent. On the forehead, on both cheeks, and just above the eyebrows, are found small and moderate-sized scaly patches of a reddish-brown color, the outer portion of the larger patches being infiltrated and well-defined against the healthy skin, and the central portion showing a marked clearing tendency. These are covered with grayish-white scales. Under the scales of these patches the skin is found reddened, not excoriated, and with no tendency to easily provoked bleeding.

On the extensor surface of the left elbow joint and of the right lower leg similar patches are observed.

After the continued administration of arsenic and local treatment the patient was finally discharged with the skin free from the eruption.

[While this case well illustrates psoriasis as seen on the scalp, where it is frequently observed, usually as a part of a more or less generally distributed eruption, it also shows a rather uncommon occurrence of well-marked patches upon the lower part of the forehead and on the face lower down. Generally speaking, the face is not affected to any conspicuous extent in psoriasis except in very extensive cases.—Ed.]

PLATES 40 and 41.

Psoriasis (Circinate, Annular, Gyrate).

H. F., aged 21 years, laborer, admitted July 6, 1896, stated that for a period of eight years scaly papules had been observed. Two years ago he was treated elsewhere with tartincture and drops (arsenic ?), and later, in winter, for three months with pyrogallol, chrysarobin, and pills (arsenic ?), but without result.

Status Præsens.—Patient is medium built, with fair bone-structure and muscular development. Internal organs normal. On the buttocks and on the upper extremities are scaly papules, pinhead to lentil in size and with a narrow red border; likewise larger efflorescences, rounded and with infiltrated bases. On the abdomen and upper third of the lower extremities are patches consisting of an infiltrated, red, scaleless center, surrounded by an annular border covered with glistening white scales.

Course and Treatment.—Thyroidin was prescribed in capsules, each containing 0.50 gm. (7½ grains), beginning with one daily, and increasing one every three days. The pulse was not materially affected, and the body-weight varied but several pounds (between 52 and 57 kg.). The skin-condition gradually improved, so that on Aug. 19 the following status was noted:

On the arms the psoriasis-spots are pale; infiltration and scale-formation have disappeared. The circinate and gyrate patches on the breast, abdomen, and back exhibit less redness, being now pale red or brownish, with retrogressive infiltration and scale-formation. Pulse 100, and regular.

Early Sept.—On buttocks are still to be seen some slightly elevated areas, and some patches which are still somewhat red.

Sept. 19.—The patient was discharged cured.

Tab. 41.

PLATE 42.

Psoriasis (Gyrate, Annular).

C. F., aged 21 years, laborer, admitted Mar. 18, 1897, stated that he had psoriasis for the first time in 1893, at which period the patches appeared on the extensor surfaces of the elbows and knees. Under treatment with pyrogallol and chrysarobin salves he was much benefited. A year ago he noticed a change in the diseased areas—spontaneous disappearance of the central portions and an extension and confluence of the borders.

Status Præsens.—Patient is of graceful build; moderately nourished. Internal organs normal. On the legs, arms, and trunk, in addition to scattered pinhead-, pea-, and coin-sized lesions, are to be seen large serpentine or irregularly circinate plaques, the peripheral portions being made up of hyperemic, elevated, scaly borders, sharply defined, and enclosing areas of brownish pigmented skin. Here and there within these boundaries are to be observed lentil- to pea-sized scaly spots. The scalp is reddened and covered with thick scales. Body-weight (Mar. 17), 54.5 kg.

Treatment.—Iodothyrin.

Apr. 6.—Weight, 52.1 kg.

Apr. 16.—Patient was, upon request, discharged, some improvement having taken place.

PLATES 43, 44, and 45.

Psoriasis. Cornua Cutanea (with Degenerative (from Uric-Acid Diathesis) Changes in Right Hand and Left Foot).

H. J., aged 58 years, an innkeeper, was admitted May 5, 1897. The patient stated that his father had been a sufferer from gout, and that he himself, when in his thirty-third year, was ill. His illness began with symptoms of general weakness, which increased, and was accompanied with swelling of the joints of the feet. This condition lasted some months. In 1883, when about forty-four, he again became sick, and was obliged to keep in bed; there were swelling and pain in all joints, especially those of the lower extremities, and in the loins. Four years later he had a similar attack. In 1891, there developed a tumor or swelling on the head, which was removed by operation. In 1889, scaly papules appeared on the right shoulder, since which time similar lesions had made their appearance on the trunk and extremities. The hands were free up to three months before admission, when the eruption appeared on these parts; there was pain in the right hand. Lately the patient had lost considerable flesh. Appetite was good. The bowels were sluggish, sometimes five days elapsing between the stools.

Examination of the urine passed in twenty-four hours showed a marked increase in the uric acid and considerable uric-acid sediment. Urine was much less actively solvent for the uric acid than normally.

Status Præsens.—Patient is large, pale, very much emaciated, and of delicate bony structure. Pulse 63; rounded and well filled. Temperature normal. Arteries hard. Lungs emphysematous, and disclosing many râles and much whistling. Heart-sounds apparently normal. Liver and spleen could not be made out.

The skin in general is dry and easily lifted in folds, the subcutaneous fat having disappeared. On both forearms the skin is parchment-like and in wrinkles and folds; on the thighs the folds are thicker and more marked. Over the general surface, with the exception of the face, neck, breast, and the back down to the sacrum, are to be seen innumerable lentil- to palm-sized scaly patches (psoriasis guttata et nummularis). In certain places, as on the buttocks and lower legs, the eruption has

Tab. 44.

Tab. 45.

become confluent and formed festoons. Over the olecranon, left arm, is a chestnut-sized, rounded, closely-adherent, heaped-up, shell-like scale, surrounded by a red infiltrated border. Similar lesions are to be seen, with smaller crust-formation, heaped up and rounded in form, on the forearms, hands, and lower extremities. Upon lifting the shell-like accumulation from these lesions, the papillæ are disclosed, the surface bleeding easily. On the extensor surface of the right elbow the eruption is of the usual character. On the extensor surfaces of both knees are yellowish crusts seated upon grater-like, raw-looking skin.

On the dorsal aspect of the second joints of the fingers of the left hand are also heaped-up, oyster-shell-like scaly crust-formations; in consequence of which the fingers are held in a bent position and cannot be extended—the stiffness of the joints of this part is, however, partly responsible. The nails of these fingers are thickened, of dirty gray color, fissured lengthwise, and lifted up from the matrix by a horny accumulation beneath. The right hand (Plate 44) and fingers, especially on the dorsal aspect, are considerably swollen, reddened, and infiltrated. The palms are the seat of yellowish, tough, hard, horny scales. The nails of the right hand jut out, talon-like, over the finger-ends, and rest upon a horny, hypertrophic nail-bed, although less so than with the nails of the other hand.

The large joints of both big toes are pushed forward, and bent, valgus-like, and covered with horny masses. Similar horny accumulations are to be observed on the soles. The toe-nails are irregular; in part wanting, in part showing horny masses.

Course and Treatment.—In the further course of the disease the patient complained of pains in the hand-joints and of a troublesome cough. Treatment consisted of Carlsbad cure, milk-diet, and baths. Under this treatment most of the crusts and scales had in four weeks' time fallen off.

June 14.—The horn-like psoriatic accumulations on the elbows, lower legs, and around the ankle have been cast off; the borders are still red and slightly scaly. The joint-affection has considerably retrogressed; the nails have hardened, are thickened, bent, cracked, and exfoliating. The patient's general appearance is materially improved, so that in this improved condition, at his own request, after a period of six weeks' treatment, he was discharged.

PLATE 46.

Lichen Planus.

U. S., aged 41 years, female.

The eruption is somewhat widespread. The face is free. On the upper extremities the flexor surfaces are more especially involved, the lesions on the extensor surface being scanty and scattered. On the lower extremities the anterior surface of the inner side of the thighs and the flexor surface of the lower leg are most affected. On the back and breast and the inner side of the thighs the individual lesions making up the patches and areas are less recognizable, owing to their being confluent, the normal skin between appearing as irregular, narrow spaces. On these parts the diseased areas are of an even copper-red with a brownish tone, covered here and there with small adherent white scales. As the sound skin is approached the individual character of the lesions making up the confluent areas is readily recognized. Such lesions are red, follicular, millet-seed-sized, somewhat firm papules, becoming paler upon pressure. On the top of each is a minute scale of epidermal exfoliation. In some places the patches are somewhat masked by the effects of scratching and covered with hemorrhagic crusts, and the eruption rendered somewhat dull and less shining in character. The mouth is entirely free.

Treatment consisted in the administration of Asiatic pills, and externally salicylic acid and resorcin salves.

PLATES 47 and 48.

Eczema Artificiale Vesiculosum [Dermatitis—Ed.].

Ch. K., admitted Jan. 1, 1896. The patient was, when admitted, the subject of scabies. On the 16th and 17th he rubbed in naphthol-soft-soap. On the 19th he fell sick with fever: temperature, 38.2° C.; evening, 39.1°, C. The skin became eczematous, and of chiefly vesicular character. On the 29th the morning temperature was 38° C., and the evening 39° C. The vesicular lesions of the eczema persisted.

The urine-examination disclosed a large quantity of albumin. On the 21st the temperature fell to 37.1° C. and the vesicles had for the most part dried. On the outer aspects of the thighs, where the eruption is less pronounced, are irregularly-scattered papules, which have partly dried into thin scales or crusts, and partly show a cracked epidermic covering. The anterior aspect of the leg is covered with yellow vesicles, with light-red areola.

The size of the vesicles varied from that of a pinhead to a lentil. On some places they have become confluent and form irregular clusters, in some of the lesions and groups the epidermal covering being lifted up by the abundant pus. On the inner thighs the eruption has dried into yellowish crusts of shining aspect and is irregularly divided into areas with whitish lines (cracks).

Jan. 22.—All the pustules have dried up and the inflammatory symptoms disappeared. Patient feels much better and is more comfortable.

The painting was made from the middle portion of the thigh, from both the inner anterior and external aspects. The dermatitis evidently resulted from the naphthol. This being absorbed, irritated the kidneys, so that in the beginning a large quantity of albumin and naphthol could be demonstrated.

PLATE 49.

Eczema Artificiale Acutum [Dermatitis—Ed.].

Sch. J., aged 47 years, worker in the arsenal, was admitted Aug. 6, 1896. Patient was burnt on Aug. 5 by a hot piece of iron falling on him, producing burns of the neck, hands, and thorax. In the beginning he was bandaged with iodoform-gauze, and then treated with lime-water and oil.

Status Præsens.—On the neck and right forearm down to the wrist are burns of the first and second degrees. On the left side of the chest is a diffused redness. Temperature and pulse normal. No constitutional symptoms. Boric-acid salve was used. For some inexplicable reason, at the suggestion of a hospital-helper, he rubbed some naphthol salve on the mucous membrane of the lips, and immediately afterward an erythema spread over the trunk. At the same time the whole face became markedly edematous and swollen, and an eczema-like eruption developed over the entire surface, especially on the thighs, as numerous pustules. The patient had at this time attacks of dyspnea. Morning temperature, 38.5° C.

Aug. 15.—The eyes are about closed by the swelling of the lids, admitting of only slight opening on effort. The mouth stands out like a proboscis and the lips are markedly swollen. On the chin and both cheeks, on the upper lip and in the nasal outlets are honey-yellow crusts; the same on the neck, the right upper extremities, and the upper right portion of the thorax, the inner surface of both thighs, and in less degree on the left upper extremity. Two days later the swelling of the face had markedly subsided; the eyes could be readily opened. Temperature was normal. General condition good.

Aug. 25.—The swelling and redness have completely disappeared, and there remain but a few spots that are still slightly reddish.

[The author evidently believes the naphthol responsible for the outbreak, but it is possible that iodoform may have been the etiological factor.—Ed.]

PLATES 50 and 51.

Eczema Pustulosum Artificiale [Dermatitis—Ed.].

B. Ph. was admitted for a markedly inflammatory eruption about the legs, which he stated had followed the use of a salve made up of three parts of diachylon ointment and two parts of vaselin. He had applied this to his legs for the relief of an alleged eruption which had been itchy, and had rubbed it in repeatedly with great vigor. After five days' use of this ointment the present eruption made its appearance. Three days later he was admitted to the hospital.

Status Præsens.—The extensor surfaces of both legs to the lower third, also the posterior surface of the right thigh near the knee, are the seat of numerous irregularly-grouped large pustules. Out of the center of each pustule emerge one or more hairs. The skin immediately surrounding the discrete lesions is reddened; where these are in groups this redness is confluent. The color is bright red, and may be made to disappear momentarily by pressure. There is no pronounced infiltration. The oldest of the pustules and purulent blebs show already hemorrhagic contents. Some have been broken and have given place to reddish crusting. The rest of the body is entirely free from efflorescences. Here and there are scratch-marks, especially on the flexor surfaces and at the axillæ.

The patient remained under observation for two weeks, during which period several boils developed; at the end of this time all the pustules had dried up, and from most the crusts had already fallen off; the boils had also practically run their course.

[The case would be classified with us as a follicular pustular dermatitis, which is occasionally noted to follow the vigorous rubbing-in of ointment (especially if not very fresh) on hairy parts.—Ed.]

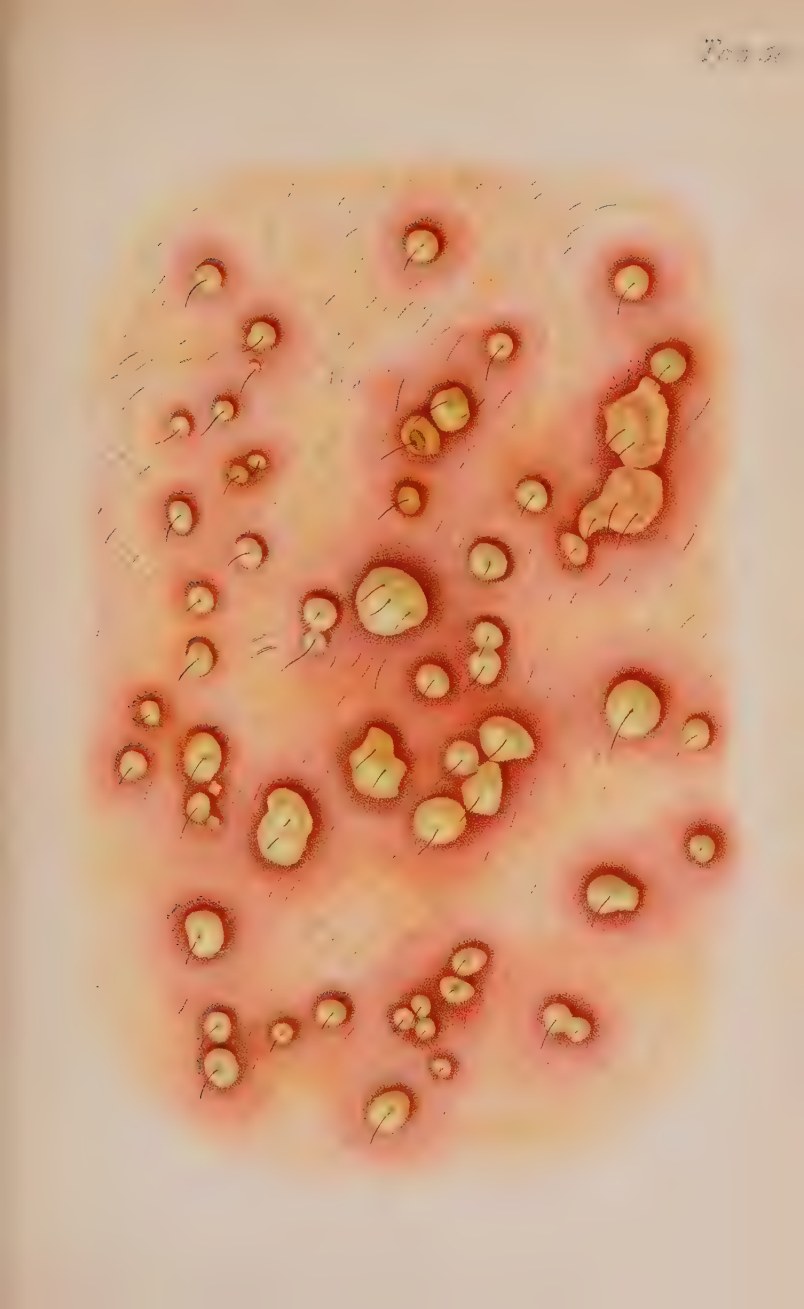

Tab. 51.

PLATE 52.

Dermatitis (Dermatitis Medicamentosa? Erythema Multiforme Bullosum?).

W. J., coachman, aged 35 years, was admitted July 4, 1895.

The patient had noticed, four days before, the appearance of papules on the back of both hands, and later similar efflorescences appeared on the hips, and finally on the thorax and nape of the neck. He was not able to say what the cause of the eruption was.

Status Præsens.—The patient is well- and strongly built, well-nourished, temperature normal. There is no troublesome itching, but there is a feeling of tension in the affected parts. On the extensor surface of both forearms are elevated, lentil-sized reddish papules, paling upon pressure. Toward the hand and on the back of the hand and fingers are similar lesions which have undergone a change into vesicles with serous contents becoming purulent. Some of the lesions have become confluent, forming larger blebs, some of which had broken, with the epidermal covering loose and collapsed. On the trunk, on both knees, and on the dorsal surface of both feet are numerous hyperemic spots and papules, some partly developed into vesicles, and others into pustules. The next day showed a marked increase in the bleb formation. Two days later the most of the blebs and pustules had become partly flaccid and some had dried to dirty brown-yellow crusts. Where the crusts have fallen off, the epidermoidal stratum is skinning over. After a treatment of eight days the efflorescences had for the most part healed—only on scattered places were there still adherent crusts. Upon request, the patient was discharged.

[The author has labeled this plate, in the German edition, "Eczema Bullosum Manus." The Germans, contrary to the custom of the Americans and English, include most cases of dermatitis under the head of eczema. In some respects the case as described is anomalous, but it might from our standpoint represent clinically either an idiopathic toxic, or medicinal eruption of the erythema multiforme bullosum type.—Ed.]

PLATE 53.

Eczema Marginatum (Tinea Trichophytina Cruris).

B. F., aged 15 years, schoolboy, stated that the eruption had first made its appearance several years before, primarily on the anterior surface of the right thigh, and later on the left, in the pubic region and about the genitalia. There had been slight itching.

Status Præsens.—The skin of the middle surface of both thighs, to the inguinal furrow and up to the pubic region, is bright red and hard to the touch. Toward the normal skin the affected area is bounded by a reddish-brown, slightly-scaly, irregular border. The border is elevated and made up of a continuous line of confluent papules, pinhead to lentil in size; the middle of the area is, for the most part, grayish-brown pigmented and slightly rugous. Beyond the main area of disease are a number of characteristic ring-shaped patches. On scrotum and penis are similar efflorescences, but much more recent and ring-shaped. The disease exists in the axillary regions, also, as typical, sharply-defined, scaly, confluent areas.

Treatment.—Lysol lotion (5 per cent.) and washings with soap, naphthol-soft-soap, and applications of Lassar's salve sufficed to cure the patient in thirty-one days.

[It is not now generally believed that all cases similar or closely similar to that here described are due to the ringworm-fungus, but that some may be classed as a variety of eczema seborrhoicum; the large majority, however, undoubtedly belong in the ringworm-group, in which the author has placed this case.—Ed.]

PLATES 54 and 55.

Eczema Madidans et Crustosum (Mycoticum ?).

J. S., aged 28 years, miller, came under observation Oct. 20, 1896. The disease had existed since June, without known cause.

Status Præsens.—On the left lower leg is a palm-sized, irregularly-bounded area, covered with dry yellowish crusts. Upon removal of the crusts the oozing corium is brought to view. In the immediate neighborhood of this patch are a few lentil- to dime-sized pustules. On the left upper extremity, on both the arm and forearm, are similar areas, partly oozing and partly crusted, of the size of a thumb-nail to a silver quarter.

Upon the application of diachylon ointment, and later the application of Lassar's paste, a cure resulted.

Tab. 55.

PLATE 56.

Prurigo.

B. K., aged 13 years, school-girl, admitted Aug. 26, 1897, stated that the skin-affection had existed since earliest childhood.

Status Præsens.—The skin of the extensor surfaces of the extremities, especially the lower in the knee-region, is thickened, dry, and rough, the folds exaggerated and of a brownish color. There are numerous embedded papules, many covered with blood-crusts; between these are reddish and brownish pigmented spots, the sites of former lesions.

Under treatment with macerating baths and the application of salves the condition was somewhat improved, and the patient left the hospital after twenty-six days' treatment.

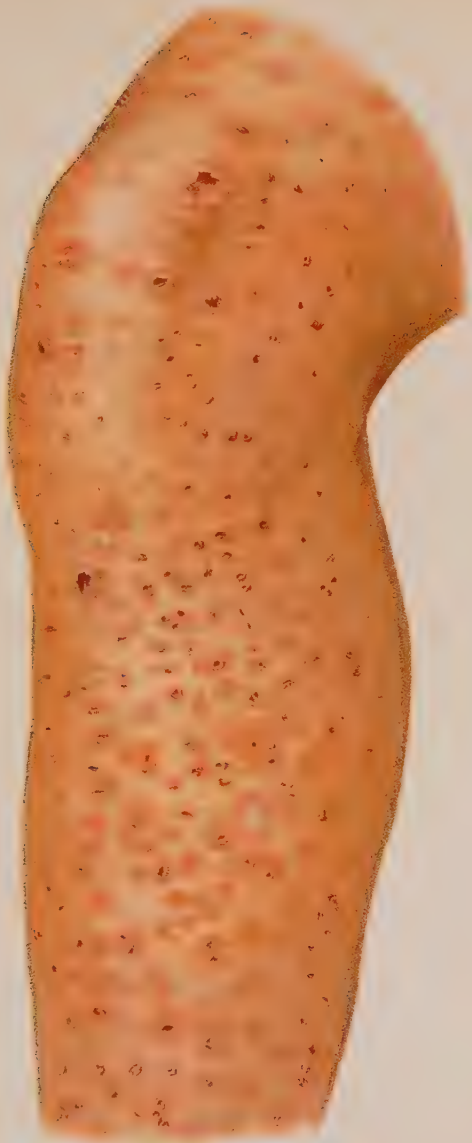

PLATE 57.

Lichen Pilaris (Keratosis Pilaris).

J. H., aged 18 years, female, stated that she has had a rough, hard skin for some years. Recently she observed the appearance of numberless minute brownish points.

Status Præsens.—Patient is strongly built and well nourished. The entire skin shows want of care. The extensor surfaces and the back are the seat of numerous, irregularly-scattered, pinhead-sized, brownish-colored papules, having their seat at the hair-follicles. The skin feels rough and dry, more noticeable on the extensor surfaces of the extremities. There was no itching, nor any symptom of a subjective character.

[In most cases of keratosis pilaris, as observed in this country, the manifestation is most marked on the thighs, especially the anterior and outer aspects; in fact, it is seldom that parts other than the thighs and corresponding surfaces of the arms and forearms are perceptibly involved.—ED.]

PLATE 58.

Ichthyosis.

A. K., aged 27 years, female, came under observation Mar. 29, 1897.

History.—The roughness and cracked condition of the skin had existed since infancy. Her only brother was also the subject of the disease.

Status Præsens.—The patient is medium-sized, and moderately nourished, but pale. The skin of the entire surface, especially the abdomen, back, and lumbar region, is rough and covered with epidermic lamellæ and plates, the cracks and fissures dividing the plates and scales disclosing the reddish rete.

[As a rule, there is less of the red aspect in ichthyosis-cases than is here pictured, and in most instances it is entirely lacking. Occasionally, however, especially when an eczema is superadded, as sometimes happens, the hyperemic element is conspicuous.—Ed.]

PLATE 59.

Ichthyosis Serpentina.

A. S., student, aged 18 years, was admitted Apr. 29, 1903. The patient had been the subject since early childhood of a rough, dry skin; otherwise he was always healthy.

Status Præsens.—Subject is small and frail, and in development somewhat backward. The surfaces of the extremities, as well as that of the abdomen and back, appeared grayish-green and dirty, as if unwashed; the epidermis is changed into horny, dull-white, greenish, brownish, and blackish masses, and especially over the knees and elbows, is heaped up in thick layers. The lines and furrows are much deeper than in normal skin. The skin of the face and head also participate in the process. The epidermal layer of the face appears dry, wrinkled, and furrowed, slightly scaly, and not very supple, so that there is difficulty in closing the eyelids, and slight ectropion is also present. The scalp is covered with normal hair, but shows slight branny desquamation. Palms, soles, and nails are normal.

After **treatment** with baths, sapo viridis and salves the patient, on May 20, was discharged, considerably improved.

PLATE 60.

Ichthyosis et Atrophia Universalis.

E. K., aged 64 years, house janitor, was brought into the hospital moribund.

Autopsy-findings. — Tuberculosis chron. pulmon. cum phthisi lob. sup. utriusque et lob. inf. dextri. Residua pleurit. obsol. bilat. Degeneratio parenchymatosa myocardii, hepatis renumque. Hernia inguin. lib. dextra et accreta sin.—Ichthyosis.

The annexed picture shows substantially an atrophy, a dry, scaly, and furrowed and wrinkled condition of the skin, the surface of which is covered with lammellar, thin, dull-white scales.

PLATE 61.

Hyperkeratosis Palmaris (Callositas).

L. K., aged 36 years, day-laborer, was admitted Nov. 20, 1896. Patient was a digger, and believed his occupation responsible for his complaint; he had at an earlier period had the ordinary callous areas in the hand. The present condition, it was stated, had lasted two weeks. The patient had long suffered from foot- and hand-sweating.

Status Præsens.—On the palms and flexor surface of the fingers of both hands, but more especially the right, the skin is much thickened, the epidermic accumulation consisting of many layers. The greatest thickness is to be observed on the thumb, the ends of the first, second, and third fingers, and on those places against which the handle of his shovel had pressed most. The joints of the parts showed tolerably deep cracks and fissures. The patient held the fingers of the right hand in a flexed position, and experienced pain in attempts to straighten them out. The nails were likewise much thickened, and between the matrix and nail was a mass of hardened epidermic accumulation. Similar conditions, but in much less degree, were noticeable on the soles of the feet.

Treatment.—Hand-baths, soft soap, and diachylon salve. Patient was discharged cured at the end of seven weeks.

PLATES 62 and 63.

Acanthosis Nigricans.

A. N., aged 58 years, a nurse maid, was admitted in the hospital, Mar. 4, 1898. According to the patient, the affection began a year ago with itching in the axillæ and poplitea. The emaciation present began about the same time. Since some months the weakness had increased and the patient had hemorrhages from the genitalia. The skin had a tense feeling as if it were too short.

Status Præsens.—The patient is large, of graceful build, and markedly emaciated. The skin of the neck is thickened and partly covered with hard crusts and partly with papillomatous growths. The same exists on the nape of the neck—only the crust formation and the thickening are more marked and the color a dark gray. On the trunk the skin furrows are accentuated, and the follicles are beset with horny, fine branny, cones; the crust formation, papillary formations, and pigmentation are less than on the neck, but, on the contrary, the skin of the abdomen is diffusely thickened and infiltrated and of an intense brown color and covered with horny crusts. These changes are most marked in the region from the pubes up to the navel, extending transversely to the spinæ anteriores, and downward beyond the pubic region, over the upper third of the thighs. The skin is everywhere thickened, like a coat of mail; is slate-gray in color, shows papillomatous vegetations, and is leathery to the touch. On the borders of the described regions linear excoriations are present. On the back, the disease is less marked, the vegetations are sparser, the pigmentation less pronounced in depth. Toward the lumbar and sacral regions the symptoms become again more decided, besides, more markedly covered with the horny formations and crusts.

The skin of the upper extremities shows an inflammatory redness, is grater-like to the touch, and, especially on the extensor surface of the elbow joints, is covered with dried blood-crusts and papillary excrescences. In the axillæ the same conditions as those in the pubic region are observed. The papillomatous formations are arranged in the direction of the normal furrows of the skin. All the axilla hairs have fallen out.

At the corners of the mouth are fissures and papillary hypertrophy. On the mucous membrane of the cheeks are pinhead- to lentil-sized vegetations; both the palate arches are diffusely reddened and sparsely covered with papular growths.

The internal organs of the thorax and abdomen are normal. There is carcinoma of the uterus; and tolerably hard and enlarged glands in both groins, tender upon pressure. Under increasing evening temperature elevation and increasing weakness the patient died on May 15, 1898.

Autopsy-findings.—Carcinoma medullare uteri exulceratum; carcinomata secundaria gland. lymphaticarum retroperit. et inguin. Strumitis purulenta—Acanthosis nigricans.

This case was published by Dr. Grosz, in the *Wiener klin. Wochenschrift*, 1902, No. 5.

PLATE 64.

Alopecia Areata (Alopecia Totalis Neurotica).

N. N., aged 22 years, female, unmarried, was admitted Oct. 13, 1896.

History.—Patient was of a highly-nervous, excitable family. No one had, however, previously suffered from any hair-loss. As a child she had varicella, and later, in her fifth year, diphtheria. Since that time she had remained anemic and weakly, and seemed unable to regain her former condition of health. As a young girl she had light-blond, very luxuriant, long hair. In early childhood she had suffered from a seborrheic condition of the scalp, but this was not accompanied by any hair-loss. From her seventh year she had suffered much from periodical one-sided headache, which, for the most part, was worst toward the occiput and neck. She began to menstruate when eleven years old, at its first onset being under great nervous perturbation; since then she had menstruated, without any special difficulty, regularly every three weeks. Some months after the establishment of this function she was subject to severe migraine, since which time she had noticed that her hair was becoming somewhat lighter in color, hard, brittle, and split at the ends, appearing as if without life. After persistent headache and recurrent nose-bleed the patient was brought in an unconscious condition to the nervous clinic. At that time she is said to have been delirious, boisterous, confused in her talk, and to have had convulsions. In one night she lost all the hair of the scalp, axillæ, mons veneris, eyebrows, and eyelashes, and later the downy hairs as well. When the patient recovered consciousness and left the hospital, three weeks after admission, she was completely bald, and remained so for ten years, up to the end of 1894. The nervous symptoms, it was stated, disappeared at this time. She noticed that the scalp-skin seemed firmly attached to the underlying tissue.

In the next six months, up to the spring of 1895, there appeared in places, first in the occipital region, then on the vertex, and finally on the parietal regions, a scanty supply of hair. This grew in length to the shoulders, although it remained sparse in quantity. With return of the severe migraine and nervous excitability the hair again fell out as before in two to three weeks. In another interval of freedom from nervous symptoms, the past five months, the hair now present had grown; the past seven or eight weeks a downy growth had also shown itself in the axillæ and the genital region.

Status Præsens.—By general examination nothing is found except a blennorrhagia of the vagina and uterus. The sensibility, pressure-, pain-, and temperature-sensations are normal, except a slight disturbance in the region of the frontal branch

Tab. 64.



of the facial nerve. The skin-, muscle-, and tendon-reflexes are present. Urine-examination gives a marked increase in phosphates. The nails are milky and show lines running lengthwise, and nail-ends tending to be fragile; they are white-dotted here and there. The skin of the scalp is pale, smooth, shining, and movable upon the underlying part, although not readily lifted in folds. The hairs are thin and atrophic, the longest being six to eight inches, and the lanugo-hair one or two lines long. Some parts, well defined and tolerably symmetric, are almost completely bald, and these, as well as those now covered with hair, agree in their arrangement with the distribution of the skin-nerves (ramus prim. trigemini, II. and III. nerv. cervicalis). A few hairs are on the region of the eyebrows; the lashes are almost completely wanting. The entire skin-covering, especially of the extremities, is dry, in spite of the fact that the patient for a number of weeks has had considerable sweating with the attacks of headache.

Noteworthy is the coincidence of the rapid hair-fall with the psychosis; the occurrence of nervous symptoms, as migraine, congestions, nose-bleed, with the oscillation in growth and falling out of the hair; the symmetry of both the hairy and the non-hairy areas, the distribution corresponding to the skin-nerves; the trophoneurotic disturbances of the nails; and also the hereditary nervous tendencies. The entire course of the affection spoke for the nervous origin of the hair-loss, and the case is to be placed in the class of alopecia totalis præmatura neurotica.

PLATE 65.

Alopecia Areata; Canities.

G. P., aged 17 years, salesman, stated that in Feb., 1895, he suffered from alopecia, which by spring was entirely cured.

The present affection appeared in Jan., 1896; the hair changed to a white color in two places in the occipital region and then began gradually to fall out. On the borders of the circular areas the hairs are easily pulled out.

Tab. 65.



PLATE 66.

Leucoderma (Vitiligo).

Z. D., aged 21 years, washerwoman, of dark complexion and dark hair.

Status Præsens.—The skin of the inner sides of the thighs, the groins, the labia, and perineum is wanting in pigment-matter, being of a dead-white color; there is increased pigmentation in the surrounding skin. The hair on the labia and pubic region is, for the most part, also white. With the exception of the whitening of the skin and hair there is nothing abnormal.

PLATE 67.

Nævus Pigmentosus Unilateralis.

P. C., aged 22 years, male, had shown since infancy pigment-marks; they had not caused any annoyance.

Status Præsens.—The skin over the buttock, from the anal furrow toward the right and downward on the thigh, irregularly bounded, is of a yellowish-brown color; otherwise of normal structure and sensation. Further down, beginning at the lowest part of the thigh and extending to the posterior and inner surface of the lower leg down to the foot was a similar blemish.

PLATE 68.

Hyperchromatosis Arsenicalis.

L. F., aged 24 years, male, stated that in July, 1895, for four weeks, and from late August into October, for six weeks, he had been in the hospital for the treatment of a scaly skin-eruption. Both times treatment was begun with the administration of five drops of Fowler's solution daily, and reached in the first course of treatment twenty drops and in the second period twenty-five drops. The scaliness had gradually disappeared and given place to extensive pigmentation.

Status Præsens.—The hairs on the patient are black and the skin yellowish-brown. On the extensor aspects of the forearms, elbows, and knee-regions are numerous scattered psoriasis-efflorescences, partly covered with scales. The skin of the entire body, with the exception of the face, neck, hands, and feet, is the seat of sepia-colored, reddish-brown spots and areas. The most are discrete, pea- to half-dollar-sized, although there were many confluent areas of larger size and irregular shape, melanotic in character. In most of the discrete spots the central part is less dark, and the borders gradually merge into the surrounding normal-colored skin. Neither scaliness nor swelling of the skin is noticed; the melanotic spots and areas feel normal to the touch and show the normal lines. The patient had during his two arsenical courses 340 and 570 drops respectively, or, in all, 900 drops.

PLATE 69.

Achromatosis (following Psoriasis treated with Iodothyrin).

A. S., cook, aged 42 years.

Patient had psoriasis, and was treated with iodothyrin. She was given 8 grains in capsule, and every three days it was increased 8 grains. After eight weeks of treatment the psoriasis efflorescences had flattened and healed, the remaining skin being pigmented a brownish color, so that location of the psoriasis patches could be readily seen by their white color, in striking contrast to the pigmented surroundings.

PLATE 70.

Nævus Verrucosus.

M. H., aged 27 years, female.

Status Præsens.—The patient had between the shoulders an elongated, oval, brown-pigmented patch. The periphery is of a light-brown color and slightly elevated; the center is dark brown, with smooth, rounded, wart-like projections which feel somewhat elastic. No pain or tenderness.

PLATE 71.

Elephantiasis Cruris.—Lupus Vulgaris.

J. A., a blacksmith's helper, aged 48 years, was admitted July 12, 1899. Twenty-five years before the patient was thrown from a horse and suffered a contusion of the soft parts of the right lower leg. After several months, fistulæ, so he stated, developed, which continued to discharge pus for a long time, and which, he believed, in the course of years, led to the present thickening and growth.

About eighteen years ago the affection on the left cheek and auricle began with the appearance of nodules and ulcerations. At the same time the patient noticed small papules on the lower border of the right lower leg. He was, some time later, in 1896, treated in the General Hospital, in the Clinic Hebra, with, as he alleges, the diagnosis of lupus vulgaris.

In November, 1898, the patient received, at his work, a blow with a heavy pair of tongs, following which he had pains in the loins. Later he was again in the clinic on account of a swelling of the entire lower leg. The crusts flattened and lessened under treatment, the livid color and swelling of the leg remaining. In later years the papillomatous formations of the right foot and ankle gradually developed, the circumference and the thickening materially increased. Alcoholism and syphilis were both excluded in the consideration of the case. On the lower edge of the lower leg, from above the ankle extending down on to the upper third of the dorsum of the foot, are seen, encircling the part, hypertrophic warty excrescences, varying in size from a pea to a hazelnut; livid in color and foul-smelling.

The patient was, upon request, after some of the swelling had disappeared, discharged, on July 25.

PLATES 72 and 73.

Elephantiasis.

K. G., a farmer, aged 25 years.

Patient comes from a healthy family, and up to his fifteenth year was always in good health, when he was attacked with apparently left-sided pleurisy, in the course of which swelling of the feet was noticed. Since then he has repeatedly suffered with febrile attacks, with pain in the left side of the breast, which were always accompanied with marked swelling of the lower extremities. For the past six years the swelling has been continuous, and, with slight variations, the parts are steadily increasing in size. It would seem, according to the patient's statement, that during the past several years the lower extremities had been frequently the seat of erysipelas, during which there was always febrile action. In spite of the enormous deformity of his leg, the patient had, up to a short time ago, been able to do his work.

Status Præsens.—Patient is over middle-size, his upper body of normal build, while the legs show a remarkable hypertrophic enlargement, which will be subsequently described. Pulse is 72, rhythmical, and the breathing regular. At the apex of the heart there is a systolic murmur; the second pulmonary tone accentuated. Liver dulness extends toward the left; the spleen dulness is small. Hydrops ascites questionable—positive evidence, owing to the thickening of the lower belly wall, not possible.

Inspection of the lower body-region (see Pictures 72 and 73, taken by Erwin Bell) show the colossal, misformed, irregular increase in size of the lower extremities, including the scrotum and penis, with the formation of lumpy and roll-like masses and deep grooves. The whole affected region is of hard consistence, and it is impossible to lift up the stretched skin in folds, so firmly is it attached to the subjacent tissues; the skin is in places smooth, in others the seat of crusts, scales, and wart-like excrescences. The thickening of the skin extends up to the groins and backward to the gluteal region. There is hypertrophy of the prepuce, and the glans cannot be bared; the skin is thickened, and the integument of the penis shows on its upper periphery numerous warts. Owing to the hypertrophy and thickening of the prepuce some drops of urine are constantly retained within its cavity. The skin on the scrotum, as well as the subcutaneous tissue, is thickened (no hernia and no hydrocele), and seems as if infiltrated with urine; both testicles can, however, be clearly felt.

The skin of the left inguinal region is extraordinarily thickened, and does not show, by coughing, the slightest swelling;

the right inguinal ring seems somewhat open. The skin is here hypertrophic and leathery, with small depressions; glandular swelling in groin, although not markedly so.

The left thigh shows two large tumors. The larger tumor (an immense formation, more than double the size of the head), on the posterior inner side of the left thigh, is pedunculated and pendulous, and the skin calloused. The massive rolls consist only of thickened skin and subcutaneous tissue. On the upper end of this large roll-like knoll are wart-like excrescences. The skin of the lower leg reminds one of the skin of pachyderms; is thick, hard, and immovable, but its cutaneous functions undisturbed. On the right side the thigh is quite intact, the skin rather soft, but from the knee down thickened. The poplitea are both normal. There is no paralysis or fracture of the lower extremities. The massively thickened lower legs are separated from the feet by a deep groove. The feet themselves seem to be small; this is, however, only apparent, as it is due to the contrast. The skin of the feet is soft and apparently normal, although somewhat edematous upon the dorsal aspects, the hollow depression made by the pressure of the finger remaining for some time.

The exact measurements of the separate elephantiasic parts are as follows:

Left.—First swelling or tumor of the lower leg: circumference, 59 cm.; furrow, 16 cm.; calf, 84 cm.; patella length, 13 cm.; lower part of the thigh, 125 cm.; outside length from malleolus ext. bis spina ant. sup., 105 cm.

Right.—First tumor or swelling, 56 cm.; furrow, 30 cm.; calf, 69 cm.; patella length, 9 cm.; thigh, 48 cm.; outside length from malleolus ext. bis spina ant. sup., 99 cm.

Scrotum.—Raphe length, 34 cm.; diameter, 34 cm.; circumference, 82 cm.

Body-weight of patient, 127.45 kg.

No *albumin* in urine. No chyluria; no lymphorrhea. The investigation of the blood as to the presence of Filaria sanguinis hominis and the embryos was negative.

The patient was operated upon in the surgical clinic of von Eiselsberg, the large tumor of the left thigh being satisfactorily removed; so that, at the end of the summer, further surgical measures for the removal of the other growths will be undertaken.

PLATES 74 and 75.

Xanthoma Tuberosum.

R. P., aged 42 years.

History.—The father of the patient died of liver-disease; his mother and brothers and sisters are living and healthy. About ten years ago the patient began to notice the appearance of small tumors on the extensor surface of the upper extremities. They gave rise to no discomfort, except when struck or pressed upon, when they felt slightly painful. In the course of the year similar growths made their appearance on the nape of the neck, on the buttocks, and on the extensor surfaces of the lower extremities. For the past three years the condition has remained about stationary.

Status Præsens.—Patient is of medium size, strong, but pale, with considerable panniculus adiposus. The internal organs are normal. On the nape of the neck near the border of the hair, on the extensor surfaces of the upper extremities, the buttocks, and the extensor surfaces of the lower extremities, the skin is the seat of numerous growths, lentil to hazelnut in size, rounded and prominent; partly smooth and partly cleft. The borders are of a bright-red color; toward the center of the growths this becomes of a fat-yellow color. Between the closely-crowded and confluent growths are lentil-sized cicatricial depressions, with an irregularly-pigmented border.

Urine-examination: Albumin, about 0.067%; sugar, 5%; quantity passed in twenty-four hours, 1260 grams; specific gravity, 1031; color, wine-yellow, clear; no renal elements in sediment.

Histologic examination of one of the growths shows that the tumor consists of fibrous filaments taking origin out of the connective tissue of the skin; the yellow fat lies in the cells of the fibrous filaments. The tumor is not inflammatory in origin.

Treatment.—Patient was advised to take a six weeks' course at Carlsbad, with restriction of albuminous foods and the use of abundant vegetable food. During this treatment there was a remarkably rapid involution of the xanthoma-lesions; in such growths the peculiar scar-like depressions with pigmented areola, above mentioned, remained; the sugar disappeared entirely from the urine.

The patient presented himself at the end of May, 1898, with new nodules; and sugar had reappeared in the urine.

[This case was published in full by Dr. G. Toepfer, in the *Archiv für Dermatologie und Syphilis*, Band 40, 1897.]

Tab. 75.

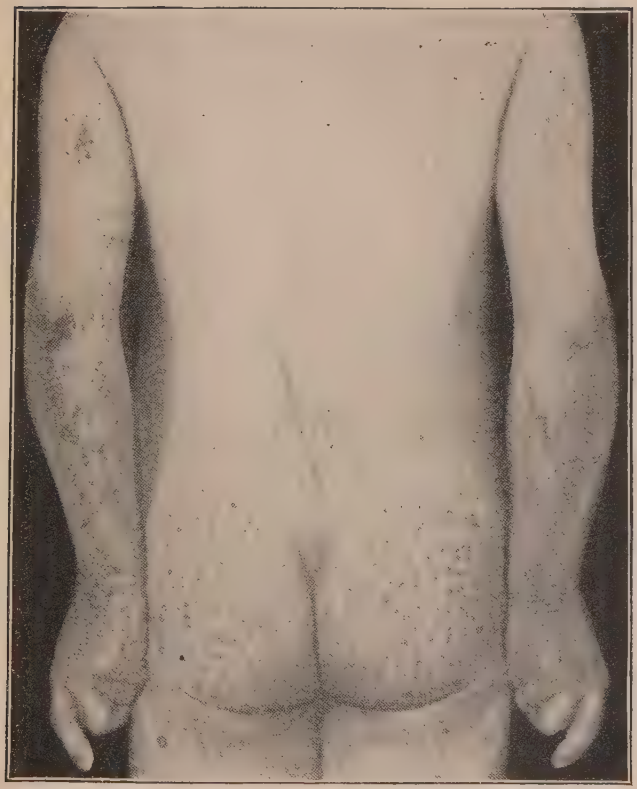

PLATE 76.

Nævus Vasculosus.

J. K., aged 22 years, workman, states that he has had the blood-vessel marks since earliest childhood, and that he has never noticed any increase in size. The parts involved are well shown in the picture. The formation is but slightly, if at all, elevated; is of a bright-red color; is not painful, and it has had no impairing influence upon the function of the leg.

PLATE 77.

Nævus Vasculosus et Verrucosus.

The seat of the affection, the left temporal region, is copper-red from minute capillary enlargements, and irregular in shape. Scattered over it are larger dilated capillaries, and small growths or elevations made up of hypertrophic connective tissue and blood-vessels.

Tab. 77.



PLATE 78.

Lupus Erythematosus.

F. H., aged 38 years, female, noticed for a number of weeks the appearance of an eruption on the end of her nose.

Status Præsens.- The disease is seated upon the tip and left ala of the nose. The area is slightly elevated, and is sharply defined from the healthy skin by a red, somewhat raised border. There is slight scaliness, the scales being markedly adherent and of a grayish and greenish-gray color; upon their removal the base is noted to be livid red.

A salicylated mercurial plaster was advised, under which the patient was improving, when she failed to continue her visits to the dispensary.

PLATE 79.

Lupus Erythematosus.

N. E., aged 40 years, admitted Apr. 15, 1898. The disease was first noticed two years ago, appearing on the nose and near by on the cheeks. Under treatment improvement then ensued. The present exacerbation patient observed eight weeks before admission.

Status Præsens.—Nose, cheeks, and ear show patches in various stages of the disease. The areas are all slightly thickened and red. In some the surface appears stretched and shiny. For the most part, however, the patches are covered with lightly-adherent whitish scales, somewhat greasy in character.

Treatment.—Improvement ensued from an application of plaster made up of equal parts of mercury and soap, with the addition of 10 per cent. of salicylic acid; the patches became paler, scaling lessened, and the infiltration gradually disappeared. Four years later the patient came again under observation with syphilis—the face showed no sign of the former disease.

PLATE 80.

Folliclis.

[This and the various similar conditions known under the names of acne necrotica, tuberculides acneiformes et necrotiques, necrotic granuloma, acne varioliformis, pustular scrofuloderm, etc., are believed by some authors to be the same, or closely allied affections.—Ed.]

J. D., female, aged 26, a teacher, was always healthy, as likewise her parents and brother and sisters—except one brother, who died of tuberculosis. About six years before the patient had noticed an outbreak of red papules on the left upper arm. In the past two years similar lesions have gradually developed on the elbow joint, on the forearm, and on the hand. The patient, an intelligent woman, stated that the lesions begin as red papules, which scale or crust and disappear, leaving slight pits or depressions. The malady had given rise to no subjective symptoms.

Status Præsens.—The subject is middle-sized, well-nourished, with soft skin and brown hair. The internal organs are normal. On the left upper arm, and especially on the outer and anterior sides, are numerous, flat, pea-sized papules, which are in all stages of development and involution or disappearance—leaving a depressed white scar. For the most part the lesions are discrete and isolated, but in the neighborhood of the elbow are aggregated. The forearm is tolerably free; on the hand-joints, back of hand, and on the fingers are to be found some rounded, half-rounded, livid, and brownish-red papules, most with a tendency to form small-fingernail-sized confluent groups, but in which the constituent lentil-sized papules can still be clearly recognized. In consistence they are tolerably hard, and under finger pressure only partly lose their color. On their summits are to be seen horny epidermoidal flakes, through which, centrally, a pustule projects. These scales can be removed only with difficulty, and show beneath an easily bleeding, sharply circumscribed depression. Nearby one sees also older lesions with peripheral involution and flattening of the papule; where the central scale has been cast off can be seen the small pitlike depression or scar, which at first is pigmented and surrounded by a slightly hyperemic areola, but which later becomes white and flat.

PLATE 81.

Lupus Vulgaris (Lupus Serpiginosus).

K. A., aged 14 years, female, admitted Mar. 21, 1898, stated that the disease had existed since childhood. Several of her sisters died in infancy; she herself was always healthy.

Status Præsens.—Patient is large, slenderly built, and pale. Apex of left lung infiltrated; heart normal. In the region of the left thigh, involving the upper two-thirds, outer side, is observed a wrinkled scar. In this scarred area are numerous flat, reddish, irregularly-distributed and -arranged tubercles, in greater number and more crowded toward the posterior border. Some of these tubercles are covered with a thin crust; some are redder in color and show minute blood-points. The posterior boundary-line is made up of a thick wall of crust-formation.

Treatment.—Under chloroform, enucleation, Paquelin cautery, and excision. Healing ensued and patient was discharged cured forty-three days after admission.

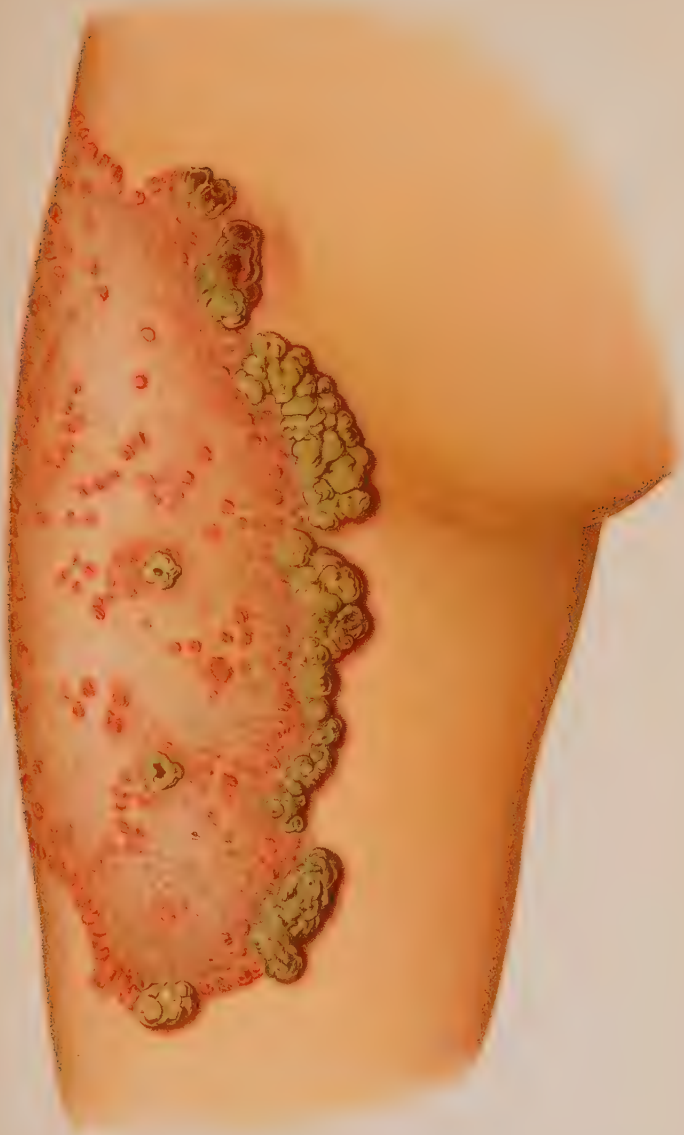

PLATE 82.

Lupus Vulgaris (Lupus Exulcerans, Lupus Exedens).

W. A., aged 22 years, shoemaker, was admitted Jan. 6, 1897. The patient stated that the skin-affection had existed since he was two years old, and that he had been under treatment several times. At present there were some pain and itching. One brother and his parents had died of consumption.

Status Præsens.—On the inner aspect of the left thigh there is a palm-sized, bright-red, infiltrated patch, partly scaly and the central portion cicatricial. On the borders reddish-brown tubercles are to be seen. In addition to this area isolated patches covered with crusts exist near by. After removing the crusts superficial ulcerations are disclosed. On the extensor aspect of the thigh, at the same height, is a half-dollar-sized area, similar in character. Besides these areas there are elongated, atrophic, somewhat depressed scars in the popliteal region.

Treatment.—Under chloroform the patch was excised and the skin stretched from the two sides and stitched together; later the uncovered wound was covered with transplanted skin. The patient was discharged cured four months after admission.

PLATES 84 and 85.

Chronic Tuberculous Ulcerations on Back of Hand. Scrofulo-gummata on Forearm.

M. M., aged 69 years, female, was admitted Oct. 18, 1895.

History.—The patient stated that in her youth she had been subject to a cough for a long time, which her physician had declared to be a lung-disease. For some years the symptoms of lung-disease had practically disappeared. Ten years ago the patient had caries of the right middle finger, which at first improved, but which two years ago became so much worse that enucleation was practised.

Status Præsens.—The patient is rather slenderly built but is moderately well nourished. Her muscles are flabby and her skin pale. At apex of the right lung there is a somewhat shorter percussion-sound; some emphysema. The right upper extremity, as to size and nutrition, showed no difference from the left, except that the right middle finger is gone. The scar from the latter reaches considerably up the hand. The surface over the metacarpal bones of the second and fourth fingers and extending slightly over that of the little finger, is rugous and covered with honey-like crusts, beneath which are shallow ulcerations; the surrounding skin is reddened. On both the corresponding fingers are small tubercles somewhat scaly. On the forearm below the elbow is a livid node about half the size of a hazelnut. Above this, separated by a band of sound skin, is an infiltrated group of similar, but smaller, lesions. Under the olecranon, on the extensor aspect, is a crusted ulcer two fifths inch wide and over a half inch long, with moderately inflamed areola, covered with crusts. In the axillæ are several bean- to walnut-sized infiltrated glands.

Treatment.—After removal of the crusts various salves spread upon bandages were from time to time applied.

Dec. 12, 1895.—Patient, by her own wish, was discharged; there had been improvement.

PLATES 87 and 88.

Lupus Vulgaris; Phlegmon.

J. A., aged 20 years, trunk-maker, admitted May 9. Th patient has been sick since early childhood; the skin-disease of about fourteen years' duration.

Status Præsens.—Patient is large, very anemic, and em ciated. Pulmonary tuberculosis; amyloidosis hepatis; ne phritis. The left lower extremity is elephantiasic, thickene and edematous; the dorsum pedis and the interdigital space covered with discrete and confluent ulcerations. Scattere groups of lupus-tubercles on the left thigh. On the mucou membrane of the cheek are several millet-seed-sized ulcer On the right thigh, starting from a scattered group of lupu tubercles, is a phlegmonous inflammation, with lymphangiti which extends to Poupart's ligament.

May 15.—Severe pain in the left lower extremity; at th same time there was noted marked increase in the edema an the skin became rugous and wrinkled. A bluish-black disco oration of the toes developed, which rapidly spread. Deat ensued in the night.

Autopsy.—In the biceps muscle of the thigh was an absce the size of the double fist; lying between it and the bone wa the femoral artery. Tuberculosis cutis (lupus verrucosus lupus mucosæ oris; hypoplasia arteriarum; amyloidosis hep atis, lienis, et renum; nephritis subacuta.

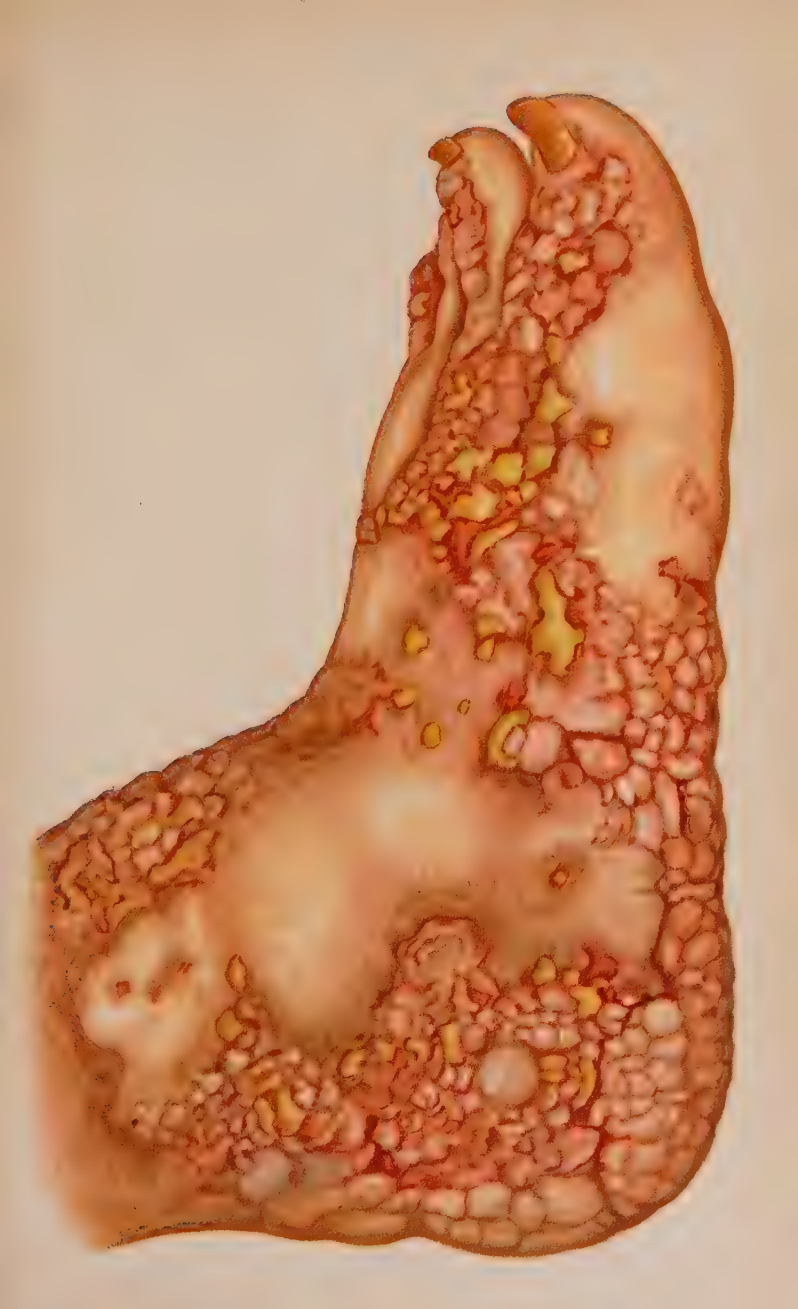

PLATE 90.

Tuberculosis Subacuta Mucosæ Oris.

K. J., aged 42 years, hotel-keeper, was admitted Feb. 8, 1897. The patient stated that for two years he has been sick. His trouble began with a swelling of the right half of the lower lip, which gradually spread superficially. At the same time there appeared ulcerations on the mucous membrane of the mouth. His disease was considered an actinomycosis, and the ulcers were cauterized, partly with the Paquelin cautery and partly with acid. There was slight improvement, which did not, however, continue, and the past month there has been a positive aggravation.

Status Præsens.—The patient is of medium size, well nourished, and strongly built. The left cheek is swollen, and on the inner side, to the extent of a silver quarter, are found hemp-seed- to small pea-sized papillary growths. The mucous membrane of the lips as well as that of the left cheek near the mouth-angle is swollen and the seat of numerous millet-seed- to hemp-seed-sized, and several larger, irregularly-shaped ulcers, covered with grayish-yellow adherent deposit. The gums of the upper and lower jaws show similar changes.

The lungs, except the apex of the right, are normal; over this latter the percussion-sound is shorter and duller; auscultation gives râles, whistling, and irregular inspiration and expiration.

The plaques in the mouth are very painful, and in them the presence of tubercle-bacilli was demonstrated.

Treatment.—Applications of a 1 per cent. sublimate solution, and cauterization with 20 per cent. lactic acid; both gave considerable pain. The disease progressed, showing no disposition toward improvement, and the patient, at his own request, was discharged after a stay of thirteen days.

PLATE 91.

Panaritium Tuberculosum.

W. J., aged 48 years, with advanced pulmonary tuberculosis. The patient was of strong bony structure, but cachectic. He stated that in 1891 a small ulcer appeared at the nail of the middle finger of the right hand, which since that time had persisted and gradually spread over the third and second phalanges. The finger is thickened toward the end, especially at the joint. The skin is livid. The nail is in process of being cast off, the base being yellowish and to some extent broken off, and lifted up from the matrix. The uncovered portion shows ulceration covered with crusts. On several places are to be seen small pea-sized to bean-sized ulcers covered with granulations; in addition there are several crusted ulcers. The movability of the finger, except between the first and second phalanges, is compromised. The patient has boring- and tearing-pains in the affected parts, at which times the finger always swells and breaks out in one or two spots, from which pus exudes; this takes place mostly about the nail. This pus-formation has, he stated, only been noticeable the past several months; during this period, too, the bones of the part have become involved. Formerly the finger was dry, not so swollen, and less painful.

PLATE 92.

Tuberculosis Cutis.

F. B., aged 54 years, porter, was treated in the dispensary-department. Patient was otherwise healthy and strong, although at the time somewhat emaciated.

Status Præsens.—The disease occupies the region between the index and middle fingers of the left hand; the affected area is elevated, mildly inflammatory, and irregularly furrowed, and of the size of a silver half-dollar. To the touch the individual nodules are somewhat elastic, and by strong pressure sebaceous-looking material in small quantities exudes from the furrows. The growth is not painful. The disease began six months previously, and had, at first, the appearance of a wart. Patient was not aware of any cause for the disease.

PLATE 93.

Tuberculosis Verrucosa Cutis.

M. M., day laborer, aged 24 years, was admitted June 3, 1891.

The patient had, in 1885, peritonitis and an attack of pleurisy. Two years ago he was treated in the hospital for a cough. Parents and his twelve brothers and sisters are healthy. Three years ago there appeared on the upper border of the back of the left hand a wart, which extended steadily. Gradually other similar formations appeared. In course of time the affection attained its present extent, without having been in any way painful. He stated that he frequently had night sweats and pain in the right half of the breast.

Status Præsens.—Patient is small, with medium-sized bones, moderately nourished, and anemic. Thorax short, but tolerably wide. The left side of the thorax somewhat less arched than the right, and, especially in the upper part, flatter. Shoulders are rather deeply placed. Supraclavicular grooves moderately deep—the left deeper than the right; both by superficial and deep respiration this side shows slightly less movement than the right. The sound in the supraclavicular fossa is on the left, a little higher and shorter; no difference is noticeable in the infraclavicular sound. The edge of the right lung in normal position and movable. Area of heart dulness is small. Over the fossa supraspinata is a light muffled sound, also in the upper part of the interscapular area; from there downward it is normal. In the fossa supraspinata a faintly-heard blowing, no rattling. In the left fossa supraclavicularis expiration is longer and louder than that on the right. With the exceptions named, there is everywhere vesicular respiration. The heart tones are pure.

Over the lower part of the metacarpal bones of the middle, ring, and small fingers of the left hand is an area 5 cm. long, 2.5 cm. wide, and 1 to 2 mm. above the normal level. The central part is covered with dried crusts and slightly fissured. The periphery is made up of lentil-sized papules, from the middle point of each can be scraped out a plug, leaving behind a slight depression. From some of these papules a grayish purulent liquid can be squeezed out. The base of the whole area is leathery to the touch and can be lifted up from the sub-

PLATE 94.

Lepra.

(From the Clinic of Professor de Amicis, Naples.)

P. F., from Bisceglia (province of Bari), aged 43 years, baker, married, was admitted Jan. 12, 1895, and discharged Jan. 18.

History.—There was no hereditary tendency. In his home-region were several lepers. Two brothers had the same disease before he had it; neither had been outside of the country. Shortly before the disease appeared the patient had married; he has no children; his wife remains healthy. The disease first showed itself when he was twenty-seven years old, with the appearance of bullæ, at first on the legs and then on the upper extremities, with resulting sluggish ulcerations which did not heal. Gradually the face began to share in the process, becoming considerably disfigured.

Status Præsens.—Head-hair normal; everywhere else the hair has disappeared, even in the genital region. The skin-color of the face is slightly bluish in tinge, and the appearance considerably distorted and disfigured. Over the forehead, and especially the eyebrows and glabella, the skin exhibits numerous reddish-brown, more or less confluent, lumpy infiltrations, with numerous furrows. Over the malar bone there is capillary enlargement. The appearance of the nose is completely changed; the bridge is flat and sunken, especially at the junction of the bone with the cartilage, where a semicircular furrow is noticeable. The alæ nasi are somewhat infiltrated, and the nasal openings contracted or closed, especially the right one; the bony septum is absent. The lips are bloated. The chin shows infiltration, with many furrows, but less numerous and less deeply than the forehead.

There are many infiltrations and yellowish spots on the upper extremities, on which ulcerations, torpid in character, are also observed, more especially on the extensor surfaces of the right forearm and on the dorsal surface of the right hand. There are likewise similar conditions on the elbow and dorsal surface of the left hand. On the buttocks and lower extremities the same lesions are to be observed. The scrotum, the skin of the penis, the prepuce, and the glans penis are infiltrated. The mucous membrane of the hard and soft palates, the tongue, epiglottis, and the arytenoid folds show more or less gray diffused infiltration. Everywhere anesthesia.

Bacteriologic examination of blood from the infiltrations showed the Hansen bacilli.

Tab. 94.

PLATE 95.

Lepra.

(From the Clinic of Professor de Amicis, Naples.)

D. E. F., of Ischitella (province of Foggia).

History.—The patient came of a fisherman's family. His parents are living and healthy; his grandfather suffered from the same disease. Of the seven brothers and sisters, the patient was the third. His four brothers, the second, fourth, sixth, and seventh children, have also the same disease; the remaining two are healthy. The affection first appeared in 1880, when he was twenty years of age; he came under medical observation in May, 1892.

The disease began with attacks of chilliness, with elevation of temperature following, and the appearance of red spots, at first on the upper extremities, with subsequent tubercle-infiltration. After some months it showed itself in the face, and later also on the lower extremities; in this latter region accompanied, for a time, with severe muscular pain. Infiltration followed soon after the macular lesions or stage, especially in the face, of which a considerable part is involved and much disfigured. On the trunk the disease spread in the form of spots and tubercles. Recently the voice has been hoarse and weak.

Status Præsens.—An examination shows that there are numerous tubercle-infiltrations, scattered and confluent, separated by more or less deep furrows, anesthetic, reddish, and brick-red in color, covering the forehead, the alopecic eyebrows, cheeks, lips, and chin, so that the face has lost its original appearance and is now suggestive of leontiasis. Also on the upper extremities are to be seen similar changes, tubercles and spots, more or less confluent, especially on the elbows and dorsal surfaces of the hands and fingers, where also some sluggish ulcerations are to be observed. On the trunk and lower extremities similar lesions are also to be seen, but are less abundant and less confluent.

The mucous membranes of the mouth and of the hard and soft palates are covered with grayish papular infiltration; likewise the epiglottis and vocal cords. There is everywhere anesthesia.

Bacteriologic examination of blood from the infiltrations gave the Hansen bacilli.

Tab. 95.

PLATE 96.

Lepra.

(From the Clinic of Professor de Amicis, Naples.)

D. S., from Marsala, lumberman, unmarried.

History.—Patient is of robust constitution and of good growth and size. His parents and the relatives of the family are healthy. At his home some cases of the disease are observed. The patient had never travelled. Toward the end of May, 1878, in his nineteenth year, he noticed the gradual appearance of scattered spots, of varying size, of reddish-brown color; at first on the lower extremities and then on the upper extremities. Soon afterward these were followed by similarly-colored milletseed- to lentil-sized papular elevations, which from the beginning were accompanied by a burning sensation, and later by itching. Finally on the affected parts the sensibility was lessened. After one and a half years he observed falling out of his eyebrows and eyelashes. In Nov., 1880, the disease having been gradually progressing, he appeared for the first time at the clinic; then again in 1881, 1886, and 1888, where he at the last time presented the following lesions and symptoms.

Status Præsens.—*Head.*—Striking tubercle- and nodular infiltration of the forehead, the region of the eyebrows, glabella, the nose, the lips, cheeks, and chin, of the size of a silver quarter or smaller; many superficially ulcerated and covered with blood-crusts. Complete loss of hair of the face. An almond sized nodule on the left upper lid and several smaller, millet-seed-sized, on the right lid; an almost completely pedunculated nodule on the conjunctiva bulbi of the left eye, with accompanying keratitis; the same on the right eye. Nodular infiltration of the ear-muscles. The hairy scalp is normal.

Trunk.—On the breast disseminated reddish-brown spots with small papular elevations, especially in the neighborhood of the nipples. Some larger, diffused, brick-red spots with symmetric papulotubercular elevations on the shoulders and loins.

Neck.—Two nutmeg-sized, half-rounded nodes with smooth surface, one on the left side on the upper third of the sterno-cleido-mastoideus muscle, the other on the right side over the mastoid process. Several smaller nodes on the nape of the neck.

Upper Extremities.—Almost the entire surface is reddish-brown, with the exception of some disseminated places where

Tab. 96.

the skin is normal. From the shoulder-joint down to the elbow-groove can be seen, on the extensor surface, nodular, lupus-like elevations; these are on the upper part confluent, and on the left side give rise to nut-sized ulcerated nodes. On the forearms are numerous nodules, nodes, and tubercles, some somewhat pedunculated, smooth, and with shining surface; others closely ribbed and covered with bran-like scales. They are irregularly distributed, with the greater number upon the extensor side. In the wrist-region are large confluent tubercles bunched closely together; traversed with furrows and scars and beset with ulcerating nodules. Owing to a deep infiltration of the dorsal aspect the hands are much maimed, and the fourth and fifth fingers are held in a flexed position. Atrophy of the interosseous, thenar, and antithenar muscles.

Lower Extremities.—As on the upper extremities, the eruption is here widespread, extending from the gluteal region to the feet. In addition to numerous spots, numerous elevations and tubercles are to be seen. Some are pedunculated, others ulcerated and crateriform; the largest being over the tendon Achilles, along the anterior border of the tibia, and on the front part of the knee. The skin on the posterior surface of the legs is irregularly infiltrated. From the dorsal surface of the feet to the ends of the toes are exceedingly numerous elevations and tubercles, crowded closely together; on the right foot is an isolated giant tubercle the size of a silver quarter. Also on the soles are bunched tubercles.

Genitalia.—Tubercles on the skin of the penis and the scrotum. Extensive, almost almond-sized infiltrations in the right epididymis; in the left epididymis still larger nodes and numerous smaller tubercles on the surface of the testicles.

Mucous Membranes.—The entire hard palate is covered with an ulcerated, grayish covered granuloma. There are also ulcerations and scars on the soft palate and tonsils. The uvula and nasal mucous membrane, especially on the septum, are the seat of extensive infiltrations.

Lymphatic System.—The glands in the neck and in the groin are markedly enlarged, the latter almost as large as a fist.

Sensibility.—Sensations of touch, heat, and pain very much diminished and in some places entirely wanting.

Urine.—The urine is ropy and rich in mucin.

Microscopic examination of blood from the diseased nodes disclosed numerous lepra-bacilli.

PLATE 97.

Epithelioma Cicatrisans.

J. J., aged 55 years, day-laborer, admitted Sept. 28, 1892. The disease began six years previously, on the right temple, as a small nodule, from which point it spread as a continuous ulcer on to the cheek and to the right eyelid.

Status Præsens.—The right cheek is, from the ear-muscle posteriorly to the nasolabial fold anteriorly, upward toward the attachment of the masseter muscle, and downward to the inferior maxilla, changed into a smooth whitish scar. The border of this area consists of an almost continuous ulcer, somewhat elevated, with a base showing but slight infiltration. The base seems made up of anemic granulation-tissue. The disease has eaten through the upper eyelid, and the lid is somewhat drawn outward by the scar-tissue. The patient complained of stinging-pain occasionally in the ulcerated part.

At intervals the proliferation was curetted, and in this way for a time destructive action or progress was stayed. On Dec. 15 the growth was investigated histologically and the diagnosis of epithelial carcinoma confirmed.

Under anesthesia the ulcerated surface was thoroughly curetted and then cauterized with the Paquelin cautery, so that all, with the exception of a linear ulcer at the corner of the mouth, healed and scarred over.

Scarcely four weeks had elapsed after this operation before the remainder of the eyelid at the inner canthus broke down; a new destructive action was also observed over the zygoma, and the epithelial masses at the corner of the mouth began to grow considerably. The patient's weight, with slight fluctuation, remained at 54 kg. The ulcerated surfaces extended and involved the scar-tissue. The eyeball was attacked, and lay in the orbital cavity surrounded by epithelial necrotic masses. The patient complained of increasing pain, which could only be relieved by constant use of morphin.

Dec. 22.—In the center of the extended ulcers small islets of scar-tissue are again to be seen, although the disease has now spread over the entire chin and also over the middle of the nose.

The patient was finally obliged to return to his home, and

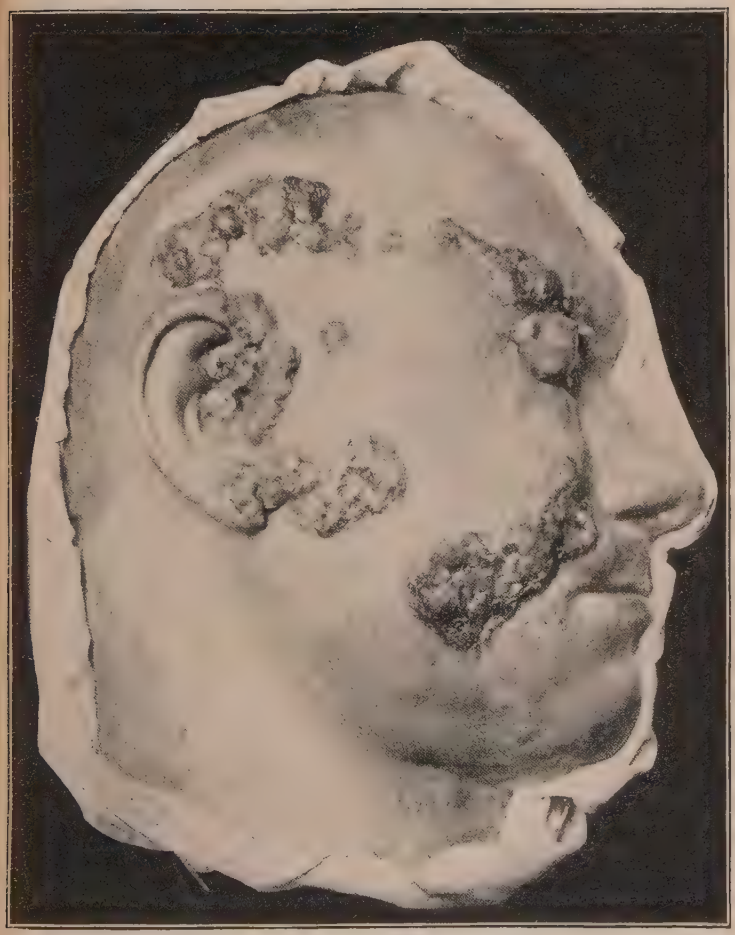

left the hospital on Sept. 21, 1894. The case was under observation for two years.

The case is remarkable in that in the entire eight years of its existence there had been no tendency to change its character. Further to be noted were the slow course and the tendency to cicatricial formation in the central parts. Later, however, not only did the ulcerated parts advance, but the already formed scar-tissue again gave away. This disposition to cicatricial formation was shown again and again, but the disease slowly progressed. The patient, from constant pain, became more and more emaciated.

PLATE 98.

Carcinoma Lenticulare.

S. A., aged 74 years, admitted July 6, 1896, stated that one year previously the left breast began to harden.

Status Præsens.—The head is directed toward the left, and it can be turned only to a moderate degree, and that with difficulty. The skin of the left breast, of the neck-region, and extending to the back and to the face, is the seat of a yellowish-red to violet-colored, tough, hard, in part cicatricial-looking growth or tumor. The border is, especially at the lower part, sharply defined against the healthy skin and slightly elevated. Toward the face and back its junction with the normal skin is not so clearly recognizable. The left side of the face is edematous. The submaxillary, supraclavicular, and infraclavicular glands are hard, infiltrated, and enlarged. The opening of the mouth is somewhat hindered, owing to lack of complete movability of the lower jaw. Swallowing is likewise less easy than normally.

In the following two months no material change ensued. The face and shoulder varied somewhat as to the amount of edema.

On Sept. 2, two months after admission, the patient died with symptoms of collapse.

Autopsy.—Diffused and lenticular sarcoma of the skin over the left breast, arising from a carcinomatous mammary gland; sarcomatosis of the pleuræ, peritoneum, and uterus.

PLATE 99.

Epithelioma.

W. M., aged 60 years, cook, came under treatment May 5 1897. The patient first noticed the disease about five months previously. It had given rise to no pain. She had always enjoyed good health, except having, when aged 40, a peritonitis from which she made a good recovery. She has given birth to one child. Menstruation ceased five years ago.

Status Præsens.—The patient is of moderately strong build and fairly nourished. On the lower part of the left labia majora is a dollar-sized ulceration with an infiltrated and elevated base. The surface is irregular, red, and uneven, with here and there whitish spots. The secretion is scanty. There is no enlargement of the inguinal glands. The opposite lip is not involved. Above the growth, on the same side, toward the vagina, is a bean-sized nodule with epithelial proliferation and beginning central destruction.

Treatment.—Under chloroform the diseased area was excised and the patient was discharged cured on June 5.

In May, 1898, about a year later, there was a recurrence with involvement of the inguinal glands. Another operation followed, healing taking place in six weeks.

PLATE 100.

arcinoma Penis.

M PROF. ALBERT'S CLINIC.)

N. nitted July 9, 1890.

H previously patient met with an ac
dent, scrotum and penis. The wou
healed began between the scrotum a
base of t o an ulcer appeared on t
penis, wh d gave rise to considera
pain. Late od deal of flesh.

Status P l, misshapen, and t
seat of fissures than five inches lo
and four inches in ci ace. On lifting the organ a pal
sized ulcer is seen, with hard borders and covered with irregu
sluggish granulations. The inguinal glands of both sides a
enlarged.

Treatment.—Amputation of penis; removal of inguin
glands. The urethra was dissected out and stitched to t
perineum.

PLATE 101.

Carcinoma Penis.

(From Prof. Albert's Clinic.)

According to the statement of the patient, the disease h
existed six months.

Status Præsens.—The patient is strongly built, but ema
ated. The skin of the penis is covered with scars, partly p
mented and partly changed into thick, tough infiltration;
high degree of phimosis exists. On the under half the infilt
tion is continuous and the base irregularly excavated and ulc
ated, and the whole mass is hard and dense. The lymphat
on the dorsal side of the penis, and the inguinal glands, a
swollen and hard.

Treatment.—Partial amputation of the penis, with plas
operation for urethra.

PLATE 102.

Tinea Favosa.

S. L., aged 25 years, admitted Aug. 18, 1896. For a numbe
of years scalp-eruption and hair-loss had existed.

Status Præsens.—The scalp-hair, with the exception of
narrow fringe posteriorly, has entirely disappeared. The scalp
skin is covered in many places with sulphur-yellow, kidney
shaped crusts. Between these larger crusted areas are sca
tered pinhead- to small pea-sized straw-yellow lesions; th
same also on the shoulder.

After three months' treatment the scalp is clean, and no ne
lesions or crusts have appeared. It remained in same conditio
when discharged Jan. 5, 1897.

PLATE 103.

Pityriasis Maculata et Circinata.

S. F., aged 18 years, admitted Feb. 13, 1896. One day befo admission the patient noticed that the spots had appeare His attention was first called to them by the itching.

Status Præsens.—The thorax, abdomen, and the flexor su faces of the extremities are the seat of numerous efflorescence On the lower belly and pubic region the spots are pale red, t larger of which show a central whitish epidermic scale. Th larger number have already paled in the central portion showing peripherally faintly-wrinkled epidermis, and here a there partly-detached scales. The border of the patches slightly elevated, the epidermis of which is smooth and re dened. Similar features are presented by the patches on oth parts.

[In the German edition this plate is described under t heading of "herpes tonsurans maculosus et squamosus," variety of ringworm. American and English observers, ho ever, consider the disease as here pictured as pityriasis mac lata et circinata, a disease entirely independent of the rin worm-fungus.—Ed.]

PLATE 104.

Tinea Trichophytina Corporis (Tinea Circinata).

L. W. admitted Nov. 16, 1895; discharged cured Nov. 2
Eight days previously patient noticed the central part of patc
since that time it had gradually enlarged to its present dime
sions.

Status Præsens.—Upon examination is found on the rig
breast a half-dollar-sized efflorescence, the center of which
yellowish-red and slightly scaly. The peripheral part of t
patch is somewhat elevated, slightly crusted and scaly, and re
dish in color. The outermost edge is sharply defined agai
the sound skin and is of a bright-red hue. There is itching, b
not to a troublesome degree.

PLATE 105.

Tinea Trichophytina Corporis (Tinea Circinata).

S. F., aged 18 years, locksmith. Under observation from May 19 to 28. Fourteen days previously the disease had appeared on the face, and during the past week on the left upper extremity. Horses were kept in the house in which patient lived.

Status Præsens.—On the face, and especially on the left side, are numerous pustular efflorescences, varying in size from a pinhead to a pea, many covered with a yellow-brown crust. On the flexor side of the left forearm, close to the hand, is a large, rounded, infiltrated, reddish patch with an elevated periphery; inside the border are a number of papules and vesicles. Cultures were made with the contents of the vesicle and the trichophyton demonstrated.

Treatment.—Lassar's paste for the face; naphthol-sulphur paste with resorcin for the patch on forearm. Complete cure in eight days.

PLATE 106.

Tinea Trichophytina Corporis (Tinea Circinata).

J. W., railroad servant, was admitted July 10, 1902.

The patient had been under our care a year previously with a papular syphilid and ozena. This time he came on account of syphilitic cerebral symptoms which had developed during military exercises and which compelled him to seek the hospital for treatment. His general condition is a serious one, as he is paralyzed.

In addition to these graver symptoms he had on his forearm a dollar-sized ring-shaped patch, with reddened and infiltrated edges beset with vesicles, with a clearing central portion, the latter having become quite pale and but little out of the normal.

The patch increased in size, so that, on July 28, when the annexed picture was taken, the following conditions existed. On the lower third of the right forearm was a rounded patch which extended across the entire outer aspect of the forearm. The patch was surrounded with a 2-cm.-wide, somewhat elevated and reddened border. This border is beset with numerous milletseed- to pinhead-sized, isolated, and confluent vesicles. Inside of the inflammatory border the skin is pale, with here and there isolated vesicles upon inflammatory bases and capped with an epidermal scale.

Treatment consisted of the applications of corrosive-sublimate lotion, followed by unguentum diachyli; healing resulted



PLATE 107.

Onychia et Paronychia Trychophytica (Trichophytosis).

R. J., aged 22 years, came under observation May 27, 1899. The patient stated that for weeks he had had an eruption in the genital region.

Status Præsens.—Patient is of small stature, with rachitic teeth and crooked thorax (Gibbus). On the scalp the hair is dry and dull looking, the scalp seborrheic with brittle, slight exfoliating grayish crusts. The eyebrows are also the seat of scaliness, and the eyelids are covered with crusts and scales, eyelashes almost gone. On the face there are follicular reddened papules, in addition to some rounded moderately scaling patches. On the extensor surface of the upper extremities are to be seen patches of lichen scrofulosorum, which are partly, owing to scratching, covered with hemorrhagic crusts. On the left forearm is a pale-brown, elevated bean-sized crust, and in its neighborhood two or three lentil-sized smaller efflorescences. On the forearms and on the dorsum of the hands are seen small follicular pustules with reddened areola, and others which have been scratched and have dried and become covered with crust and surrounded by a scaling periphery.

All the fingers of the right hand and those of the left hand, except the forefinger, are affected with paronychia. On the left hand the nail-fold of the forefinger is slightly reddened; in one place in the same there is a broken vesicle with torn epidermis. The thumbs and, to a greater extent, the small finger and the middle finger are likewise affected; the nails of these fingers are free. On the thumb, ring, and small fingers of the right hand, as well as the ring finger of the left hand, the matrix of the nail, up to first interphalangeal joint, is swollen, reddened, and covered with torn epidermis and lamellar crusts; the nails are brownish, bent, fragile, and cracked on the end, with furrows on the lunula; the nail of the right ring finger is lifted up from the matrix, with a dirty white and splintered base.

On the trunk, here and there, are lichenoid efflorescences; the abdomen, from above the navel, about the width of the space between the mammæ, down on to the perineum and nates, shows the following condition of the skin: The edge is

exfoliating or scurfy, and toward the inner side is covered with yellowish crusts; the epidermis, especially that of the scrotum, inflamed and swollen; the periphery on the abdomen beset with small pea-sized papules. On the penis, especially on the glans, the surface is partly free and partly beset with isolated scaly papules. The lower extremities are free.

The patient was debilitated, inclined to diarrhea, and was obliged to be particular about his diet—sometimes obliged to take opium to control the diarrhea.

On *June 12* an abscess that existed on the right buttock was, of necessity, opened.

The patient was daily painted over with cod-liver oil.

June 20.—The crusts are loosening, the new epidermis is becoming visible, and the nails on both ring fingers have fallen off. Under treatment with tar baths the patient was able, after forty days, to leave the hospital, rid of the cutaneous manifestation and with his general health improved.

[The author does not, except as to the lichen scrofulosorum, directly state the nature of the more or less general eruption, although the description, especially that of body and genital region implies his belief that the most of it is also due to the trichophyton. In many respects some parts of it correspond to seborrheic eczema in a strumous subject—Ed.]

PLATE 108.

Sycosis.

T. A., aged 54 years, admitted May 7, 1896, stated that in 1890 he noticed a papule on the upper lip, which later changed into an oozing spot, while immediately in the neighborhood other papules and oozing patches appeared. In the course of four years the process had spread and gradually involved the entire upper lip.

Status Præsens.—The entire moustache region is inflamed and crusted, the crusts mostly confluent and of a greenish color; here and there a small spot covered with horny epidermis, and in some places moist spots with a papillomatous (frambesiform) tendency. The crusting is quite thick in places, and is irregularly and scantily pierced by projecting hairs, which are loosely embedded and which may be quite easily and painlessly pulled out, the root-sheath appearing swollen. In the middle of the lip toward the right upper part the skin is free from crust, reddened, and infiltrated, and to some extent covered with scales. There is no active purulent discharge. From the corner of the mouth the process tends to extend downward, although the crusting here is not so massive and is easily detached.

PLATE 109.

Tinea Versicolor.

J. N., aged 20 years, workwoman, admitted Aug. 18, 1897.

Status Præsens.—Over the breast are to be seen numerous variously-shaped and -sized, yellowish-brown patches. Slight branny scaliness is observable in some, and the epidermal covering is readily scratched off. The color is pale yellowish brown to a darker brown—the darker color being more pronounced at the edges.

Treatment.—Naphthol-sulphur soap, sapo viridis, and dusting-powder of rice-flour. Cure.

PLATE 110.

Actinomycosis.

D. A., aged 42 years. The patient was in the hospital in Aug., 1892, but returned to his home. As his condition had gradually grown worse, he was on request again admitted on Oct. 28, 1892.

Status Præsens.—The patient is very pale, emaciated, and complains of difficulty in breathing and swallowing. Lungs and heart normal. The entire left side of the neck, from the lower jaw down over the supraclavicular fossa, is made up of numerous elevations and depressions. The whole area is hard. Between these depressions the skin is infiltrated and correspondingly raised, and the seat of numerous fistulous tracts of varying depths; out of which there oozes thick pus containing the fungus, appearing as minute grayish-white or yellowish granules. The skin over the lower part of this infiltrated area is of a dirty violet-gray color. Immediately over the left collar-bone is a nut-sized fluctuating tumor covered with pale violet-colored skin; also on the right side of the neck, in the supraclavicular fossa, is a similar growth.

Treatment.—Patient was treated by incisions and the injection of $\frac{1}{4}$ per cent. corrosive-sublimate solutions, and the parts kept covered with antiseptic bandages. Some improvement ensued. The patient insisted upon leaving the hospital three weeks after admission.

PLATES 111 and 112.

Scabies.

H. M., female, admitted Aug. 12, 1897. The patient stated that itching, especially at night, became noticeable six weeks previously, although most of the pustular lesions had appeared more recently.

Status Præsens.—The whole surface is the seat of irregularly-scattered scratch-marks and excoriations; and the extremities are covered with numerous discrete pustules, mostly crusted. The dorsal surface of both hands is studded with well-filled pustules and pus-containing blebs; in some places, more particularly on the fingers, they have been scratched away and given place to raw-looking abrasions.

Treatment.—Wilkinson's ointment; cure.

Tab. 112.

PLATE 113.

Maculæ Cæruleæ; Phthiriasis.

O. F., aged 33 years, baker's helper, admitted Aug. 21, 1897.

In the pubic and axillary regions numerous Pediculi pubis (crab-lice) are present, and ova may be observed attached to the hair-shafts. In addition, in the inguinal region, from the effects of scratching and from applications of mercurial ointment, are to be seen minute excoriations. The body is covered with bluish, rounded and linear, elongated spots up to the size of a pea; the overlying epiderm is uninjured.

PLATE 114.

a. Nits (louse-eggs, ova), attached to the hair-shaft.

b. Head-louse.

c. Body-louse, clothing-louse.

d. Crab-louse.

e. A burrow (cuniculus).

f. Itch-mite egg.

g. Itch-mite, from beneath.

h. Itch-mite, from above.

i. Hair-follicle mite (Acarus folliculorum).



a.

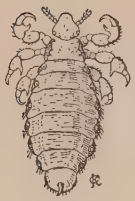

b.

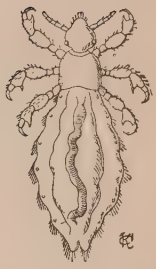

c.

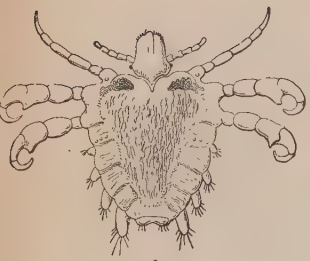

d.

e.

f.

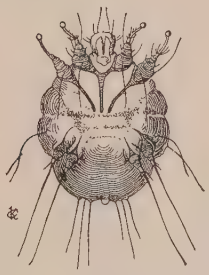

g.

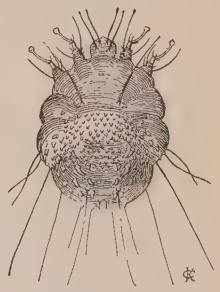

h.

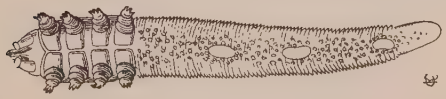

i.

PLATE 115.

a. Ray-fungus.

b. Molluscum epitheliale corpuscle; "molluscum body."

c. Trichophyton (ringworm-fungus) in scalp, hair- and outer root-sheath.

d. Microscopic picture of a hair in trichorrhexis nodosa.

e. Achorion Schönleinii (favus-fungus), from a favus-crust.

f. Microsporon furfur (tinea-versicolor fungus).



a.

b.

c.

d.

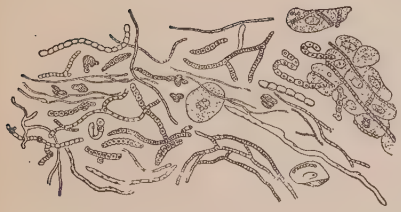

e.

f.

INDEX.

Absence of nails, 169
Acanthosis, 28
  nigricans, 159; Pls. 62, 63
    treatment of, 160
Acarus folliculorum, 257; Pl. 114 *i*
  hordei, 258
  seu sarcoptes hominis, 254
Achorion schönleinii, Pl. 115 *e*
Achromatosis, Pl. 69
Acne, 45
  artificialis, 48
  bromid, 48; Pl. 32
  cachecticorum, 133, 211
  coagminata, 47
  eruptions, toxic, 47
  follicularis, Pl. 3
  hordeolaris, 46
  iodid, 47
  mentagra, 51
  punctata, 46
  pustulosa, 46
  rosacea, 54
    treatment of, 56
  telangiectodes, 202
  treatment of, 48
  urticata, 47
  varioliformis, 210
  vulgaris, 46
    disseminata, Pl. 4
Acnitis, 210
Acrodermatitis, 185
Actinomycosis, 252; Pl. 110
  treatment of, 253
Addison's disease, 175
Adenoma sebaceum, 44; Pl. 3
Albinismus, 167
  partialis, 170
  universalis, 170
Albinos, 170
Aleppo boil, 225
Alopecia, 164
  after syphilis, 165
  areata, 165
  areolaris, Pl. 65
  atrophicans idiopathica, 164
  congenital, 164
  furfuracea, 165
  pityrodes, 165
  premature, 164
  senilis, 164
  symptomatic, 165
  totalis neurotica, Pl. 64
    præmatura neurotica, 164
  traumatic, 164
  treatment of, 166
Anal furrow, eczema of, 140
Anasarca, 183
Anemia of skin, 57
Anesthesia of skin, 154
Anesthetic leprosy, 216, 218
Angina herpetica, 105
Angiokeratoma, 212
Angiomata, 195
Angioneurotic edema, 68
Animal parasites, 254
Anomalies of epidermis, 154
  of hair, 164
  of nails, 168
  pigment, of skin, 170
Antipyrin, eruptions from, 71
Anus, pruritus of, 153
Argyria, 177
Arsenic, eruptions from, 71
  in psoriasis, 123
  zoster, 71
Arsenical hyperkeratosis, 177
  melanosis, 176
Arsenicismus, 176

Ascomyces maduræ, 225
Asiatic pills in psoriasis, 123
Atrophia cutis idiopathica congenita, 184
progressiva, 184
Atrophic scars, 29
Atrophy, general, 184
partial, 183
Autographism, 67

Baldness, 164. See also *Alopecia.*
Balsams, eruptions from, 71
Barber's itch, 248
Barley mite, 258
Bed bug, 260
Bird louse, 258
Blastomycosis, 253
Blebs, 27
Bleeders' disease, 75
Blood-vessel papillæ, 19
Blood-vessels of skin, 22
Body louse, 259; Pl. 114 *c*
Boil, Aleppo, 225
Bridge-swellings, 18
Bromid acne, 48; Pl. 32
Bromidrosis, 36
Brückenknöpfchen, 18
Bullæ, 27
Bullous eruptions, 100
Burns, 81; Pl. 31
cause of death in, 84
of first degree, 81
of second degree, 82
of third degree, 82
prognosis of, 85
treatment of, 85
Burrow, Pl. 114 *e*

Callositas, 154
Callus, 154
Canities, 167; Pl. 65
Cantharides, Pl. 30
Cantharidin, eruptions from, 71
Carbuncle, 93
treatment of, 94
Carcinoma, 234
chimney-sweepers', 235
en cuirasse, 236
lenticulare, 236; Pl. 98
of penis, Pls. 100, 101
Caustics, 35
Cells, lepra, 221
Cheiropompholyx, 37
Chicken lice, 261
Chilblain, 86
Chimney-sweepers' cancer, 235
Chloasma cachecticorum, 174
caloricum, 172
traumaticum, 172
treatment of, 172
uterinum, 172
Chrysarebin in psoriasis, 125
Cicatrix, 29, 180
Cimex lectularius, 266
Clavus, 155
Clothing louse, 259; Pl. 114 *c*
Coil glands, 21
Cold-sense, 24
Colloid milium, 202
Color of skin, 19
Combustio, 81; Pl. 31
bullosa, 82
erythematosa, 81
escharotica, 82
Comedo, Pl. 3
Comedones, 41
Congelatio, 86
escharotica, 87
treatment of, 87
Corn, 155
Cornu cutaneum, 155; Pls. 43, 44, 45
Corps ronds, 161
Corpus glandulæ sudoriferæ, 22
Corpuscle, molluscum epitheliale, Pl. 115 *b*
Crab louse, Pl. 114 *d*
Cracks, 28
Creeping disease, 258
Crusta lactea, 139
Crusts, 28
Culicidæ, 260
Cuniculus, Pl. 114 *e*
Cuticula pili, 20
Cutis, 18
marmorata, 59
propria, 19
testacea, 40
Cyanosis, 59
Cysticercus cellulosæ, 257
cutis, 257

Darier's disease, 160
Dead fingers, 58
Degeneration, senile, of skin, 26
Demodex folliculorum, 257
Dermanyssus avium, 258
Dermatitis, 75
  erysipelatosa, 99
  exfoliativa, 95
    acuta, 95
    generalisata, Pls. 16, 17
    neonatorum of Ritter, 98
      treatment, 99
    treatment of, 99
  factitia, Pl. 30
  herpetiformis, 115
  nodularis necrotisans, 210
  papillaris capillitii, 53
  psoriasiformis nodularis, 97
  scarlatiniformis exfoliativa toxica, 96; Pl. 15
Dermatomyomata, 194
Dermatoses, inflammatory, 60
  squamous, 116
Dermatozoa, 254
Dermographismus, 67
Diabète bronzé, 174
Diabetes mellitus, melanodermic conditions in, 174
Dot psoriasis, 118
Drug eruptions, 70
Dysidrosis, 37
Dystrophic papillaire et pigmentaire, 159
Ductus sudoriferus, 22

Ecchymoses, 27
Echinococcus, 257
Ecthyma, 28
  gangrænosum, 76
Ecthymata per totam cutem dispersa, Pl. 33
Eczema, 134
  acute, 134
    of face, 137
    of genitalia, 137
    of hands, 137
    treatment of, 145
  artificiale acutum, Pl. 49
    vesiculosum, Pls. 47, 48
  bullosum manus, Pl. 52
Eczema, caloricum, 143
  causes of, 142
  chronic, 138
    of face, 139
    pustular, of scalp, 139
    treatment of, 146
  course of, 144
  crustosum, 135
  diagnosis of, 141
  erythematosum, 135
  impetiginosum artificiale, Pls. 50, 51
  intertrigo, 138
  madidans, 135
    et crustosum, Pls. 54, 55
  marginatum, 140, 246; Pl. 53
  of anal furrow, 140
  of genitalia, 140
  of hands, 140
  of lips, 140
  papulosum, 134
  prognosis of, 144
  pustulosum, 134
  rubrum, 135
  seborrhoicum, 40, 52, 141
  solare, 143
  squamosum, 135
  sudamen, 143
  treatment of, 145
  vesiculosum, 134
Edema, angioneurotic, 68
  cutis, 183
  neonatorum, 163
Efflorescences, 27, 28
Efflorescentiæ aggregatæ, 29
  annulares, 29
  circinatæ, 39
  dispersæ, 29
  solitariæ, 29
Elephantiasis, 181, Pls. 72, 73
  acquired, 181
  arabum, 181
  cruris, Pl. 71
  lymphangiectodes, 196
Endothelioma cutis, 231
Ephilids, 172
Epidermis, 17
  anomalies of, 154
Epidermolysis bullosa hereditaria, 98

Epithelioma, 234, Pl. 99
cicatrisans, Pl. 97
Epizoa, 254
Equinia, 94
treatment of, 95
Erysipelas, 89
bullosum, migrans, 89
perstans faciei, 188
prognosis of, 90
recurrence of, in lupus, 205
salutaire, 90
treatment of, 91
Erythema, 60
annulare, 61
bullosum, Pls. 6, 7
caloricum, 64
causes of, 63
congestivum, 58
contusiforme, 63
et papulatum, Pl. 9
exsudativum, Pl. 8
figuratum, 61
gyratum, 61
hemorrhagic, 72
induratum, 212
iris, 61
multiforme, 60; Pl. 5
bullosum, 61
nodosum, 62
papulatum, 61
rheumatoid, 62
scarlatiniforme recidivans, 95
serum, 65
solare, 64
toxic, 65
treatment of, 64
vesiculosum, 61
Erythrasma, 251
treatment of, 252
Erythrodermia exfoliativa universalis tuberculosa, 212
Erythrodermie pityriasiques en plaques disseminées, 97
Erythromelalgia, 65
treatment of, 66
Erythromelia, 185
Esthiomene, 182
Exanthem, 29
Exanthema bullosum neuropathicum, 100; Pl. 18
Exfoliative erythrodermias, 95
Eyelids, lupus of, 204

Face, acute eczema of, 137
chronic eczema of, 139
Facies leonina, 217
Fats, 31
Favus, 239; Pl. 102
of nails, 240
treatment of, 243
treatment of, 241
Favus-fungus, Pl. 115 *e*
Feet, hyperidrosis of, 35
Fibroma, 191
hard, 192
molluscum seu pendulum, 191
treatment of, 192
Filaria medinensis, 258
Fingers, dead, 58
Fish-skin disease, 157
Fissures, 28
Flores unguium, 169
Folliclis, 209; Pl. 80
Folliculitis barbæ, 51
decalvans, 164
Foot, Madura, 224
perforating ulcer of, 78
Fowler's solution in psoriasis, 123
Fox's disease, 160
Freckles, 172
treatment of, 172
Frost bite, 86
treatment of, 87
Fungus cutis, 209
favus-, Pl. 115 *e*
ray-, Pl. 115 *a*
ringworm-, Pl. 115 *c*
tinea-versicolor, Pl. 115 *f*
Furuncle, treatment of, 93
Furunculosis, 92; Pl. 34
Furunculus, 92
compositus, 94
treatment of, 93

Gangræna diabetica bullosa serpiginosa, 75
Gangrene, hysteric, 78
marasmic, 76
multiple cachectic, 76

Gangrene, multiple neurotic, 78
neurotic, 77
senile, 76
symmetric, 77
Gangrenous genital ulcers, 79
Gelatin paste, 33
Genitals, eczema of, 140
acute, 137
herpes of, 105
ulcers of, gangrenous, 79
Glanders, 94
treatment of, 95
Granuloma fungoïdes, 226
d'emblée, 227
treatment of, 228
Graying of hair, 167
Gumma urethræ, 182
Gyri, 29

Hair, 20
anomalies of, 164
bulb, 20
changes in structure of, 166
graying of, 167
inner root-sheath of, 21
outer root-sheath of, 21
root, 20
shaft, 20
spindle, 167
Hair-follicle, 20
mite, Pl. 114 *i*
Hands, acute eczema of, 137
eczema of, 140
Harlequin fetus, 159
Harvest bug, 258
Head louse, Pl. 114 *b*
Heat rash, 36
Heat-sense, 24
Hebra's spiritus saponatus kalinus, 32
Hematidrosis, 37
Hemophilia, 75
Hemorrhagic erythema, 72
purpura, 73
Herpes circinatus, 61
facialis et progenitalis, 104
treatment of, 106
idiopathic, 105
genital, 105
iris, 61
Herpes præputialis, 105
pyæmicus, 110
tonsurans, 243
disseminatus, 245
maculosus et squamosus, Pl. 103
orbicularis, Pls. 104, 106
vesiculosus, Pl. 105
zoster, 100
cervicalis, Pl. 21
faciei et capillitii, 102
sacrolumbalis hæmorrhagicus et gangrænosus, Pl. 19
supraorbital and palpebral, Pl. 20
treatment of, 104
Hirsuties, 167
Hydrocystoma, 38
Hyperchromatosis arsenicalis, 176; Pl. 68
Hyperemia of skin, 58
Hyperidrosis, 35
general, 36
of feet, 35
of palms, 36
palmarum et plantarum, 35
treatment of, 38
universal, 36
Hyperkeratoses, 28
Hyperkeratosis, arsenical, 177
palmaris, Pl. 61
subungualis, 169
Hypertrichosis, 167
Hyponychium, 21
Hysteric gangrene, 78

Ichthyosis, 28, 157; Pl. 58
congenita, 159
et atrophia universalis, Pl. 60
hystrix, 157; Pl. 58
sebacea, 40
serpentina, 157; Pl. 59
simplex, 157
treatment of, 158
Idiopathic herpes facialis, 105
Impetigo, 28
contagiosa, 108
annularis, 108
circinata, 108
serpiginosus, 108

Impetigo, contagiosa, treatment of, 108
herpetiformis, 109; Pls. 22, 23, 24
etiology of, 110
prognosis of, 109
treatment of, 110
simplex, 107
Inflammatory dermatoses, 60
Iodid acne, 47
Iodin, eruptions from, 71
Iododerma tuberosum, 47
Itch, barber's, 248
Itch-mite, Pl. 114 *g*, *h*
egg, Pl. 114 *f*
Ixodes ricinus, 258

Jarisch's disease, 232

Kaposi's disease, 159 230
Keloid, scar, 180
true, 181
Keratohyalin, 18
Keratolysis, 98
treatment of, 98
Keratoma hereditarium palmare et et plantare, 161
Keratosis nigricans, 159
universalis congenita, 159
Koilonychia, 169
Kraursosis vulvæ, 184

Lassar's paste, 34
Lentigo, 172
Leontiasis, 182
Lepra, 215; Pls. 94, 95, 96
anæsthetica seu nervosa, 216, 218
cells, 221
globi, 221
lazarina, 222
mutilans, 220
tuberosa, 216
Leproide, 218
Leprosy, 215
anesthetic, 216, 218
course of, 222
etiology of, 221
nerve, 216
treatment of, 223
tubercular, 216
Leptus autumnalis, 258
Leuconychia striata, 169
Leukemia, 228
treatment of, 230
Leukoderma, 171
acquisitum, 171
syphiliticum, 171
Lice, 259
chicken, 261
Lichen, 127
lividus, 133
moniliformis, 130
pilaris, 159; Pl. 57
planus, 129
diagnosis of, 131
ruber acuminatus, 127
planus, 129; Pl. 46
scrofulosorum, 132
treatment of, 133
treatment of, 131
urticatus, 150
Linear nevus, 179
Lipoma, 192
treatment of, 192
Lips, eczema of, 140
Livedo, 59
Liver spots, 250
Locality sense, 24
Louse, bird, 258
body, 259; Pl. 114 *c*
clothing, 259; Pl. 114 *c*
crab, Pl. 114 *d*
head, Pl. 114 *b*
Lupus, 200, Pls. 87, 88
disseminatus follicularis, 202
elephantiasticus, 205
erythematodes discoides, 187
disseminatus, 209; Pl. 79
nasi, Pl. 78
erythematosus, 187
acute disseminated type, 187
discoid type, 187
disseminatus, 188
etiology of, 189
treatment of, 190
exulcerans, 203; Pl. 82
hypertrophicus faciei, Pl. 89
miliaris, 202
of eyelids, 204
papillaris hypertrophicus, 202

Lupus sclerosus, 261
serpiginosus, 202
syphiliticus, 205
tumidus, 202; Pl. 86
verrucosus, 202
vulgaris, 200; Pl. 71
course of, 204
recurrence of erysipelas in, 205
serpiginosus, Pl. 81
Lymph vessels of skin, 22
Lymphangioma, 196
tuberosum multiplex, 196
Lymphodermia perniciosa, 230

Maculæ cæruleæ, 260; Pl. 113
Macules, 27
Madura foot, 224
Mal del sole, 69
Mal rosso, 69
Malignant growths, 225
pustule, 94
Marasmic gangrene, 76
Melanodermic conditions in diabetes mellitus, 174
Melanoicterus, 174
Melanosarcoma, 233
Melanosis, arsenical, 176
Melasma, 174
Menopon pallidum, 261
Mercury, eruptions from, 71
Microsporon Audonini, 244
furfur, Pl. 115 f
Miliaria alba, 36
crystallina, 36
epidemica, 37
rubra, 36
Miliary tuberculosis of skin, 207
Milium, 43; Pl. 2
colloid, 202
Mite, hair-follicle, Pl. 114 *i*
itch-, Pl. 114, *g*, *h*
Mollin, 31
Mollusca atheromatosa, 41
Molluscum body, Pl. 115, *b*
contagiosum, 44
treatment of, 45
epitheliale, 44
corpuscle, Pl. 115 *b*
verrucosum, 44
Morbus Addisonii, 175
maculosus Werlhofii, 73
Morphea, 162
Multiple cachetic gangrene, 76
neurotic gangrene, 78
Mycetoma pedis, 224
Mycosis fungoïdes, 229
Myiasis dermatosa œstrosa, 260
externa, 259
Myxedema, 183

Nævi vasculosi, 27
Nævus lipomætodes, 178
mollusciformis, 178
pigmentosus, 172
unilateralis, Pl. 67
spilus, 178
vascularis, Pls. 76, 77
vasculosus, 195
verrucosus, 179; Pl. 70
Nail, 21
absence of, 169
anomalies of, 168
bed, 21
body, 21
favus of, 240
treatment of, 243
furrow, 21
matrix of, root, 21
white spots on, 169
Neoplasms, 178
Nerve leprosy, 216
nevi, 179
Nerves of skin, 22
Neurofibromata, 191
Neuroses, 151
Neurotic gangrene, 77
multiple, 78
Nevi, 178
nerve, 179
Nevus, etiology of, 178
linear, 179
systematized, 179
treatment of, 179
New growths, 178
Nits, Pl. 114 *a*
Noma, 80

Œdema cutis circumscriptum, 68
Œstridæ, 260

Onychia et paronychia trychophytica, Pl. 107
Onychias, syphilitic, 170
Onychogryposis, 169
  trichophytina, 247
Onychomycosis favosa, 240
  trichophytina, 247
Onychorrhexis, 169
Onychoschisis symmetrica, 169
Osmidrosis, 36

Pachydermia, 181
Paget's disease, 237
  treatment of, 238
Pain, sense of, 24
Paleness of skin, 170
Palms, hyperidrosis of, 36
Panaritium tuberculosum, Pl. 91
Papillary body, 18
  layer, 18
Papules, 27
Papulosquamous syphiloderm, 131
Parakeratoses, 28
Parakeratosis variegata, 97
Paraplasters, 34
Parapsoriasis, 97
Parasites, animal, 254
  vegetable, 239
Parasitic diseases, 239
  sycosis, 248
Parchment skin, 185
Paronychias, syphilitic, 170
Pars papillaris, 18
  reticularis, 19
Paste, gelatin, 33
  Lassar's, 34
Pastes, 34
Pediculosis, 259
  capitis seu capillitii, 259
  corporis seu vestimenti, 259
  pubis, 260
Peliosis, 72
Pellagra, 69, 174
  causes of, 69
  course of, 69
  treatment of, 70
Pemphigus, 110
  circinatus, 111
  crouposus, 111
  etiology of, 115
Pemphigus foliaceus, 112
  framboesioides, 113
  gyratus, 111
  neonatorum sive contagiosus, 106
    treatment, 107
  prognosis of, 114
  pruriginosus, 111
  serpiginosus, 111
  treatment of, 116
  vegetans, 113; Pls. 26, 27
  vulgaris, 110
    benignus, 112
    diutinus, 112; Pl. 25
Penis, carcinoma of, Pls. 100, 101
Perforating ulcer of foot, 78
Perniones, 86
Petechiæ, 27
Phlegmon, 90; Pls. 87, 88
Piedra, 252
Pigment anomalies of skin, 170
Pigmentation, increase in, 172
Pityriasis capitis treatment, 42
  lichenoides chronica, 97
  maculata et circinata, 245, 248
  rosea, 248
  rubra, 95, 96
    pilaris, 128
  versicolor, Pl. 109
Plasters, 34
Platyonychia hereditaria, 169
Plica polonica, 139
Poliosis, 167
Pompholyx, 37; Pl. 1
Postmortem tubercle, 208
Potassium iodid in psoriasis, 124
Powders, 34
Premature alopecia, 164
Pressure sense, 24
Prickly heat, 36
Prurigo, 147; Pl. 56
  agria, 148
  diagnosis of, 149
  ferox, 148
  mitis, 148
  treatment of, 149
Pruritus, 151
  ani, 153
  cutaneus, 151
    senilis, 152
  hiemalis, 154

Pruritus localis, 151
pudendorum, 153
scroti, 153
treatment of, 152, 154
universalis, 151
vulvæ, 153
Pseudoerysipelas, 90
Pseudoleukemia, 228, 230
treatment of, 230
Psoriasis, 116
annularis, 118; Pls. 40, 41
serpiginosa, Pl. 42
arsenic in, 123
Asiatic pills in, 123
atypical forms of, 120
chrysarobin in, 125
circinata, 118
confluens figurata, 117
diagnosis of, 119
diffusa universalis, 118
dot, 118
etiology of, 121
Fowler's solution in, 123
guttata, 117
gyrata, 118
nummularis, 117
ostreacea, 121
potassium iodid in, 124
prognosis of, 122
punctata, 117
pyrogallic acid in, 125
Röntgen-ray treatment of, 126
sulphur in, 126
syphiliticus, 131
tar preparations in, 124
thyroid preparations in, 124
treatment of, 123, Pls. 39, 43, 44, 45
vulgaris confluens, Pl. 36
nummularis et scutata, Pls. 37, 38
punctata et guttata, Pl. 35
Psorospermosis follicularis vegetans, 160
Pulex irritans, 260
penetrans, 258
Purpura, 27; Pls. 10, 11
factitia, 74
hæmorrhagica, 73
papulosa, 73
Purpura papulosa et bullosa, 72; Pls. 13, 14
rheumatica, 72
fulminans, 72; Pl. 12
senilis, 72
treatment of, 74
Pustula maligna, 94
Pustules, 28
Pyrogallic acid in psoriasis, 125

Quinia, eruptions from, 71

Radix pili, 20
Ray-fungus, Pl. 115 *a*
Raynaud's disease, 77; Pls. 28, 29
Resorbin, 31
Respiratory function of skin, 25
Rete malpighii, 17
Rheumatic purpura, 72
Rheumatoid erythema, 62
Rhinophyma, 55
Rhinoscleroma, 197
Ringworm, 243
fungus, Pl. 115 *c*
treatment of, 249
Ritter's dermatitis exfoliativa neonatorum, 98
Röntgen rays, effect on skin, 65
Rodent ulcer, 234
Roseola, 27
Rupia, 28

Salve, cooling, 32
mulls, 32
pencils, 32
Sarcoid growths, 225
Sarcoma, 233
idiopathicum hæmorrhagicum, 230
Sarcomatis cutis, 232
Scabies, 254
pustulosa, Pls. 111, 112
treatment of, 255
Scabrities unguium syphilitica, 170
Scales, 28
chronic pustular eczema of, 139
Scar, 29, 180
atrophic, 29
keloid, 180
Schizonychia, 169

Sclerema adiposum, 163
neonatorum, 163
Sclerodactylia, 162
Scleroderma, 162
Scleronychia, 169
Scorbutus, 74
treatment of, 74
Scrofuloderma, 206
Scrotum, pruritus of, 153
Scurvy, 74
Seaman's skin, 186
Sebaceous glands, disorders of, 40
Seborrhea, 40
congestiva, 187
Seborrhœa oleosa, 40
sicca seu squamosa, 40
treatment of, 42
Sebum, 25
Senile degeneration of skin, 26
gangrene, 76
Senilitas cutis præcox, 185
Sense, cold-, 24
heat-, 24
locality, 24
of pain, 24
of touch, 24
pressure, 24
skin as organ of, 23
space, 24
Serum erythema, 65
Skin, anatomy of, 17
anemia of, 57
anesthesia of, 154
as organ of sense, 23
blood-vessels of, 22
color of, 19
diseases of, mechanical and physical methods of treatment, 85
treatment, 30
effect of Röntgen rays on, 65
hyperemia of, 58
lymph vessels of, 22
nerves of, 22
pathology of, 26
physiology of, 23
respiratory function of, 25
senile degeneration of, 26
Soaps, 32
Space sense, 24
Spiegler's disease, 232
Spindle hairs, 167
Spiritus saponatus kalinus, 32
Squamæ, 28
Squamous dermatoses, 116
Stomonyidæ, 260
Stratum corneum, 17
reticulare corii, 19
Streptothrix maduræ, 225
Striæ atrophicæ, 183
gravidarum, 183
Strophulus, 150
Subcutis, 19
Sulcus unguis, 21
Sulphur in psoriasis, 126
Sweat, 25
as heat-regulating factor, 26
glands, 21
disorders of, 35
Sycosis, 51
framboësioides, Pl. 108
parasitic, 248
treatment of, 53
vulgaris, 51
Symmetric gangrene, 77
Syphilis after alopecia, 165
Syphilitic lesions in lupus, 205
leukoderma, 171
onychias, 170
paronychias, 170
Syphiloderm, papulosquamous, 131
Syphilonychia ulcerosa hereditaria, 170
Syringomyelia, 77

Tænia echinococcus, 257
Tar preparations in psoriasis, 124
Telangiectases, 27, 195
Thinning of skin, 183
Thyroid preparations in psoriasis, 124
Tilbury Fox's disease, 108
Tinctura saponis viridis, 33
Tinea circinata, 244
favosa, 239
treatment of, 241
imbricata, 247
kerion, 248
sycosis, 248
tonsurans, 247

Tinea trichophytina, 243
capitis, 247
corporis, 244
versicolor, 250
fungus of, Pl. 115 *f*
Touch papillæ, 19
sense of, 24
Toxic acne eruptions, 47
erythema, 65
Traumatic alopecia, 164
chloasma, 172
Trichoepithelioma papulatum multiplex, 232
Trichomycosis capillitii, 252
palmellina, 252
Trichophyton, 244; Pl. 115 *c*
Trichophytosis, 243; Pl. 107
Trichoptilosis, 167
Trichorrhexis nodosa, 166
microscopic picture of hair in, Pl. 115 *d*
Trophoneuroses, 151
True keloid, 181
Tubercle, postmortem, 208
Tubercular leprosy, 216
Tuberculide, 209
Tuberculides acnéiformes et nécrotiques, Pl. 80
Tuberculosis, chronic, of hand, Pl. 83
of skin of leg, Pl. 86
cutis, Pl. 92
colliquativa, 206
fungosa, 209
miliary, of skin, 207
subacuta mucosæ oris, Pl. 90
ulcerosa cutis, 207
verrucosa cutis, 208; Pl. 93
Tuberculous diseases of skin, 198
treatment, 212
ulcer, 207
of hand, Pls. 84, 85
Turpentine, eruptions from, 71
Tyloma, 154
Tylosis palmaris et plantaris, 130

Ulcer, 28
gangrenous genital, 79
of foot, perforating, 78
rodent, 234
Ulcer, tuberculous, 207
of hand, Pls. 84, 85
Ulcus chronicum vulvæ, 182
Unguentum caseini Unna, 33
Unna-Beiersdorf gutta-percha plaster mulls, 34
Urethra, gumma of, 182
Uridrosis, 37
Urtica, 27
Urticaria, 66
bullosa, 67
factitia, 67
papulosa, 66, 150
papulovesiculosa, 66
pigmentosa, 67
treatment of, 68
vesiculosa, 66

Vagabond's disease, 174
Varnishes, 33
Vegetable parasites, 239
Vernix caseosa, 40
Verruca, 156
Vesicles, 27
Vesicular eruptions, 100
Vibices, 27
Vitiligo, 172; Pl. 66
Vitiligoidea, 193
Vox rauca leprosorum, 217
Vulva, kraurosis of, 184
pruritus of, 153

Warts, 156
Water, 31
Wheal, 27
White spots on nails, 169
Whitening of skin, 170

Xanthelasma, 193
Xanthoma, 193
etiology of, 194
planum, 193
treatment of, 194
tuberosum, 193; Pls. 74, 75
Xeroderma, 185
pigmentosum, 185
treatment of, 186

Zoster gangrænosus, 101
hæmorrhagicus, 101

SAUNDERS' MEDICAL HAND-ATLASES

A SERIES OF BOOKS OFFERING
A SATISFACTORY SUBSTITUTE FOR ACTUAL CLINICAL WORK

SPECIAL OFFER

AS it is impossible to realize the beauty and cheapness of these atlases without an opportunity to examine them, we make the following offer: Any one of these books will be sent to physicians, carriage prepaid, upon request. If you want the book, you have merely to remit the price; if not, return the book by mail.

A Descriptive Catalogue of all our Publications Sent on Request

W. B. SAUNDERS & COMPANY

925 Walnut Street **Philadelphia**

LONDON: 9, Henrietta Street, Covent Garden

SAUNDERS' MEDICAL HAND-ATLASES

IN planning this series of books arrangements were made with representative publishers in the chief medical centers of the world for the publication of translations of the atlases in thirteen different languages, the lithographic plates for all being made in Germany, where work of this kind has been brought to the greatest perfection. The enormous expense of making the plates being shared by the various publishers, the cost to each one was reduced approximately to one-tenth. Thus, by reason of their **universal translation** and reproduction, affording international distribution, the publishers have been enabled to secure for these atlases the **best artistic** and **professional talent,** to produce them in the **most elegant style,** and yet to offer them at a **price heretofore unapproached in cheapness.**

Moderate Price

One of the most valuable features of these atlases is that they offer a **ready and satisfactory substitute for clinical observation.** Such observation, of course, is available only to the residents in large medical centers; and even then the requisite variety is seen only after long years of routine hospital work. To those unable to attend important clinics these books will be absolutely indispensable, as presenting in a complete and convenient form the most accurate reproductions of clinical work, interpreted by the most competent of clinical teachers.

Substitute for Clinical Observation

As an indication of the great practical value of the atlases and of the immense favor with which they have been received, it should be noted that the **Medical Department of the U. S. Army** has adopted the "Atlas of Operative Surgery" as its standard, and has ordered the book in large quantities for distribution to the various regiments and army posts.

Adopted by U. S. Army

Sobotta and Huber's Human Histology

Atlas and Epitome of Human Histology. By Pr. Dr. J. Sobotta, of Würzburg. Edited, with additions, by G. Carl Huber, M. D., Professor of Histology and Embryology, University of Michigan, Ann Arbor. With 214 colored figures on 80 plates, 68 text-cuts, and 248 pages of text. Cloth, $4.50 net.

This work combines an abundance of well chosen and most accurate illustrations with a concise text, and in such a manner as to make it both atlas and text-book. The colored lithographic plates have been produced with the aid of over thirty colors, and particular care was taken to avoid distortion and assure exactness of magnification

Boston Medical and Surgical Journal

"In color and proportion they are characterized by gratifying accuracy and lithographic beauty. . . . May be highly recommended to those who are without access to histologic collections."

Haab *and* de Schweinitz's Operative Ophthalmology

Atlas and Epitome of Operative Ophthalmology. By Dr. O. Haab, of Zürich. Edited, with additions, by George E. de Schweinitz, M. D., Professor of Ophthalmology in the University of Pennsylvania. With 30 colored lithographic plates, 154 text-cuts, and 377 pages of text. Cloth, $3.50 net.

JUST ISSUED

This new volume forms an admirable conclusion of the series of atlases on the Eye prepared by Professor Haab. Operations are described with all the fidelity and clearness that thirty years' conscientious practice in eye work naturally brings. The colored illustrations exhibit the same perfection of art and accurateness of detail which are found only in this invaluable series of atlases.

Grünwald and Newcomb's Mouth, Pharynx, Nose

Atlas and Epitome of Diseases of the Mouth, Pharynx, and Nose. By Dr. L. Grünwald, of Munich. *From the Second Revised and Enlarged German Edition.* Edited, with additions, by James E. Newcomb, M. D., Instructor in Laryngology, Cornell University Medical School; Attending Laryngologist to the Roosevelt Hospital, Out-Patient Department. With 102 illustrations on 42 colored lithographic plates, 41 text-cuts, and 219 pages of text. Cloth, $3.00 net.

INCLUDING ANATOMY AND PHYSIOLOGY

In designing this atlas the needs of both student and practitioner were kept constantly in mind, and as far as possible typical cases of the various diseases were selected. The illustrations are described in the text in exactly the same way as a practised examiner would demonstrate the objective findings to his class, the book thus serving as a substitute for actual clinical work. The illustrations themselves are numerous and exceedingly well executed, portraying the conditions so strikingly that their study is almost equal to examination of the actual specimens. The editor has incorporated his own valuable experience, including notes on the use of the active principle of the suprarenal bodies.

OPINIONS OF THE MEDICAL PRESS

American Medicine

"Its conciseness without sacrifice of clearness and thoroughness, as well as the excellence of text and illustration are commendable."

Journal of Ophthalmology, Otology, and Laryngology

"A collection of the most naturally colored lithographic plates that has been published in any book in the English language. . . . Very valuable alike to the student, the practitioner, and the specialist."

Each volume contains from 50 to 100 colored plates

Helferich and Bloodgood's Fractures and Dislocations

Atlas and Epitome of Traumatic Fractures and Dislocations. By PROFESSOR DR. H. HELFERICH, Professor of Surgery at the Royal University, Greifswald, Prussia. Edited, with additions, by JOSEPH C. BLOODGOOD, M. D., Associate in Surgery, Johns Hopkins University, Baltimore. *From the Fifth Revised and Enlarged German Edition.* With 216 colored illustrations on 64 lithographic plates, 190 text-cuts, and 353 pages of text. Cloth, $3.00 net.

SHOWING DEFORMITY, X-RAY SHADOW, AND TREATMENT

This department of medicine being one in which, from lack of practical knowledge, much harm can be done, and in which in recent years great importance has obtained, a book, accurately portraying the anatomic relations of the fractured parts, together with the diagnosis and treatment of the condition, becomes an absolute necessity. This present work fully meets all requirements. As complete a view as possible of each case has been presented, thus equipping the physician for the manifold appearances that he will meet with in practice. The illustrations show the visible external deformity, the X-ray shadow, the anatomic preparation, and the method of treatment.

OPINIONS OF THE MEDICAL PRESS

Medical News, New York

"This compact and exceedingly attractive little volume will be most welcome to all who are interested in the practical application of anatomy. The author and editor have made a most successful effort to arrange the illustrations that the interpretation of what they are intended to present is exceedingly easy."

Brooklyn Medical Journal

"There are few books published that better answer the requirements for illustration than this work of Professor Helferich. . . . Such a collection of illustrations must be the result of much labor and thought."

Sultan and Coley's Abdominal Hernias

Atlas and Epitome of Abdominal Hernias. By PRIVATDOCENT DR. GEORG SULTAN, of Göttingen. Edited, with additions, by WILLIAM B. COLEY, M. D., Clinical Lecturer on Surgery, Columbia University (College of Physicians and Surgeons), New York. With 119 illustrations, 36 of them in colors, and 277 pages of text. Cloth, $3.00 net.

DEALING WITH THE SURGICAL ASPECT

This new atlas covers one of the most important subjects in the entire domain of medical teaching, since these hernias are not only exceedingly common, but the frequent occurrence of strangulation demands extraordinarily quick and energetic surgical intervention. During the last decade the operative side of this subject has been steadily growing in importance, until now it is absolutely essential to have a book treating of its surgical aspect. This present atlas does this to an admirable degree. The illustrations are not only very numerous, but they excel, in the accuracy of the portrayal of the conditions represented, those of any other work upon abdominal hernias with which we are familiar. The work will be found a worthy exponent of our present knowledge of the subject of which it treats.

PERSONAL AND PRESS OPINIONS

Robert H. M. Dawbarn, M. D.,

Professor of Surgery and Surgical Anatomy, New York Polyclinic.

"I have spent several interested hours over it to-day, and shall willingly recommend it to my classes at the Polyclinic College and elsewhere."

Boston Medical and Surgical Journal

"For the general practitioner and the surgeon it will be a very useful book for reference. The book's value is increased by the editorial notes of Dr. Coley."

They have already appeared in thirteen different languages

Brühl, Politzer, and MacCuen Smith's Otology

Atlas and Epitome of Otology. By GUSTAV BRÜHL, M. D., of Berlin, with the collaboration of Professor DR. A. POLITZER, of Vienna. Edited, with additions, by S. MACCUEN SMITH, M. D., Professor of Otology in the Jefferson Medical College, Philadelphia. With 244 colored figures on 39 lithographic plates, 99 text-illustrations, and 292 pages of text. Cloth, $3.00 net.

INCLUDING ANATOMY AND PHYSIOLOGY

This excellent volume is the first attempt to supply in English an illustrated clinical handbook to act as a worthy substitute for personal instruction in a specialized clinic. This work is both didactic and clinical in its teaching, the latter aspect being especially adapted to the student's wants. A special feature is the very complete exposition of the minute anatomy of the ear, a working knowledge of which is so essential to an intelligent conception of the science of otology. The illustrations are beautifully executed in colors, and illuminate the text in a singularly lucid manner, portraying pathologic changes with such striking exactness that the student should receive a deeper and more lasting impression than the most elaborate description could produce. Further, the association of Professor Politzer in the preparation of the work, and the use of so many valuable specimens from his notably rich collection especially enhance the value of the work. The text contains everything of importance in the elementary study of otology.

PERSONAL AND PRESS OPINIONS

Clarence J. Blake, M. D.,

Professor of Otology, Harvard University Medical School, Boston.

"The most complete work of its kind as yet published, and one commending itself to both the student and teacher in the character and scope of its illustrations."

Boston Medical and Surgical Journal

"Contains what is probably the best collection of colored plates of the ear, both of normal and pathological conditions, of any hand-book published in the English language. In addition to this the text is presented in an unusually clear and direct manner."

They are offered at a price heretofore unapproached in cheapness

Lehmann, Neumann, and Weaver's Bacteriology

Atlas and Epitome of Bacteriology: INCLUDING A TEXT-BOOK OF SPECIAL BACTERIOLOGIC DIAGNOSIS. By PROF. DR. K. B. LEHMANN and DR. R. O. NEUMANN, of Würzburg. *From the Second Revised and Enlarged German Edition.* Edited, with additions, by G. H. WEAVER, M. D., Assistant Professor of Pathology and Bacteriology, Rush Medical College, Chicago. In two parts. Part I.—632 colored figures on 69 lithographic plates. Part II.—511 pages of text, illustrated. Per part: Cloth, $2.50 net.

INCLUDING SPECIAL BACTERIOLOGIC DIAGNOSIS

This work furnishes a survey of the properties of bacteria, together with the causes of disease, disposition, and immunity, reference being constantly made to an appendix of bacteriologic technic. The special part gives a complete description of the important varieties, the less important ones being mentioned when worthy of notice. The lithographic plates, as in all this series, are accurate representations of the conditions as actually seen, and this collection, if anything, is more handsome than any of its predecessors. As an aid in original investigation the work is invaluable.

OPINIONS OF THE MEDICAL PRESS

American Journal of the Medical Sciences

"Practically all the important organisms are represented, and in such a variety of forms and cultures that any other atlas would rarely be needed in the ordinary hospital laboratory."

The Lancet, London

"We have found the work a more trustworthy guide for the recognition of unfamiliar species than any with which we are acquainted."

There have been 82,000 copies imported since publication

Zuckerkandl and DaCosta's Operative Surgery

Second Edition, Revised and Greatly Enlarged

Atlas and Epitome of Operative Surgery. By Dr. O. Zuckerkandl, of Vienna. Edited, with additions, by J. Chalmers DaCosta, M. D., Professor of the Principles of Surgery and Clinical Surgery, Jefferson Medical College, Philadelphia. With 40 colored plates, 278 text-cuts, and 410 pages of text. Cloth, $3.50 net.

ADOPTED BY THE U. S. ARMY

In this new edition the work has been brought precisely down to date. The revision has not been casual, but thorough and exhaustive, the entire text having been subjected to a careful scrutiny, and many improvements and additions made. A number of chapters have been practically rewritten, and of the newer operations, all those of special value have been described. The number of illustrations has also been materially increased. Sixteen valuable lithographic plates in colors and sixty-one text-figures have been added, thus greatly enhancing the value of the work. There is no doubt that the volume in its new edition will still maintain its leading position as a substitute for clinical instruction.

OPINIONS OF THE MEDICAL PRESS

Philadelphia Medical Journal

"The names of Zuckerkandl and DaCosta, the fact that the book has been translated into 13 different languages, together with the knowledge that it is used in the United States Army and Navy, would be sufficient recommendation for most of us."

Munchener Medicinische Wochenschrift

"We know of no other work that combines such a wealth of beautiful illustrations with clearness and conciseness of language, that is so entirely abreast of the latest achievements, and so useful both for the beginner and for one who wishes to increase his knowledge of operative surgery."

Each volume is edited, with additions, by a leading specialist

Dürck and Hektoen's General Pathologic Histology

Atlas and Epitome of General Pathologic Histology. By Pr. Dr. H. Dürck, of Munich. Edited, with additions, by Ludvig Hektoen, M. D., Professor of Pathology, Rush Medical College, Chicago. 172 colored figures on 77 lithographic plates, 36 text-cuts, many in colors, and 453 pages of text. $5.00 net.

JUST ISSUED

This new atlas gives the accepted views in regard to the significance of pathologic processes. All the illustrations have been made from original specimens without combining different microscopic fields. Extraordinary care has been taken to reproduce them as near perfection as possible, in many cases twenty-six colors being required.

Dürck and Hektoen's Special Pathologic Histology

Atlas and Epitome of Special Pathologic Histology. By Dr. H. Dürck, of Munich. Edited, with additions, by Ludvig Hektoen, M. D., Professor of Pathology, Rush Medical College, Chicago. In Two Parts. Part I.—Circulatory, Respiratory, and Gastro-intestinal Tracts. Part II.—Liver, Urinary and Sexual Organs, Nervous System, Skin, Muscles, and Bones. 243 colored figures on 122 plates, and 350 pages of text. Per part: Cloth, $3,00 net.

William H. Welch, M. D.,

Professor of Pathology, Johns Hopkins University, Baltimore.

"I consider Dürck's 'Atlas of Special Pathologic Histology,' edited by Hektoen, a very useful book for students and others The plates are admirable."

They represent the best artistic and professional talent

Haab and deSchweinitz's Ophthalmoscopy

Atlas and Epitome of Ophthalmoscopy and Ophthalmoscopic Diagnosis. By DR. O. HAAB, of Zürich. *From the Third Revised and Enlarged German Edition.* Edited, with additions, by G. E. DESCHWEINITZ, M. D., Professor of Ophthalmology, University of Pennsylvania. With 152 colored lithographic illustrations; 85 pages of text. Cloth, $3.00 net.

Not only is the student made acquainted with carefully prepared ophthalmoscopic drawings done into well-executed lithographs of the most important fundus changes, but, in many instances, plates of the microscopic lesions are added. It furnishes a manual of the greatest possible service.

The Lancet, London

"We recommend it as a work that should be in the ophthalmic wards or in the library of every hospital into which ophthalmic cases are received."

Haab and deSchweinitz's External Diseases of Eye

Atlas and Epitome of External Diseases of the Eye. By DR. O. HAAB, of Zürich. Edited, with additions, by G. E. DESCHWEINITZ, M. D., Professor of Ophthalmology, University of Pennsylvania. 98 colored illustrations on 48 lithographic plates and 232 pages of text. Cloth, $3.00 net.

SECOND REVISED EDITION—RECENTLY ISSUED

In this thorough revision the text has been brought up to date by the addition of new matter, including references to some of the modern therapeutic agents. There have also been added eight chromolithographic plates.

The Medical Record, New York

"The work is excellently suited to the student of ophthalmology and to the practising physician. It cannot fail to attain a well-deserved popularity." (Review of previous ed.)

They are convenient in size and uniformly bound

Schäffer *and* Edgar's Labor *and* Operative Obstetrics

Atlas and Epitome of Labor and Operative Obstetrics. By Dr. O. Schäffer, of Heidelberg. *From the Fifth Revised and Enlarged German Edition.* Edited, with additions, by J. Clifton Edgar, M. D., Professor of Obstetrics and Clinical Midwifery, Cornell University Medical School. 14 lithographic plates in colors; 139 other cuts; 111 pages of text. $2.00 net.

The book presents the act of parturition and the various obstetric operations in a series of easily understood illustrations. These are accompanied by a text that treats the subject from a practical standpoint.

Dublin Journal of Medical Science, Dublin

"One fault Professor Schäffer's Atlases possess. Their name, and the extent and number of the illustrations, are apt to lead one to suppose that they are merely 'atlases,' whereas the truth really is they are also concise and modern epitomes of obstetrics."

Schäffer & Edgar's Obstetric Diagnosis and Treatment

Atlas and Epitome of Obstetric Diagnosis and Treatment. By Dr. O. Schäffer, of Heidelberg. *From the Second Revised German Edition.* Edited, with additions, by J. Clifton Edgar, M. D., Professor of Obstetrics and Clinical Midwifery, Cornell University Medical School. 122 colored figures on 56 plates; 38 other cuts; 315 pages of text. $3.00 net.

This book treats particularly of obstetric operations, and, besides the wealth of beautiful lithographic illustrations, contains an extensive text of great value. This text deals with the practical, clinical side of the subject.

New York Medical Journal

"The illustrations are admirably executed, as they are in all of these atlases, and the text can safely be commended, not only as elucidatory of the plates, but as expounding the scientific midwifery of to-day."

These are the famous "Lehmann medicinische Handatlanten"

Mracek and Stelwagon's Skin

Atlas and Epitome of Diseases of the Skin. By PROF. DR. FRANZ MRACEK, of Vienna. Edited, with additions, by HENRY W. STELWAGON, M. D., Professor of Dermatology in the Jefferson Medical College, Philadelphia. With 77 colored plates, 50 half-tone illustrations, and 288 pages of text.

JUST ISSUED—NEW (2d) EDITION

This volume, the outcome of years of scientific and artistic work, contains, together with colored plates of unusual beauty, numerous illustrations in black, and a text comprehending the entire field of dermatology. The illustrations are all original and prepared from actual cases in Mracek's clinic.

American Journal of the Medical Sciences

"The advantages which we see in this book and which recommend it to our minds are: First, its handiness; secondly, the plates, which are excellent as regards drawing, color, and the diagnostic points which they bring out. We most heartily recommend it."

Mracek and Bang's Syphilis *and* Venereal Diseases

Atlas and Epitome of Syphilis and the Venereal Diseases. By PROF. DR. FRANZ MRACEK, of Vienna. Edited, with additions, by L. BOLTON BANGS, M. D., late Prof. of Genito-Urinary Surgery, University and Bellevue Hospital Medical College, New York. With 71 colored plates and 122 pages of text. Cloth, $3.50 net.

According to the unanimous opinion of numerous authorities, to whom the original illustrations of this book were presented, they surpass in beauty anything of the kind that has been produced in this field, not only in Germany, but throughout the literature of the world.

Robert L. Dickinson, M. D.,

Art Editor of "The American Text-Book of Obstetrics."

"The book that appeals instantly to me for the strikingly successful, valuable, and graphic character of its illustrations is the 'Atlas of Syphilis and the Venereal Diseases.' I know of nothing in this country that can compare with it."

The lithographs, all made in Germany, are unrivalled

Schäffer and Webster's Operative Gynecology

Atlas and Epitome of Operative Gynecology. By DR. O. SCHÄFFER, of Heidelberg. Edited, with additions, by J. CLARENCE WEBSTER, M. D. (EDIN.), F. R. C. P. E., Professor of Obstetrics and Gynecology in the Rush Medical College, in affiliation with the University of Chicago. With 42 lithographic plates in colors, many text-cuts, a number in colors, and 138 pages of text. Cloth, $3.00 net.

RECENTLY ISSUED

The excellence of the lithographic plates and the many other illustrations in this atlas render it of the greatest value in obtaining a sound and practical knowledge of operative gynecology. Indeed, the artist, the author, and the lithographer have expended much patient endeavor in the preparation of the water-colors and drawings. They are based on hundreds of photographs taken from nature, and they reproduce faithfully and instructively the various situations. The text closely follows the illustrations, and is fully as accurate.

Shäffer and Norris' Gynecology

Atlas and Epitome of Gynecology. By DR. O. SHAFFER, of Heidelberg. *From the Second Revised and Enlarged German Edition.* Edited, with additions, by RICHARD C. NORRIS, A. M., M. D., Gynecologist to Methodist-Episcopal and Philadelphia Hospitals. With 207 colored figures on 90 plates, 65 text-cuts, and 308 pages of text. Cloth, $3.50 net.

The value of this atlas will be found not only in the concise explanatory text, but especially in the illustrations. The large number of colored plates, reproducing the appearance of fresh specimens, will give the student a knowledge of the changes induced by disease that cannot be obtained from mere description.

Bulletin of Johns Hopkins Hospital, Baltimore

"The book contains much valuable material. Rarely have we seen such a valuable collection of gynecological plates."

These books are next best to actual clinical work

Jakob and Eshner's Internal Medicine & Diagnosis

Atlas and Epitome of Internal Medicine and Clinical Diagnosis. By Dr. Chr. Jakob, of Erlangen. Edited, with additions, by Augustus A. Eshner, M. D., Professor of Clinical Medicine in the Philadelphia Polyclinic. With 182 colored figures on 68 plates, 64 illustrations in black and white, and 259 pages of text. Cloth, $3.00 net.

In addition to an admirable atlas of clinical microscopy, this volume describes the physical signs of all internal diseases in an instructive manner by means of fifty colored schematic diagrams. As a means of instruction its value is very great; as a reference handbook it is admirable.

British Medical Journal

"Dr. Jakob's work deserves nothing but praise. The information is accurate and up to present-day requirements."

Grünwald and Grayson's Diseases of the Larynx

Atlas and Epitome of Diseases of the Larynx. By Dr. L. Grünwald, of Munich. Edited, with additions, by Charles P. Grayson, M. D., Clinical Professor of Laryngology and Rhinology, University of Pennsylvania. With 107 colored figures on 44 plates, 25 text-illustrations, and 103 pages of text. Cloth, $2.50 net.

This atlas exemplifies a happy blending of the didactic and clinical, such as is not to be found in any other volume upon this subject. The author has given special attention to the clinical portion of the work, the sections on diagnosis and treatment being particularly full.

The Medical Record, New York

"This is a good work of reference, being both practical and concise. . . . It is a valuable addition to existing laryngeal text-books."

For "Special Offer" regarding these atlases see page 1

Hofmann and Peterson's Legal Medicine

Atlas of Legal Medicine. By DR. E. VON HOFMANN, of Vienna. Edited by FREDERICK PETERSON, M. D., Clinical Professor of Psychiatry, College of Physicians and Surgeons, N. Y. 120 colored figures on 56 plates, 193 text-cuts. $3.50 net.

The Practitioner, London

"The illustrations appear to be the best that have ever been published in connection with this department of medicine, and they cannot fail to be useful alike to the medical jurist and to the student of forensic medicine."

Jakob and Fisher's Nervous System and its Diseases

Atlas and Epitome of the Nervous System and its Diseases. By PROF. DR. CHR. JAKOB, of Erlangen. *From the Second Revised German Edition.* Edited, with additions, by EDWARD D. FISHER, M. D., Professor of Diseases of the Nervous System, University and Bellevue Hospital Medical College, N. Y. 83 plates and copious text. Cloth, $3.50 net.

Philadelphia Medical Journal

"We know of no one work of anything like equal size which covers this important and complicated field with the clearness and scientific fidelity of this hand-atlas."

Golebiewski and Bailey's Accident Diseases

Atlas and Epitome of Diseases Caused by Accidents. By DR. ED. GOLEBIEWSKI, of Berlin. Edited, with additions, by PEARCE BAILEY, M. D., Consulting Neurologist to St. Luke's Hospital and Orthopedic Hospital, N. Y. 71 colored illustrations on 40 plates, 143 text-cuts, 549 pages of text. Cloth, $4.00 net.

Medical Examiner and Practitioner

"It is a useful addition to life-insurance libraries, for lawyers, physicians, and for every one who is brought in contact with the treatment or consideration of accidents or diseases growing out of them, or legal complications flowing from them."

The "Atlas of Operative Surgery" has been adopted by U. S. Army

SAUNDERS' MEDICAL HAND-ATLASES

Atlas and Epitome of External Diseases of the Eye. By DR. O. HAAB, of Zurich. Edited, with additions, by G. E. DE SCHWEINITZ, M.D., Professor of Ophthalmology in the University of Pennsylvania. *Second Revised Edition.* With 98 colored illustrations on 48 plates and 232 pages of text. Cloth, $3.00 net.

"The work is well done, and is valuable to physicians in general, as well as to ophthalmologists. I shall take pleasure in recommending it."—JOHN E. WEEKS, M.D., *Clinical Professor of Ophthalmology, University of Bellevue Hospital Medical School,* N. Y.

Atlas and Epitome of Internal Medicine and Clinical Diagnosis. By DR. CHR. JAKOB, of Erlangen. Edited, with additions, by AUGUSTUS A. ESHNER, M.D., Professor of Clinical Medicine in the Philadelphia Polyclinic. With 179 colored figures on 68 plates and 259 pages of text. Cloth, $3.00 net.

"Dr. Jakob's work deserves nothing but praise. The information is accurate and up to present-day requirements."—*British Medical Journal.*

Atlas of Legal Medicine. By DR. E. VON HOFMANN, of Vienna. Edited, with additions, by FREDERICK PETERSON, M.D., Assistant Professor of Psychiatry, College of Physicians and Surgeons, New York. With 120 colored figures on 56 plates and 193 half-tone illustrations. Cloth, $3.50 net.

"It is rare indeed that so large a series of illustrations are found which demonstrate so well and so accurately the conditions which they are supposed to represent."—*Boston Medical and Surgical Journal*

Atlas and Epitome of Diseases of the Larynx. By DR. L. GRUNWALD, of Munich. Edited, with additions, by CHARLES P. GRAYSON, M.D., Clinical Professor of Laryngology and Rhinology in the University of Pennsylvania. With 107 colored figures on 44 plates, 25 text-illustrations, and 103 pages of text. Cloth, $2.50 net.

"Excels everything we have hitherto seen in the way of colored illustrations of diseases of the larynx."—*British Medical Journal.*

Atlas and Epitome of Operative Surgery. By DR. O. ZUCKERKANDL, of Vienna. *From the Second Revised and Enlarged German Edition.* Edited, with additions, by J. CHALMERS DACOSTA, M.D., Professor of the Principles of Surgery and of Clinical Surgery, Jefferson Medical College, Philadelphia. *Second Edition, Revised and Greatly Enlarged.* With 40 colored plates, 278 text-cuts, and 410 pages of text. Cloth, $3.50 net.

"It may be said that few, if any, books of this description are so comprehensive in their scope."—*Philadelphia Medical Journal.*

Atlas and Epitome of Syphilis and the Venereal Diseases. By PROF. DR. FRANZ MRACEK, of Vienna. Edited, with additions, by L. BOLTON BANGS, M.D., late Professor of Genito-Urinary Surgery, University and Bellevue Hospital Medical College, New York. With 71 colored plates and 122 pages of text. Cloth, $3.50 net.

"A glance through the book is almost like actual attendance upon a famous clinic."—*Journal of the American Medical Association.*

Atlas and Epitome of Skin Diseases. By PROF. DR. FRANZ MRACEK, of Vienna. Edited, with additions, by HENRY W. STELWAGON, M.D., Professor of Dermatology in the Jefferson Medical College, Philadelphia. With 63 colored plates, 39 half-tone illustrations, and 200 pages of text. Cloth, $3.50 net.

"The illustrations are very well executed, and the coloring remarkably accurate; they will serve as substitutes for clinical observation."—*Medical Record,* New York.

Atlas of Bacteriology and Text-Book of Special Bacteriologic Diagnosis. By PROF. DR. K. B. LEHMANN and DR. R. O. NEUMANN, of Würzburg. *From the Second Revised and Enlarged German Edition.* Edited, with additions, by G. H. WEAVER, M.D., Assistant Professor of Pathology and Bacteriology, Rush Medical College, Chicago. Two volumes. Part I.—632 colored figures on 69 plates. Part II.—511 pages of text, illustrated. Per volume: Cloth, $2.50 net.

"The illustrations . . . are works of art; they are true in color and relationship and are much superior to the usual photographic reproductions."—*Buffalo Medical Journal.*

SAUNDERS' MEDICAL HAND-ATLASES

Atlas and Epitome of Special Pathologic Histology.—By Dr. H. Durck, of Munich. Edited, with additions, by Ludvig Hektoen, M.D., Professor of Pathology, Rush Medical College, Chicago. In Two Parts. Part I.—Circulatory, Respiratory, and Gastro-intestinal Tracts. Part II.—Liver, Urinary and Sexual Organs, Nervous System, Skin, Muscles, and Bones. With 243 colored figures on 122 Plates, and 350 pages of text. Per part: $3.00 net.

"The work maintains the high standard of its predecessors. The plates are most beautifully reproduced and are accurate representations of the microscopic structure of the various organs concerned and the changes produced by disease."—*The Lancet*, London.

Atlas and Epitome of Diseases Caused by Accidents. By Dr. Ed. Golebiewski, of Berlin. Translated and edited, with additions, by Pearce Bailey, M.D., Consulting Neurologist to St. Luke's Hospital, New York. With 71 colored figures on 40 plates; 143 text-illustrations; 549 pages of text. Cloth, $4.00 net.

"This volume appeals not only to the medical student and the practitioner, but to the medico-legal specialist and accident insurance companies also."—*New York Medical Journal.*

Atlas and Epitome of Gynecology. By Dr. O. Schaffer, of Heidelberg. *From the Second Revised and Enlarged German Edition.* Edited, with additions, by Richard C. Norris, A.M., M.D., Assistant Professor of Obstetrics, University of Pennsylvania. With 207 colored illustrations on 90 plates, 65 text-illustrations, and 308 pages of text. $3.50 net.

"The book contains much valuable material. . . . Rarely have we seen such a valuable collection of gynecological plates."—*Bulletin of Johns Hopkins Hospital.*

Atlas and Epitome of Labor and Operative Obstetrics. By Dr. O. Schaffer, of Heidelberg. *From the Fifth Revised and Enlarged German Edition.* Edited by J. C. Edgar, M.D., Professor of Obstetrics and Clinical Midwifery, Cornell University Medical School. With 14 lithographic plates in colors, 139 other illustrations. $2.00 net.

"A careful study of the plates and drawings is the next best thing to actual clinical experience."—*Buffalo Medical Journal.*

Atlas and Epitome of Obstetrical Diagnosis and Treatment. By Dr. O. Schaffer, of Heidelberg. *From the Second Revised and Enlarged German Edition.* Edited, with additions, by J. C. Edgar, M.D., Professor of Obstetrics and Clinical Midwifery, Cornell University Medical School. With 122 colored figures on 56 plates, 38 other illustrations, and 315 pages of text. Cloth, $3.00 net.

"The illustrations are admirably executed . . . and the text expounds the scientific midwifery of to-day."—*New York Medical Journal.*

Atlas and Epitome of the Nervous System and its Diseases. By Prof. Dr. Chr. Jakob, of Erlangen. *From the Second Revised and Enlarged German Edition.* Edited, with additions, by E. D. Fisher, M.D., Professor of Diseases of the Nervous System, University and Bellevue Hospital Medical College, New York. 83 plates; 215 pages of text. $3.50 net.

"Represents with wonderful accuracy the macroscopic and microscopic anatomy of the nervous tissues as found in normal and pathologic conditions."—*American Medicine.*

Atlas and Epitome of Ophthalmoscopy and Ophthalmoscopic Diagnosis. By Dr. O. Haab, of Zurich. *From the Third Revised and Enlarged German Edition.* Edited, with additions, by G. E. de Schweinitz, M.D., Professor of Ophthalmology in the University of Pennsylvania. With 152 colored figures; 82 pages of text. Cloth, $3.00 net.

"Nowhere else can be found such a fine pictorial collection of changes and lesions of the eye-fundus as this volume contains."—*Journal of the American Medical Association.*

27.A.271.
Atlas and epitome of diseases o1905
Countway Library BET9309
3 2044 046 018 479

Atlas and Epitome of Otology. E
lin, with the collaboration of PROF. DR. A. P
with additions, by S. MACCUEN SMITH, M.
the Jefferson Medical College, Philadelphia.
lithographic plates, 99 text-cuts, and 292 pag

"The most complete of its kind as yet published."—CLARENCE J. BLAKE, M.D., *Professor of Otology, Harvard Medical School,* Boston.

Atlas and Epitome of Abdominal Hernias. By PRIVATDOCENT DR. GEORG SULTAN, of Göttingen. Edited, with additions, by WILLIAM B. COLEY, M.D., Clinical Lecturer on Surgery, Columbia University, N. Y. 119 illustrations, 36 in colors; 277 pages of text.
Cloth, $3.00 net.

"For the general practitioner and the surgeon it will be a very useful book for reference. The book's value is increased by the editorial notes of Dr. Coley."—*Boston Medical and Surgical Journal.*

Atlas and Epitome of Traumatic Fractures and Dislocations. By PROF. DR. H. HELFERICH, of Greifswald. Edited, with additions, by JOSEPH C. BLOODGOOD, M.D., Associate in Surgery, Johns Hopkins University, Baltimore. With 216 colored figures on 64 lithographic plates, 190 text-cuts, and 353 pages of text. Cloth, $3.00 net.

"The author has given the anatomy of fractures his special attention. . . . It is this feature of the work which gives it special value."—*University of Pennsylvania Medical Bulletin.*

Atlas and Epitome of Diseases of the Mouth, Pharynx, and Nose. By DR. L. GRÜNWALD, of Munich. *From the Second Revised and Enlarged German Edition.* Edited, with additions, by JAMES E. NEWCOMB, M.D., Clinical Instructor in Laryngology, Cornell University Medical School. With 102 colored figures on 42 lithographic plates, 41 text-cuts, and 219 pages of text. Cloth, $3.00 net.

"A distinct and valuable addition to the armamentarium of the worker in rhinologic fields.."—*American Medicine.*

Atlas and Epitome of Human Histology and Microscopic Anatomy. By PR. DR. J. SOBOTTA, of Würzburg. Edited, with additions, by G. CARL HUBER, M.D., Professor of Histology and Embryology, University of Michigan, Ann Arbor. With 214 colored figures on 80 plates, 68 text-cuts, and 248 pages of text. Cloth, $4.50 net.

"The 200 or more colored plates are, above all things, natural, and just as one would see them under the microscope."—*Indian Lancet,* India.

Atlas and Epitome of Operative Gynecology. By DR. O. SCHAFFER, of Heidelberg. Edited, with additions, by J. CLARENCE WEBSTER, M.D. (EDIN.), F.R.C.P.E., Professor of Obstetrics and Gynecology, Rush Medical College, in affiliation with the University of Chicago. With 43 colored figures on 42 lithographic plates, 21 text figures, many in colors, and 138 pages of text. $3.00 net.

Atlas and Epitome of General Pathologic Histology. By PR. DR. HERMANN DURCK, of Munich. Edited, with additions, by LUDVIG HEKTOEN, M.D., Professor of Pathology, Rush Medical College, Chicago. With 172 colored figures on 77 lithographic plates, 36 text-figures, many in colors, and 371 pages of text. *Just Issued.* Cloth, $5.00 net.

Atlas and Epitome of Operative Ophthalmology. By DR. O. HAAB, of Zurich. Edited, with additions, by GEO. E. DE SCHWEINITZ, M.D., Professor of Ophthalmology, University of Pennsylvania. With 30 colored plates, 154 text-cuts, and 377 pages of text. *Just Issued.* $3.50 net.

27.A.271.
Atlas and epitome of diseases o1905
Countway Library BET9309
3 2044 046 018 479